

Original article

Transanal resection using a single port trocar: a new approach to NOTES[☆]

Ramón Cantero Cid,^{*} Juan Carlos García Pérez, Tomás González Elosua, Francisca Lima Pinto, Javier Martínez Alegre, Raquel Martín, Jesús Torres Jiménez

Unidad de Coloproctología, Servicio de Cirugía General y Ap Digestivo, Hospital Infanta Sofía, San Sebastián de los Reyes, Madrid, Spain

ARTICLE INFORMATION

Article history:

Received March 23, 2010

Accepted September 27, 2010

Keywords:

Villous adenoma

Single port

Transanal resection

Rectal tumour

A B S T R A C T

Introduction: The morbidity and mortality, along with the functional changes that arise from radical surgery of rectal cancer, has led to an increasing interest in local treatment in the early stages of cancer of the rectum. Conventional transanal surgery has a high recurrence rate, for this reason transanal endoscopic microsurgery (TEM) is considered the treatment of choice in the last few years in large rectal adenomas and in early rectal cancer (low risk T1). **Patients and method:** We have intervened five patients, four with a diagnosis of villous adenoma of the rectum, and one in situ rectal carcinoma, using this new transanal approach, with a single port device.

Results: The locations of the lesions were in the mid-rectum, at a mean distance of 9 cm (range 6-10) from the anal margin. All of them were situated in the posterior side. The resection margins were negative in all cases. The mean size of the adenomas was 4 cm, three being sessile shaped, and one with a short, thick pedicle (>1 cm); the size of the carcinoma was 3 cm. The mean surgical time was 55 minutes. All the patients were discharged 48 hours after the surgical procedure.

Conclusion: We believe that the transanal endoscopic approach with a single port device is a simple, easily reproducible and cost-effective procedure when compared to TEM.

© 2010 AEC. Published by Elsevier España, S.L. All rights reserved.

Resección transanal a través de un trocar monopuerto. Una nueva aproximación al NOTES

R E S U M E N

Introducción: La morbilidad y la mortalidad, así como las alteraciones funcionales que conllevan la cirugía radical del cáncer de recto, han hecho que se produzca un incremento en el interés por el tratamiento local del cáncer de recto en estadios precoces. La cirugía transanal convencional ofrece una tasa de recurrencia elevada por lo que en los últimos años la TEM se considera el tratamiento de elección en los adenomas rectales de gran tamaño y en el cáncer de recto precoz (T1 de bajo riesgo).

Palabras clave:

Adenoma vellosa

Puerto único

Resección transanal

Tumor rectal

[☆]Video-Presentation during the XVIII Jornadas Internacionales. "Masterclass" en Coloproctología. (18th International Conference. Masterclass in Coloproctology). Laparoscopic Colorectal Surgery. Baiona, Spain, February 2010.

^{*}Corresponding author.

E-mail address: ramon.cantero@salud.madrid.org (R. Cantero Cid).

Pacientes y método: Hemos intervenido cinco pacientes, con diagnóstico de adenoma vellosa de recto (4) y carcinoma in situ de recto (1), mediante este nuevo abordaje transanal, utilizando un dispositivo monopuerto.

Resultados: La localización de las lesiones fue en recto medio, a una distancia media del margen anal de 9 cm (r: 6-10). Todas las lesiones estaban situadas en cara posterior. Los márgenes de resección en todos los casos fueron negativos. El tamaño medio de los adenomas fue de 4 cm, siendo tres de forma sésil y uno con pedículo corto y grueso (> 1 cm); el carcinoma tenía un tamaño de 3 cm. El tiempo medio quirúrgico fue de 55 minutos. Todos los pacientes fueron dados de alta a las 48 horas del procedimiento quirúrgico.

Conclusión: Pensamos que el abordaje transanal endoscópico a través de un dispositivo monopuerto es un procedimiento sencillo, fácilmente reproducible y coste-efectivo comparado con la TEM.

© 2010 AEC. Publicado por Elsevier España, S.L. Todos los derechos reservados.

Introduction

The removal of rectal neoplasms using endoanal ultrasound-guided surgery has not been a significant technique in the therapeutic arsenal for this pathology.

The risk of developing cancer in a colorectal polyp can now be determined after the breakthrough in the adenoma-carcinoma sequence,¹ where it was discovered that colorectal cancer is the result of a series of mutations which activate or block certain signals of the intracellular sequence. Therefore, a polyp larger than 1 cm has a 2.5% and 8% risk of being malignant at 5 and 10 years, respectively.²

A renewed interest has arisen in the transanal approach of rectal lesions. The progressive rise in colorectal cancer screening tests has resulted in a greater number of benign and malignant lesions being diagnosed during their early stages, the longer lives of patients and the widespread usage of endorectal ultrasound and radiotherapy.

The first line of treatment in the resection of rectal benign lesions is the endoscopic approach during the diagnosis procedure. However, if the size or location of the lesion restricts this or the lesion is malignant, different local transanal resection methods can be used (transanal resection, posterior [Kraske] or anterolateral [Mason], transanal endoscopic microsurgery [TEM], transanal endoscopic operation [TEO]).

The morbidity (20%-30%)³ and mortality (2%-3%) rate, as well as sexual, urinal and anorectal changes⁴ that arise from radical surgery of rectal cancer has led to an increasing interest in local treatment in the early stages of rectal cancer.

Conventional transanal surgery has a high recurrence rate,⁵⁻⁷ for this reason TEM (transanal endoscopic microsurgery) has been considered the treatment of choice in the last few years in large rectal adenomas and early rectal cancer (low risk T1).^{8,9}

TEM provides a better view of the whole of the rectum, enabling lesions up to the upper rectum region to be resected. In addition, it has shown to have lower recurrence rates than conventional transanal resection and its results are comparable to those of radical surgery, but with a lower complication rate and better functional results.^{10,11}

Furthermore, we have been able to see how surgery has evolved towards approaches performed through natural

orifices (NOTES) employing instruments that are normally used in TEM.¹²

In addition, different devices have appeared recently enabling laparoscopy to be performed through a single port. Several procedures carried out in this way have been reported in medical literature.¹³⁻¹⁵

We present here a new transanal endoscopic approach using a single port trocar and conventional laparoscopic material. This procedure may be considered as an alternative to TEM for the resection of rectal lesions.

Patients and method

Five patients diagnosed with villous adenoma of the rectum (4 patients) and in situ rectal carcinoma (one patient) underwent this new transanal approach using a Single Incision Laparoscopic Surgery (SILS) Covidien, Mansfield, MA (Figure 1).

All the patients were informed about the procedure and gave their consent for the operation to be performed under general anaesthesia.

The patients received antegrade preparation of the colon and a single dose of amoxicillin/clavulanic acid.

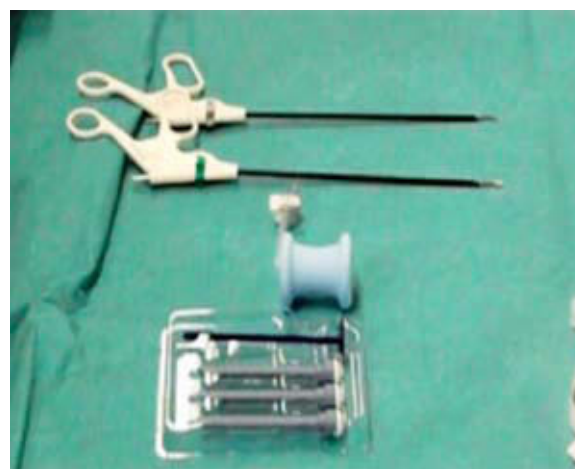


Figure 1 – Material used in the transanal endoscopic approach: SILS device, conventional paediatric laparoscopic material.

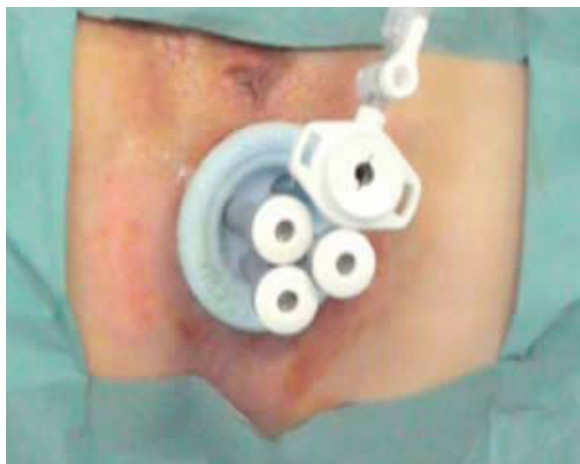

Figure 2 – SILS device inserted in the anal canal.

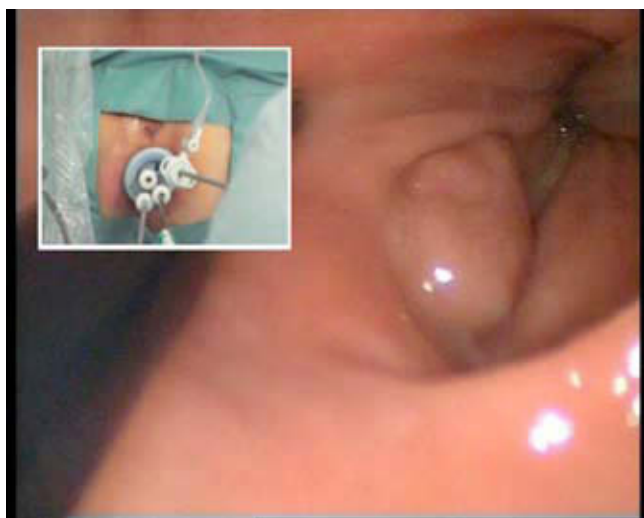

Figure 3 – Forceps and 30-degree scope inserted through the SILS device.

The classic lithotomy position was used on all patients as the lesions were located on the posterior wall.

The device was lubricated and introduced easily into the anus. Once this had been done, the trocars had to be inserted into the holes of the SILS port and the instillation of CO₂ was started until it reached a pressure of 14-16 mm H₂O (Figure 2).

The tools usually employed in laparoscopic surgery were inserted through the device (in our case, we used material used in paediatric surgery): grasping forceps, scissors and a blood-clotting device (Figure 3).

A 5 mm and/or 10 mm, 30-degree scope was always used.

Results

Five patients (31-72 years old) diagnosed with villous adenoma and in situ rectal carcinoma underwent transanal endoscopic surgery using a SILS device.

The lesions were located in the mid-rectum at a mean distance of 8 cm (range 6-10 cm) from the anal margin. All the lesions were located on the posterior wall.

The margins of resection were negative in all cases.

The mean size of the tumours was 3 cm, three being sessile shaped and one with a short, thick pedicle (>1 cm).

The resection of the full thickness of the wall was finished by stitching the approximated edges with absorbable stitches in four out of the five cases. The surgical site was thoroughly irrigated with betadine solution.

The mean surgery time was 55 minutes.

During the procedure we were able to see that the rectal walls collapsed at some points and it was necessary to separate them with the forceps. As happens in laparoscopic surgery, the effect of CO₂ facilitated the dissection of the lesion considerably.

All the patients were discharged 48h after the surgical procedure.

An anal manometry was performed on one patient before surgery and one week after the procedure, with no manometric changes being observed.

There were no perioperative complications and no abnormalities have been found in any of the patients after an average of 12 weeks of follow-up.

Discussion

Adenoma is the most common neoplasm of the large intestine and it is well known that most rectal cancers come from adenomas. Although endoscopic resection is possible in most cases, sometimes it cannot be performed due to the size, location and histological type of tumour. In these cases a surgical approach must be used.

The National Cancer Institute (NCI) believes that local resection should be performed in rectal cancers in stages 0 and 1 according to the American Joint Committee on Cancer (AJCC), as well as in patients that cannot or do not want to undergo radical surgery.

In this context, the TEM, technique described by Buess,¹⁶ has been increasingly accepted during the last few years. In Spain it is not very widespread due mainly to the high price of the equipment and the learning curve of the technique.

This is different to how easy it is to find a SILS device and conventional laparoscopic material that would make it possible for this procedure to become widespread, although the surgical strategy must be the same as the one used when the TEM/TEO device is available.

TEM requires the anal sphincter to dilate up to a diameter of 4 cm so that the rectoscopy can be inserted. This is avoided in the transanal approach with the SILS device which is made of a flexible and soft material. It is "hourglass" shaped and the 3 cm diameter neck remains perfectly in place held by the sphincter.

Casadesus¹⁷ has recently published a review of the TEM, where he compared this technique with other endoanal surgical techniques for adenoma resection. He reached the conclusion that the TEM had a lower percentage of residual tumours and postoperative complications; however, he found

a higher rate of long-term complication, especially problems linked to incontinence.

A comprehensive analysis was recently performed during a systematic review and economic evaluation of transanal endoscopic surgery by the *Agencia Lain Entralgo*.¹⁸ This showed a saving of 1187€ for adenomas (cost of 3072€) and 1769€ for malignant lesions (cost of 3283€) using TEM compared to other techniques. However, these savings do not take into account the initial investment and training of the surgeons, which amount to around 75 000€, meaning that 52 procedures must be performed before the initial investment can be recovered.

A device named TEO has recently appeared which has a considerably lower cost and uses the same scope as the laparoscopic approach.

Even so, if we compare these costs with those of the new transanal procedure, where we use the SILS device and conventional laparoscopic material, the balance falls clearly on the side of this new device.

It is important to point out that it is not advisable to remove rectal lesions in the upper third and/or which cover more than half the circumference of the rectum using the current SILS port device.

Another point in favour of the new technique has to do with how elastic the SILS device is. Unlike the TEM, it can be removed easily if it is necessary, for example, when removing the surgical piece.

The SILS device has three or four holes where trocars are inserted and one hole where CO₂ enters through a cannula. However, in some cases this orifice may be used to insert a conventional trocar through which CO₂ may be instilled and other types of instrument inserted (Figure 2).

The fact that no manometric abnormalities appear with regard to short-term faecal continence, compared to what seems to happen in TEM,¹⁹ might also be a factor in favour of using SILS. The above mentioned shape and make-up of the SILS mean that there are no changes in the resting pressure and maximum pressure values.

To conclude, we believe that the transanal endoscopic approach using a SILS device is a simple, easily reproducible and cost-effective procedure when compared to TEM.

Conflict of interest

The authors affirm that they have no conflict of interest.

REFERENCES

- Vogelstein B, Fearon ER, Hamilton SR, Kern SE, Preisinger AC, Leppert M, et al. Genetics alterations during colorectal tumor development. *N Engl J Med*. 1998;319:525-32.
- Gordon PH, Nivatvongs S. Principles and practice of surgery for the colon, rectum and anus. 2nd ed. New York: Marcel Dekker; 1999.
- Enker WE, Merchant N, Cohen AM, Lanouette NM, Swallow C, Guillem J, et al. Safety and efficacy of low anterior resection for rectal cancer, 681 consecutive cases from a speciality service. *Ann Surg*. 1999;230:544-54.
- Havenga K, Maas CP, De Ruiter MC, Welvaart K, Trimbos JB. Avoiding long-term disturbance to bladder and sexual function in pelvic surgery, particularly with rectal cancer. *Semin Surg Oncol*. 2000;18:235-43.
- Mellgren A, Sirivongs P, Rothemberger DA, Madoff RD, García-Aguilar J. Is local excision adequate therapy for early rectal cancer? *Dis Colon Rectum*. 1999;43:1064-74.
- Madbouly KM, Remzi FH, Erkek BA, Senagore AJ, Baeslach CM, Khandwala F, et al. Recurrence after transanal excision of T1 rectal cancer: should we be concerned? *Dis Colon Rectum*. 2005;48:711-9.
- Endreseth BH, Myrvold HE, Romundstad P, Hestvik UE, Bjerkeset T, Wibe A, The Norwegian Rectal Cancer Group. Transanal excision vs major surgery for T1 rectal cancer. *Dis Colon Rectum*. 2005;48:1380-8.
- Demartines N, Von Flue MC, Harder FH. Transanal endoscopic microsurgical excision of rectal tumors: indications and results. *World J Surg*. 2001;25:870-5.
- Borschitz T, Heintz A, Junginger T. The influence of histopathologic criteria on the long term prognosis of locally excised pT1 rectal carcinomas: results of local excision (transanal endoscopic microsurgery) and immediate reoperation. *Dis Colon Rectum*. 2006;49:1-15.
- Heintz A, Moerschel M, Junginger T. Comparison of results after transanal endoscopic microsurgery and radical resection for T1 carcinoma of the rectum. *Surg Endosc*. 1998;12:1145-8.
- Palma P, Horisberger K, Joos A, Rothenhoefer S, Willeke F, Post S. Local excision of early rectal cancer: Is transanal endoscopic microsurgery an alternative to radical surgery? *Rev Esp Enferm Dig*. 2009;101:172-8.
- Denk PM, Swanström LL, Whiteford MH. Transanal endoscopic microsurgical platform for natural orifice surgery. *Gastrointest Endosc*. 2009;70:193-4.
- Curcillo PG, King SA, Podolsky ER, Rottman SJ. Single Port Access (SPA) minimal access surgery through a single incision. *Surg Technol Int*. 2009;18:19-25.
- Leroy J, Cahill RA, Asakuma M, Dallemagne B, Marescaux J. Single- access laparoscopic sigmoidectomy as definitive surgical management of prior diverticulitis in a human patient. *Arch Surg*. 2009;144:173-9.
- Remzi FH, Kirat HT, Kaouk JH, Geisler DP. Single-port laparoscopy in colorectal surgery. *Colorectal Dis*. 2008;10:823-6.
- Buess G, Theiss R, Hutterer F, Pichlmaier H, Pelz C, Holfeld T, et al. Transanal endoscopic surgery of the rectum—testing a new method in animal experiments. *Leber Magen Darm*. 1983;13:73-7.
- Casadesus D. Transanal Endoscopic Microsurgery: A review. *Endoscopy*. 2006;38:418-23.
- Callejo D, Blasco JM, Fernández de Larrea N. Revisión sistemática y evaluación económica de la cirugía endoscópica endoanal. Madrid: Plan Nacional para el SNS del MSC. Unidad de Evaluación de Tecnologías Sanitarias: UETS No. 2006/07. ISBN: 978-84-451-3117-6.
- Serra X, Bombardo J, Mora L, Alcántara M, Ayguavives I, Navarro S. Microcirugía endoscópica transanal (TEM). Situación actual y expectativas de futuro. *Cir Esp*. 2006;80:123-32.