


CIRUGÍA ESPAÑOLA

www.elsevier.es/cirugia



Review article

NOTES. History and current situation of natural orifice transluminal endoscopic surgery in Spain

José F. Noguera Aguilar,^{a,*} Carlos Moreno Sanz,^b Ángel Cuadrado García,^a
 José M. Olea Martínez-Mediero,^a Rafael Morales Soriano,^a José C. Vicens Arbona,^a
 María L. Herrero Bogajo,^b and Luis Lozano Salvá^a

^aServicio de Cirugía, Hospital Son Llàtzer, Palma, Spain

^bServicio de Cirugía, Hospital La Mancha Centro, Alcázar de San Juan, Spain

ARTICLE INFORMATION

Article history:

Received December 3, 2009

Accepted March 16, 2010

Keywords:

NOTES

Minimally invasive surgery

Endoscopic surgery

National experience

A B S T R A C T

Natural orifice transluminal endoscopic surgery (NOTES), involves a group of new endoscopic approaches to the abdominal cavity, with potential advantages over conventional laparoscopic surgery. It is based on the possibility of performing intra-peritoneal surgical techniques through natural orifices by entering the peritoneal cavity through natural orifices perforating the organ that allows direct access to that cavity (stomach, vagina, rectum, bladder). The possibility of using this same route to access the retroperitoneum and mediastinum has subsequently been postulated.

Comments are made on how the technique has been developed, as well as how it has been applied in our country, attempting to give a general view on the risks and benefits of NOTES and the basic requirements to be able to start in this new surgery.

© 2009 AEC. Published by Elsevier España, S.L. All rights reserved.

NOTES. Historia y situación actual de la cirugía endoscópica por orificios naturales en nuestro país

R E S U M E N

La cirugía endoscópica transluminal a través de orificios naturales (NOTES, del inglés Natural Orifice Translumenal Endoscopic Surgery) engloba un conjunto de nuevas vías de abordaje endoscópico de la cavidad abdominal, con ventajas potenciales sobre la cirugía laparoscópica convencional. Se fundamenta en la posibilidad de realizar técnicas quirúrgicas intraperitoneales mediante la entrada en la cavidad peritoneal a través de los orificios naturales perforando el órgano que permite la entrada directa a dicha cavidad (estómago, vagina, recto, vejiga). Posteriormente se ha postulado la posibilidad de este mismo acceso para acceder al retroperitoneo y al mediastino.

Palabras clave:

NOTES

Cirugía mínimamente invasiva

Cirugía endoscópica

Experiencia nacional

*Corresponding author.

E-mail address: jnoguera@hsl.es (J.F. Noguera Aguilar).

A continuación se comenta cómo se ha desarrollado la técnica y cómo ha sido la aplicación en nuestro país, intentando dar una visión general sobre los riesgos y beneficios de la NOTES y las necesidades básicas para poder iniciarse en esta nueva cirugía.

© 2009 AEC. Publicado por Elsevier España, S.L. Todos los derechos reservados.

History of developing a new type of surgery

NOTES was first studied in animals. Kalloo performed three procedures in 2004¹ and communicated its satisfactory results performing transgenic peritoneoscopy and liver biopsy on a porcine model. Adequate access via the peritoneal cavity and a secure gastrotomy closure with endoscopic clips were achieved. Simultaneously, Rao and Reddy performed peritoneoscopy and hepatic and genital procedures with flexible endoscopes via the peroral route with laparoscopic support. In that same year, Reddy and Rao reported the first human appendectomy via the transgastric route.² This operation sparked widespread interest in the clinical application of NOTES.

The following year, several groups described different NOTES techniques in animal models, which continue attracting interest because of their feasibility and reproducibility. Kalloo's group reported satisfactory results performing tubal ligation and gastrojejunostomy transgastrically.^{3,4} Meanwhile, Thompson's group conducted the same sort of study with their experiences of transgastric abdominal exploration and gynaecological organ resection.⁵ It was also in 2005 when the groups of Swanstrom and Park successfully performed transgastric cholecystectomy and cholecystogastrostomy with flexible endoscopes.^{6,7}

Two years passed before interest in clinical application was awakened. During this time, experiments on animals showed how difficult it was to perform transgastric cholecystectomy safely, which was reflected by experimentation with access through the vagina. The clinical transvaginal approach for NOTES was not preceded by extensive animal experimentation, as the accessibility and safety of this route were supported by the extensive use made in the field of gynaecology with culdoscopy⁸⁻¹⁰ and with the use of the vaginal route for removing surgical specimens.^{11,12}

In early March 2007, the Zorron group performed the first series of transvaginal NOTES cholecystectomies on 4 patients, based on previous experimental studies.^{13,14} Later the same month, Bessler performed a successful hybrid transvaginal cholecystectomy with abdominal laparoscopic ports.¹⁵ In April 2007, Marescaux performed the purest NOTES cholecystectomy on a patient, using only one abdominal port to insert a Veress needle for pneumoperitoneum control and a grasper for vesicular traction.¹⁶ Branco's group reported their experience with hybrid cholecystectomy in a case with a single abdominal access trocar,¹⁷ and later a transvaginal nephrectomy with two 5 mm abdominal trocars.¹⁸ The first hybrid transvaginal NOTES cholecystectomy in Spain was performed by the Noguera group in October 2007,¹⁹ while the

first hybrid transgastric cholecystectomy was performed in November 2007 by the Lacy group.

Transcolonic and transvesical access have been advocated by some researchers as more suitable for the abdominal approach for supramesocolic structures, which are often more difficult to reach through a transgastric route. The Lima group²⁰ used the combined transgastric and transvesical approach to increase the feasibility of moderate complex procedures, such as nephrectomy and cholecystectomy in animal experiments. Feussner²¹ published his results on the transcolonic approach in animal experiments, creating a replicable model for potentially safer access to the peritoneal cavity through the sigma and upper rectum.

Parallel to this development, minilaparoscopy, i.e. laparoscopy with instrumentation of a smaller diameter, has developed in recent years, although it is still of sporadic clinical use. Optical instruments of 2.8 mm and 3 mm have been used, which allow the same manoeuvres with acceptable vision, reproducing conventional laparoscopy with minimal parietal access. Currently, the instrumentation is of interest for use as support in hybrid approaches to transluminal surgery. In the same vein, and with the intention of minimising access and transparietal support, techniques and instruments have been developed to perform traction and suspension manoeuvres of the target organ, such as magnets and tissue retractors attached to the parietal peritoneum. Scott's group²² managed to maintain the traction of the vesicular bottom with magnets in animals, thereby avoiding the need for a port in the abdominal wall. All these developments are being validated in animal and clinical pilot experiences, with the intention of being able to perform pure NOTES procedures with the necessary clinical safety as soon as possible.

While transluminal endoscopic surgery is developing, a new approach brought about by the improvement and reduction in laparoscopic instrumentation has appeared: single port or single incision surgery. It is based on using a single entry port in the abdomen, as the transumbilical approach is the most popular. Transumbilical surgery is gaining popularity and is being initially implemented in various procedures, particularly cholecystectomy and appendectomy, as reported by the Paraskeva group.²³ Many authors recommend the use of multiple trocars with a single entry through the navel, however, this creates more trauma to the abdominal wall than conventional laparoscopy. Therefore, the most appropriate future development may come from the use of endoscopic surgery with flexible instruments also through the navel. The use of the endoscope provides two working channels, a light and a camera inside the abdomen with

a single parietal entry. The transumbilical approach is not limited to females, as the transvaginal route is, and therefore has a promising future.

The use of natural orifices, particularly the transvaginal approach, has shown benefits in assisting the removal of surgical specimens, enabling laparoscopic approaches to be used without the need for support laparotomy, as this is achieved by the transvaginal approach. This approach is called MANOS (Minilaparoscopy-Assisted Natural Orifice Surgery) and is used to extract the specimen and to perform any other additional surgical manoeuvres. It was first reported by Tsin in 2001 under the name of culdolaparoscopy²⁴ but went unnoticed until the advent of NOTES surgery. Recently, this surgical approach has been applied for performing colorectal,²⁵ spleen,²⁶ and bariatric²⁷ surgery.

Many surgical groups are conducting clinical applications for single port transluminal endoscopic surgery, especially the transumbilical and transvaginal approaches. Isolated clinical cases are being reported in the literature for application in various diseases, while the results of clinical series are beginning to appear at scientific conferences, with the majority being promising and encouraging. Now is the time to carry out comparative studies with conventional laparoscopy to assess whether the promising benefits attributed to these new endoscopic surgery techniques are confirmed.

NOTES: benefits and risks

As with all surgical techniques, new surgical procedures and new approaches have both risks and benefits. NOTES surgery has real benefits, clear since it first appeared, and other potential ones, which may be achieved when pure procedures are performed without laparoscopic support.

Among the real benefits, which are clear despite being supported in hybrid procedures, is the reduction in trauma to the abdominal wall (Figure 1). Using a smaller number of parietal ports in the abdominal wall with a smaller diameter (3-5 mm), means less incisional pain and less possibility of parietal complications (bleeding, infection, evisceration and post-operative hernia). Performing less invasive procedures to the parietal peritoneum should also result in a reduced adhesiogenic capacity for this surgery. Some surgical approaches through natural orifices have the ability to allow extraction of surgical specimens without the

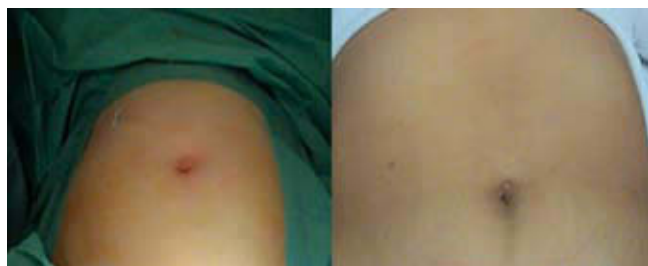

Figure 1 – Cosmetic benefit in the immediate postoperative period and one week after the operation in hybrid NOTES procedures.

problems caused by enlargement of the parietal ports: in vaginal access, the ability of the vaginal wall to expand, and the ease with which the incision closes makes this a natural benefit for extraction through the parietal port.

Some aspects that have shown real benefits have yet to be proven and must currently be considered as potential benefits (Table 1).

NOTES surgery also has some risks, for example, those arising from the application of flexible endoscopes when performing surgical procedures and those from new access routes to the abdominal cavity. The main risks associated with access to the peritoneal cavity via natural orifices are due to the possibility of contaminating the peritoneal cavity by introducing bacteria from the opening in the organ used (vagina, stomach, rectum), and problems in closing the organ wall, where parietal bleeding can occur as an immediate complication. Furthermore, another risk which is later problem is dehiscence of the parietal suture. Access to the cavity can be assisted by laparoscopic vision (Figure 2) or blindly with dissection planes passing through the wall. The latter access carries the possibility of damaging adjoining organs such as the rectum, vascular structures and ileal loops when using approaches from the pelvis, as well as the jejunal loops, transverse colon and epiploic vessels in the transgastric approach.

Table 1 – Potential benefits of endoscopic surgery via natural orifices

Potential benefits of NOTES surgery
Increased postoperative comfort
Less surgical pain
Reduced inflammatory response
Less formation of intraperitoneal adhesions
Fewer postoperative parietal complications
Shorter hospital stay and sick leave
NOTES indicates natural orifice transluminal endoscopic surgery.

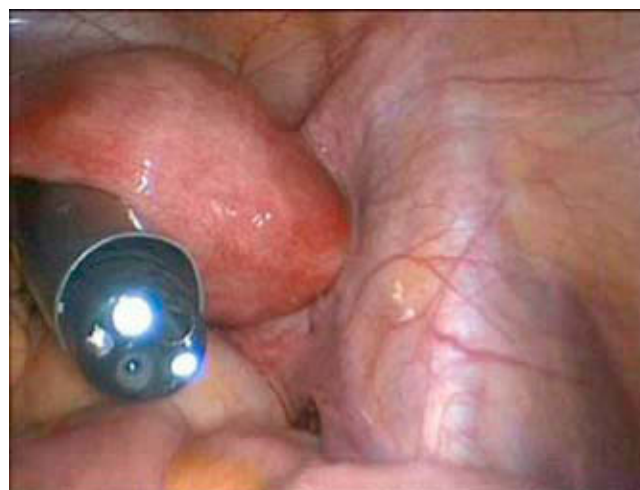


Figure 2 – Transvaginal approach with the flexible endoscope. Surgical trocar access ensures the input channel and prevents contamination of the endoscope.

Table 2 – Current risks with NOTES surgery

Risks of NOTES surgery
Intraperitoneal infection
Visceral parietal entry port haemorrhage
Visceral parietal entry suture dehiscence
Injury to adjacent viscera at entry
Viscera injury or structures in dissection
Difficulty in controlling complications
NOTES indicates natural orifice transluminal endoscopic surgery.

The flexible endoscopic vision is quite different from that usually obtained with the laparoscope. There is a 'fish-eye' deformity, which makes the central areas seem closer and leads to great instability due to the movement of the flexible optics carrier. Advantages of this new kind of vision include improved lens cleaning by an integrated-irrigation system, and the option of changing the viewing angle from 0° to almost 90° with the same device, without being limited to the single viewing angle of conventional laparoscopy. Despite the mobility of the flexible endoscope tip, the best way of working is opposite the operating site with the endoscope aligned: pelvic access to address the upper or supramesocolic compartment and gastric access to address the inframesocolic compartment and the pelvis.

The risks arising from the use of the flexible endoscope and its instrumentation depend on the use made of them. The main safety risk for the procedure is when performing dissection with the flexible endoscope, due to abrupt movements derived from the difficulty of precise and delicate manoeuvres. In cholecystectomy and appendectomy, dissection of the pedicle and mesentery is best performed with a medial to lateral approach to prevent unwanted movements of the coagulation electrodes towards the hepatic pedicle or the intestinal tract. Controlling possible haemorrhages would be problematic, due to the difficulty in making quick manoeuvres and the lack of adequate instruments for proper vascular sealing (Table 2).

Experimental development and practice in Spain

The experimental development of NOTES surgery has been made possible by the development of surgical models for cholecystectomy, nephrectomy and tubal ligation in pigs. Transgastric access is the most commonly used for the evolution of NOTES surgery and it has been quickly adopted into clinical practice. This is because the transvaginal approach can not be transferred exactly to the human model. Transgastric and transcolonic access in animal experiments are enabling the development of safe opening manoeuvres and closing mechanisms for the visceral opening: the 2 visceral opening and closing operations have not yet been transferred to clinical application due to lack of safety.

Test centres in Spain perform NOTES surgery on animals for 2 reasons: to investigate the development of NOTES and to

train teams so that these procedures can be implemented. The most active are CCMIJU–Centro de Cirugía de Mínima Invasión Jesús Uson (Jesus Uson Centre for Minimally Invasive Surgery) in Cáceres, CENDOS–Centro de formación en Cirugía Endoscópica (Endoscopic Surgery training centre) in Santander and WIDER - World Institute for Digestive Endoscopy Research in Barcelona. However, there are other smaller development centres for the technique, such as the Quirófano Experimental del Hospital Son Llàtzer (Experimental Surgery in Son Llàtzer Hospital) in Palma de Mallorca, Instituto Mediterráneo de Endoscopia (Mediterranean Institute of Endoscopy) in Castellón, Instituto de Investigación Biomédica (Institute of Biomedical Research) in La Coruña and Quirófano Experimental del Hospital Clínic (Experimental Surgery of the Hospital Clinic) in Barcelona. All of these are training teams currently conducting clinical NOTES applications and research on new applications via the transgastric and transvaginal approaches. Transvesical and transrectal approaches are not yet being investigated in Spain.

The Euro-NOTES organisation awarded various research grants in 2008 for development in this field. The Spanish group, GEPED–Grupo Español de Protocolos en Endoscopia Digestiva (Spanish Group of Digestive Endoscopy Protocols) received 2 of these grants for animal experiment projects. Their objectives were to assess different gastroenteroanastomosis techniques (Vázquez-Sequeiros) and various ways of closing the access hole wall into the peritoneal cavity (Pérez-Miranda). Both studies have been concluded and are now reporting promising results.

Clinical development in Spain

The first experiences in Spain with the clinical application of NOTES were in October 2007, which was when the first hybrid transvaginal cholecystectomy was performed in Spain by the J. Noguera group in Son Llàtzer Hospital, Palma de Mallorca.¹⁹ In November 2007, the first hybrid transgastric NOTES cholecystectomy was performed by the A. Lacy group in the Barcelona Hospital Clinic.

These 2 centres began cautiously, and established 2 separate lines: the development of safety and efficacy studies for transvaginal cholecystectomy in the Balearic centre, and the development of MANOS surgery (Minilaparoscopy Assisted Natural Orifice Surgery) in the Catalan centre. Transvaginal surgeries can be performed with MANOS, using rigid or flexible instruments with laparoscopic support, with colonic resections and bariatric surgery being performed via this route.²⁵

During 2008 and 2009, other techniques and other groups provided clinical contributions, with the first liver resection using transvaginal hybrid NOTES appearing in 2008 by the Balearic group²⁸ and the first nephrectomy by the A. Alcaraz group in the Barcelona Hospital Clinic.²⁹ Then in 2009, the first hybrid NOTES splenectomies were done by the E. Targarona group in Sant Pau Hospital, Barcelona.²⁶

Under the development of NOTES, single incision or single port surgery has appeared. This is also focusing on cholecystectomy so that this approach can be perfected, and

this emerging method has a predisposition to postoperative umbilical hernia among its disadvantages. Due to the concern for this potential adverse event, experimental and clinical studies have been launched to achieve an appropriate parietal wall, such as that by the C. Moreno group at Hospital La Mancha Centro in Ciudad Real (La Mancha Centre Hospital).³⁰

How to structure development: applying research to surgery practice

One of the initial problems a treatment team found when starting to use NOTES was how to programme the particular development in their team. Surgeons must be critical and yet be open to emerging techniques, paying special attention to what should be done and who needs to do it.³¹ There are some constraints based on prior laparoscopic experience in gastrointestinal surgery and in training a multidisciplinary team, which includes experienced laparoscopic surgeons and therapeutic endoscopists (Table 3). From the surgical point of view, the team must be trained in endoscopic surgery with 3 parietal ports and with minilaparoscopic access. From the viewpoint of flexible endoscopy, experience in endoscopic submucosal dissection seems to be a prior condition to determine tissue reaction to the manoeuvres performed with the endoscope. Combining both arms of the treatment team, there must be prior coordination of movements and the acquisition of minimal skills, so that injury to adjacent organs is avoided and basic surgical manoeuvres can be performed. This coordination is achieved in the simulator, with training boxes and by using animals.

The operating theatre should have two pieces of equipment: a tower for rigid endoscopy and one for flexible endoscopy. All instruments must be sterilised, and the flexible endoscope and accompanying instrumentation must be sterilised with ethylene oxide or hydrogen peroxide plasma.

Having achieved the above, the next step before starting a clinical application is to prepare a specific clinical programme with a comprehensive procedural protocol and well-defined objectives. Procedural safety must be prioritised over effectiveness, and there must be a possibility of finding a reproducible technique rather than having a singular surgical action which is difficult to reproduce. It must also include an early safety analysis and have the approval of the local research ethical committee (Table 3).

Having reached this stage, it seems a logical and desirable condition to perform the NOTES procedures in centres where the technique is being developed or where the first cases are being trained, before starting the clinical application. In the medium-term, the teaching and regulation of the implementation of these techniques seems necessary. The US and European agencies, NOSCAR and Euro-NOTES, intend to regulate the development and implementation of these new approaches, as well as structure the research to resolve the controversial aspects of this new type of surgery.

Recently, the EAES recommendations³² for the methodology of managing innovation in endoscopic surgery, and the IDEAL

Table 3 – Basic requirements for performing NOTES surgery

Requirements before starting NOTES surgery

Human resources, skilled staff

Laparoscopic surgeons with experience in the target organ
Experience of the team in the transvaginal approach and minilaparoscopy
Therapeutic endoscopists with experience in endoscopic dissection
Nurses trained in both fields

Material resources

Laparoscopy and flexible endoscopy equipment in the operating theatre
Sterilisation of equipment in ethylene oxide or plasma

Coordination requirements

Common training programme using animal experimentation
Correct orientation and navigation with the flexible endoscope
Coordination of surgical manoeuvres in small field of view

Preparation of a specific, comprehensive clinical programme evaluated by the ethics committee

Prioritisation of safety over efficacy
Prioritisation of reproducibility over feasibility

Early interim safety analysis

NOTES indicates natural orifice transluminal endoscopic surgery.

model³³⁻³⁵ (Idea, Development, Exploration, Assessment and Long-term study) for the development of innovation in surgery and its evaluation were published. Both studies state the necessary innovation stages for the method in question, as a new operation and management protocol for a given disease is not the same as a new instrumentation for a technique or a new surgical technique itself. The evolution of NOTES and its viability has so far been developed as a technique with evaluation using simulators and experiments on animals before moving on to initial application in patients. The next step is the small cohort prospective evaluation to be followed later by randomised trials.

Conflict of interest

The authors affirm they have no conflicts of interest.

REFERENCES

1. Kalloo AN, Singh VK, Jagannath SB, Niiyama H, Hill SL, Vaughn CA, et al. Flexible transgastric peritoneoscopy: a novel approach to diagnostic and therapeutic interventions in the peritoneal cavity. *Gastrointest Endosc*. 2004;60:114-7.
2. Rao GV, Reddy DN. Transgastric appendectomy in humans. Presented: 45th Annual Congress of the Society of Gastrointestinal Endoscopy of the India (2004), and World Congress of Gastroenterology; September 2006; Montreal, Canada.

3. Jagannath SB, Kantsevov SV, Vaughn CA, Chung SS, Cotton PB, Gostout CJ, et al. Peroral transgastric endoscopic ligation of fallopian tubes with long-term survival in a porcine model. *Gastrointest Endosc.* 2005;61:449-53.
4. Kantsevov SV, Jagannath SB, Niiyama H, Chung SS, Cotton PB, Gostout CJ, et al. Endoscopic gastrojejunostomy with survival in a porcine model. *Gastrointest Endosc.* 2005;62:287-92.
5. Wagh MS, Merrifield BF, Thompson CC. Endoscopic transgastric abdominal exploration and organ resection: initial experience in a porcine model. *Clin Gastroenterol Hepatol.* 2005;3:892-6.
6. Swanstrom LL, Kozarek R, Pasricha PJ, Gross S, Birkett D, Par PO, et al. Development of a new access device for transgastric surgery. *J Gastrointest Surg.* 2005;9:1129-36.
7. Park PO, Bergström M, Ikeda K, Fritscher-Ravens A, Swain P. Experimental studies of transgastric gallbladder surgery: cholecystectomy and cholecystogastric anastomosis (videos). *Gastrointest Endosc.* 2005;61:601-6.
8. Quinonez Guerrero R. Transvaginal celioscopy. 100 cases. *Ginecol Obstet Mex.* 1964;19:289-310.
9. Bajzak KI, Winer WK, Lyons TL. Transvaginal hydrolaparoscopy, a new technique for pelvic assessment. *J Am Assoc Gynecol Laparosc.* 2000;7:562-5.
10. Burnett AF. Reinventing the culdoscope. *Surg Endosc.* 2000;14:685-8.
11. Gill IS, Cherullo EE, Meraney AM, Borsuk F, Murphy DP, Falcone T. Vaginal extraction of the intact specimen following laparoscopic radical nephrectomy. *J Urol.* 2002;167:238-41.
12. Horng S, Huang K, Lo T, Soong Y. Bladder injury after LAVH: a prospective, randomized comparison of vaginal and laparoscopic approaches to colpotomy during LAVH. *J Am Assoc Gynecol Laparosc.* 2004;11:42-6.
13. Zorrón R, Filgueiras M, Maggioni LC, Pombo L, Lopes Carvalho G, Lacerda Oliveira A. NOTES. Transvaginal cholecystectomy: report of the first case. *Surg Innov.* 2007;14:279-83.
14. Zorrón R, Maggioni LC, Pombo L, Oliveira AL, Carvalho GL, Filgueiras M. NOTES transvaginal cholecystectomy: preliminary clinical application. *Surg Endosc.* 2008;22:542-7.
15. Bessler M, Stevens P, Milone L, Parikh M, Fowler D. Transvaginal laparoscopically assisted endoscopic cholecystectomy: a hybrid approach to natural orifice surgery. *Gastrointest Endosc.* 2007;66:1243-5.
16. Marescaux J, Dallemagne B, Perretta S, Wattiez A, Mutter D, Coumaros D. Surgery without scars: report of transluminal cholecystectomy in a human being. *Arch Surg.* 2007;142:823-6.
17. Branco Filho AJ, Noda RW, Kondo W, Kawahara N, Rangel M, Branco AW. Initial experience with hybrid transvaginal cholecystectomy. *Gastrointest Endosc.* 2007;66:1245-8.
18. Branco AW, Branco Filho AJ, Kondo W, Noda RW, Kawahara N, Camargo AA, et al. Hybrid transvaginal cholecystectomy. *Eur Urol.* 2008;53:1290-4.
19. Dolz C, Noguera JF, Martín A, Vilella A, Cuadrado A. Transvaginal cholecystectomy (NOTES) combined with minilaparoscopy. *Rev Esp Enferm Dig.* 2007;99:698-702.
20. Rolanda C, Lima E, Pêgo JM, Henriques-Coelho T, Silva D, Moreira I, et al. Third-generation cholecystectomy by natural orifices: transgastric and transvesical combined approach (with video). *Gastrointest Endosc.* 2007;65:111-7.
21. Meining A, Wilhelm D, Burian M, Dundoulakis M, Schneider A, Von Delius S, et al. Development, standardization and evaluation of NOTES cholecystectomy using a transsigmoid approach in the porcine model: an acute feasibility study. *Endoscopy.* 2007;39:860-4.
22. Scott D, Tang S, Fernandez R, Bergs R, Goova MT, Zeltser I, et al. Completely transvaginal NOTES cholecystectomy using magnetically anchored instruments. *Surg Endosc.* 2007;21:2308-16.
23. Chow A, Purkayastha S, Paraskeva P. Appendectomy and cholecystectomy using single-incision laparoscopic surgery (SILS): the first UK experience. *Surg Innov.* 2009;16:211-7.
24. Tsin DA. Culdolaparoscopy: a preliminary port. *JSLs.* 2001;5:69-71.
25. Lacy AM, Delgado S, Rojas OA, Almenara R, Blasi A, Llach J. MA-NOS radical sigmoidectomy: report of a transvaginal resection in the human. *Surg Endosc.* 2008;22:1717-23.
26. Targarona EM, Gomez C, Rovira R, Pernas JC, Balague C, Guarner-Argente C, et al. NOES-assisted transvaginal splenectomy: the next step in the minimally invasive approach to the spleen. *Surg Innov.* 2009;16:218-22.
27. Ramos AC, Zundel N, Neto MG, Maalouf M. Human hybrid NOTES transvaginal sleeve gastrectomy: initial experience. *Surg Obes Relat Dis.* 2008;4:660-3.
28. Noguera JF, Dolz C, Cuadrado A, Olea JM, Vilella A. Transvaginal liver resection (NOTES) combined with minilaparoscopy. *Rev Esp Enferm Dig.* 2008;100:411-5.
29. Alcaraz A, Peri L, Molina A, Goicoechea I, García E, Izquierdo L, et al. Feasibility of transvaginal NOTES-assisted laparoscopic nephrectomy. *Eur Urol.* 2009. In press.
30. Moreno-Sanz C, Picazo-Yeste JS, Manzanera-Díaz M, Herrero-Bogajo ML, Cortina-Oliva J, Tadeo-Ruiz G. Prevention of trocar site hernias: description of the safe port plug technique and preliminary results. *Surg Innov.* 2008;15:100-4.
31. Targarona EM. Cirugía endoscópica transgástrica: delirio tecnológico o avance potencial. *Cir Esp.* 2006;80:1-2.
32. Neugebauer EA, Becker M, Buess GF, Cuschieri A, Dauben HP, Fingerhut A, et al. EAES recommendations on methodology of innovation management in endoscopic surgery. *Surg Endosc.* 2010. In press.
33. Barkun JS, Aronson JK, Feldman LS, Maddern GJ, Strasberg SM, Altman DG, et al. Evaluation and stages of surgical innovations. *Lancet.* 2009;374:1089-96.
34. Ergina PL, Cook JA, Blazeby JM, Boutron I, Clavien PA, Reeves BC, et al. Challenges in evaluating surgical innovation. *Lancet.* 2009;374:1097-104.
35. McCulloch P, Altman DG, Campbell WB, Flum DR, Glasziou P, Marshall JC, et al. No surgical innovation without evaluation: the IDEAL recommendations. *Lancet.* 2009;374:1105-12.