

## CIRUGÍA ESPAÑOLA

www.elsevier.es/cirugia

## Original article

**Hemorpex system: A new procedure for the treatment of haemorrhoids****Carlo Iachino,<sup>a</sup> Yaima Guerrero,<sup>b,\*</sup> Francesco Sias,<sup>c</sup> Luca Milone,<sup>d</sup> Martino Saccone,<sup>a</sup> Giuseppe Franco Giordano,<sup>a</sup> and Máximo Giordano<sup>a</sup>**<sup>a</sup>Department of Surgery, School of Medicine, University of Genoa, Italy<sup>b</sup>Servicio de Cirugía General, Hospital Municipal de Badalona, Badalona, Barcelona, Spain<sup>c</sup>Department of Surgery, Clínica Villa Santa Rita, Cagliari, Italy<sup>d</sup>Department of Surgery, Columbia University College of Physicians & Surgeons, New York, USA

## ARTICLE INFO

## Article history:

Received January 9, 2009

Accepted March 29, 2009

Online June 21, 2009

## Keywords:

Haemorrhoids

Muco-haemorrhoidopexy

Hemor Pex System®

## A B S T R A C T

**Introduction:** We present a new technique for the surgical treatment of haemorrhoids, consisting of the repositioning of haemorrhoid cluster, using a rotating proctoscope called Hemor Pex System® (HPS). This procedure is performed as an outpatient procedure, with minimal postoperative pain and rapid integration into working life.

**Objectives:** To present the experience with this technique during 3 years of follow-up in 2 institutions in Genoa, Italy.

**Patients and methods:** From January 2003 to June 2006, 1112 patients with grade II, III, and IV haemorrhoids were operated on using the HPS technique, in 2 different hospitals. Prospectively analyzed the following parameters: postoperative pain, incidence of complications, and recurrence of symptoms.

**Results:** A total of 1112 patients were operated, of whom 719 have completed the follow-up. The mean age was 47 years. In 92% of cases the intervention was performed under local anaesthesia. The average time of surgery time was 20 (5) min. A total of 97% of patients were discharged at 6 h after surgery. The immediate postoperative pain, according to the Visual Analogue Scale (VAS): absent (0) in 38 cases, slight (1-3) in 431 cases, 218 medium, and intense in 32 cases.

**Conclusions:** We believe HPS is a safe procedure, with a short learning curve for surgeons, and in particular leads to a great reduction in post-operative pain for the patient.

© 2009 AEC. Published by Elsevier España, S.L. All rights reserved.

\*Corresponding author.

E-mail address: yguerrero@bsa.cat (Y. Guerrero).

0009-739X/\$ - see front matter © 2009 AEC. Published by Elsevier España, S.L. All rights reserved.

## Resultados de la hemorroidopexia con sistema hemorpex en el tratamiento quirúrgico ambulatorio de las hemorroides

### R E S U M E N

#### Palabras clave:

Hemorroides

Pexia mucohemorroidal

Hemor Pex System®

**Introducción:** Se presenta una nueva técnica para la intervención de hemorroides, consistente en el reposicionamiento de los paquetes hemorroidales, para lo que se emplea un proctoscopio rotatorio denominado Hemor Pex System® (HPS). Se realiza de forma ambulatoria, con mínimo dolor postoperatorio y rápida incorporación a la vida laboral.

**Objetivos:** Presentar la experiencia obtenida con esta técnica durante 3 años de seguimiento en 2 instituciones en Génova, Italia.

**Pacientes y método:** Desde enero de 2003 hasta junio de 2006 se intervinieron 1.112 pacientes diagnosticados de hemorroides (grados II, III y IV) con la técnica de HPS. Se realizó un estudio prospectivo no aleatorizado en 2 hospitales, en el que se tuvo en cuenta el dolor postoperatorio, la incidencia de complicaciones y la recurrencia de síntomas.

**Resultados:** Se intervino a 1.112 pacientes, de los cuales 719 han concluido el seguimiento. La edad media fue de 47 años. En el 92% de los casos la intervención se realizó bajo anestesia local. El tiempo medio quirúrgico fue de  $20 \pm 5$  min. Al 97% de los pacientes se lo dio de alta a las 6 h de la intervención. El dolor postoperatorio inmediato, según la escala analógica visual, estuvo ausente (0) en 38 casos, fue ligero (1 a 3) en 431 casos, medio en 218 casos e intenso en 32 casos.

**Conclusiones:** Los autores consideran que es un procedimiento seguro, con una corta curva de aprendizaje para los cirujanos y, sobre todo, aporta una gran reducción en el dolor postoperatorio para el paciente.

© 2009 AEC. Publicado por Elsevier España, S.L. Todos los derechos reservados.

## Introduction

Haemorrhoids are a frequent ailment that affect more than 50% of the population that is older than 50.

The usual therapeutic alternatives oscillate from mildly intensive interventions,<sup>1,2</sup> which can even be carried out in the clinic, to more involved interventions,<sup>3-7</sup> that require local-regional anaesthesia, an operating room and, normally, hospitalisation as well as a slower post-operative period with its corresponding economic expenses.<sup>8</sup>

The development of new techniques<sup>9-11</sup> for haemorrhoid surgery that aim to offer a more comfortable post-operative period, show that there is yet to exist an "ideal" surgery for this ailment: with a low rate of complications and minimal post-operative pain.

This study is designed to test the effectiveness of the de-arterialising haemorrhoidopexy; the results regarding post-operative pain, the incidence of complications and the recurrence of symptoms will be evaluated. This technique is performed as an outpatient surgery.

The operating technique consists of a muco-haemorrhoidopexy using a device call the Hemor Pex System® (HPS). By using a disposable rotating proctoscope (Angiológica, Italy) and a light source that is introduced into it, the haemorrhoidal clusters are better visualised and loose sutures are placed in each of the 6 terminal branches of the superior haemorrhoidal artery. This way, the anorectal mucous is elevated and the haemorrhoidal columns return to their position above the Z line.

The results obtained over more than 3 years of performing the HPS technique in 2 different institutions are described in this article.

## Materials and method

A prospective, non-randomised study was carried out on patients that had undergone an intervention using the HPS technique in the Hospital San Martino in Genoa, and in the Villa Santa Rita de Cagliari Clinic, Italy, from January of 2003 to June of 2006. Hundred thousand twelve patients were included in the study that were affected by grade II (with persistent bleeding), III and IV haemorrhoids, according to Goligher,<sup>12</sup> of which 719 concluded the follow-up period.

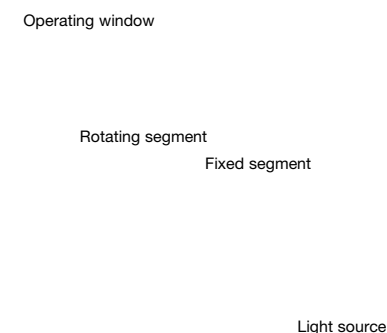
The following parameters were prospectively analysed: post-operative pain, incidences of complications and recurrence of symptoms.

A colonoscopy or a barium enema was performed on all of the patients, as well as an anaesthetic evaluation and a pre-operative examination before being admitted as outpatients.

The follow-up controls were carried out 7, 30, and 60 days, and 6 and 12 months after the surgical intervention was performed.

All of the patients were instructed on how to carry out the control of their post-operative pain at their homes according to the visual analogue scale (VAS).

Post-operative pain was recorded after the operation, and at each of the follow-up visits the VAS was used, where 0 meant no pain and 10 meant the highest level of pain felt.



**Figure 1 – Disposable proctoscope. Fixed segment and rotating segment.**

### **Surgical technique**

To perform the surgery, a HPS® (Angiológica, Italy) device was used. It is a disposable device (proctoscope), made a fixed segment that maintains contact with the skin of the anus and the sensitive mucous of the anal canal, and by another rotating segment. A light source is attached to the proctoscope to allow for better visualisation. Also, the device presents a window through which sutures can be performed (Figure 1).

Two hours before the intervention, an anaesthetic cream was applied to the anus of the patients (Emla).

The technique was carried out with local anaesthesia and sedation in the majority of the cases. The patients was placed on the operating table in the prone decubitus position ("Jack Knife") position or in a left lateral decubitus position (Sims position), the gynaecological position was used in very few cases and only with general anaesthesia.

During surgery and during the first 5 days of the post-operative period, metronidazole (1.5 g) was administered to the patients.

The rotating proctoscope is introduced in the anus with the handle facing the perineum so that the positions of the operating windows coincide with the hours 1, 3, 5, 7, 9, and 11, that coincide with the 6 branches of the superior haemorrhoidal artery (Figure 2). Sutures are placed in a "Z" formation through the window of the device, one for each hour position (Vycril 3/0, 22 needle). With this procedure, the corresponding artery is bound, as well as the placation of the mucous and sub-mucous, which makes it possible to repair the haemorrhoidal prolapsed component.

### **Results**

A haemorrhoidopexy was performed on 1112 patients using the HPS® technique, of which 719 concluded the follow-up

**Figure 2 – Surgical technique.**

period; the 393 that did not conclude the follow-up period were excluded from the study. Of the 719 patients, 456 were men and 263 were women. The average age was 47 years old (range, 20-87).

Depending on the haemorrhoidal grade, 180 patients were included with grade II haemorrhoids (with associated rectal bleeding), 467 patients with grade III haemorrhoids, and 72 patients with grade IV haemorrhoids.

The interventions were carried out in 92% of the cases with sphincter local anaesthesia (carbocain, 2%: 15 cc), in 7% of the cases, local anaesthesia was not administered (only sedation). General anaesthesia was only administered in 4 cases and spinal anaesthesia in 5 cases, both because of patient requests.

Sedation was administered to all patients with midazolam in variable intravenous doses (from 5 to 10 mg).

Surgical time was 20 (5) min.

Ninety-seven percent of the patients were discharged 6 h after the intervention, while 1.9% had to stay at the hospital for 1 night, but no more than 24 h.

The first spontaneous intestinal evacuation was produced after 24 h in 82% of the patients; the rest of the patients that had still not evacuated on the third post-operative day and that presented great discomfort were encouraged to take a mild laxative (with a natural fibre base).

The patients returned to work in an average of 3 days after the surgery (range, 1-7).

There were no cases of persistent intra-operative bleeding, 97 patients (13.5%) reported mild bleeding when defecating during the first 7 to 12 days after surgery.

Thirty-two patients (4.5%) suffered an acute retention of urine in the immediate post-operative period, while 139 patients (19.3%) suffered discrete anal and peri-anal swelling.

Pain control in the immediate post-operative period showed a predominance of a 1 to 3 on the VAS (431 patients) (Figure 3).

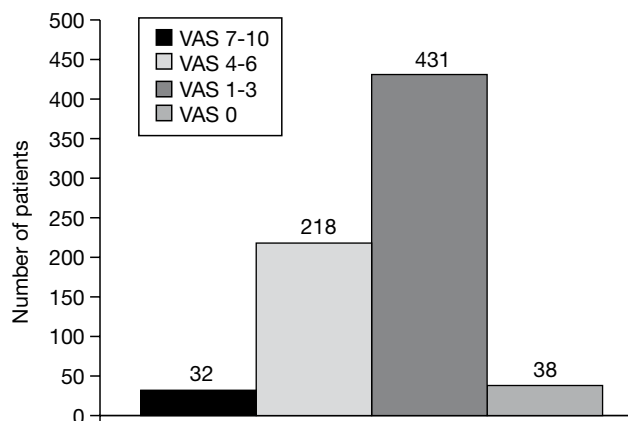


Figure 3 – Pain in the immediate post-operative period.

Table 1 – Complications in the first 30 days of the post-operative period

| Complications            | Patients, % |
|--------------------------|-------------|
| Tenesmus                 | 114 (15.9)  |
| Peri-anal abscess        | 6 (0.8)     |
| Para-rectal fistula      | 3 (0.4)     |
| Discomfort in anal canal | 218 (30.3)  |
| Peri-anal ecchymosis     | 26 (9.5)    |

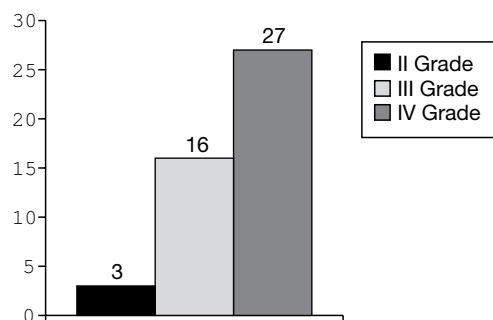


Figure 4 – Relapses according to the haemorrhoidal grade.

Table 1 shows the complications observed in the first 30 days after surgery.

In the third follow-up visit, after 60 days, 6 patients (0.8%) presented peri-anal fistulas, 2 patients (0.3%) presented pseudopolyps, 3 patients (0.4%) presented haemospermia, 2 patients (0.2%) presented faecal incontinence, and 13 patients (1.8%) presented incontinence of gasses that returned to normal spontaneously.

Regarding the relapses, 3 cases were observed in the group of patients with grade II haemorrhoids (1.6%); in the grade III group there were 16 patients (3.4%) that relapsed and in the grade IV group, there were 27 patients (37.5%) that relapsed (Figure 4).

Regarding the costs of the technique, a relevant fact and something to keep in mind is that before the new technique

Table 2 – Relative cost of the Hemor Pex System®

| Technique                        | Relative cost |
|----------------------------------|---------------|
| Cryoablation                     | 3             |
| Milligan-Morgan                  | 4             |
| Longo                            | 10            |
| HPS                              | 6             |
| HPS indicates Hemor Pex System®. |               |

was being used, the Statistical Institute of the University of Genoa carried out a study on the relative cost of said technique, comparing it with other existing techniques. The data is shown in Table 2.

## Discussion

The results of this study show that the HPS® technique is a safe alternative to conventional surgical procedures for the outpatient treatment of haemorrhoids with various grades of prolapsed, although those of grade IV present an elevated number of relapses.

The percentage of peri-operative bleeding (0%) is inferior to that published in existing medical literature that is found between 0.5% and 4% of risk for post-operative bleeding. This could be related to the extreme ease with which this system allows to suture the blood vessels with good visualisation.

In the 14 cases where the patients had to stay one night at the hospital, this was not due to reasons related to the surgical intervention, but rather immediate complications (intense pain, acute urine retention, patient's home more than 150 km from the hospital).

The habitual use of metronidazol was found to reduce post-operative pain; diuretics and cortisone were also used for patients that presented swelling and bruising to reduce pain and tenesmus to a minimum.

Of the 218 patients that complained about endo-rectal pain, said pain was due to the presence of non-absorbable sutures (polypropylene). In fact, when said suture was removed (by endoscope), the pain disappeared. This problem has not returned since we started to use absorbable sutures (Vicryl®).

In the 2 cases where "pseudopolyps" were observed, a polypectomy was carried out during an endoscopic control as they were considered as polyps. However, the histological study showed that they were actually mucous exuberances secondary to the sutures of the mucopexy.

Three patients presented haematospermia after the operation. It is probable that this was due to a technical error, and it is important to not go too deep when passing the suture in the anterior wall of the rectum to avoid perforating the rectum with possible serious complications (for example: recto-vaginal fistula) similar to those reported with other techniques.<sup>15</sup>

Six patients presented peri-anal or peri-rectal abscesses followed by the formation of fistulas. This happened primarily in diabetic patients, in those that were taking anticoagulant

treatment and in obese patients. The presence of these co-morbidities shows the scarring process and increases the probability of local bacterial overgrowth.

The recurrences seemed to be superior than what they really were. In fact, when examining the rectum, many patients (22%) had skin-tags and no recurrence of the disease. The true relapses were of 6.4% and this is not more than that described in existing medical literature.<sup>16-18</sup>

No logical explanation was found for the cases of faecal incontinence (2 patients) and that of gasses (13 patients), which were spontaneously resolved in around 2 to 3 months after the intervention. It is probable, however, that some deficit existed before the surgical intervention.

To conclude and according to the opinion of the authors, the HPS® technique has numerous advantages: it is a safe procedure, even if the follow-up period is relatively short, it is easy to learn the technique (it has a short learning curve for surgeons) and, above all, it provides a great reduction in post-operative pain for the patient. Although the procedure is simple, it is not complication-free, primarily during the learning curve. The persistence of skin-tags and relapses, more evident in patients with grade IV haemorrhoids are two of the disadvantages of the technique. On the other hand, the process is fast and can be carried out with local anaesthesia or eventually, even with mild sedation that allows for a fast recuperation of the patient and the immediate return to the work force.

## REFERENCES

1. Dennison AR, Paraskevopoulos A, Kerrigan DD, Shorthouse AJ. New thoughts on the aetiology of haemorrhoids and the development of non operative methods for their management. *Int Surg Sci.* 1995;2:31-5.
2. Ho Y-H, Tan M, Seow-Choen F. Micronized purified flavonoid fraction compared favorably with rubber band ligation and fiber alone in the management of bleeding hemorrhoids: Randomized controlled trial. *Dis Colon Rectum.* 2000;43:66-9.
3. MacRae HM, McLeod RS. Comparison of hemorrhoidal treatment modalities: A meta-analysis. *Dis Colon Rectum.* 1995;38:687-94.
4. Oh C. Problems of cryohemorrhoidectomy. *Cryobiology.* 1982;19:283-6.
5. Longo A. Treatment of hemorrhoidal disease by reduction of mucosa and hemorrhoidal prolapse with circular stapling device: A new procedure. 6th World Congress of Endoscopic Surgery. Bologna: Monduzzi Editore; 1998. p. 777-84.
6. Milligan ETC, Morgan CN, Jones LE, Officer R. Surgical anatomy of the anal canal and operative treatment of haemorrhoids. *Lancet.* 1937;2:1119-24.
7. Fergusson EF. Alternatives in the treatment of hemorrhoidal disease. *South Med J.* 1988;81:606-10.
8. Gaj F, Trecca A, Buzzi N, Restifo A, Tonelli F. Il censimento di centri nazionali di colonproctologia: il profilo e le principali problematiche della colonproctologia nel nostro paese. [tal] *Coloproct.* 2000;19:3.
9. Longo A. Treatment of hemorrhoids disease by reduction of mucosa and hemorrhoidal prolapse with a circular suturing device: A new procedure. Proceedings of the 6th World Congress of Endoscopic Surgery. Roma: Mondozi Editore; 1998. p. 777-84.
10. Morinaga K, Hasuda K, Ikeda T. A novel therapy for internal hemorrhoids: Ligation of the hemorrhoidal artery with a newly devised instrument (moricorn) in conjunction with a Doppler flowmeter. *Am J Gastroenterol.* 1995;90:610-3.
11. Meintjes D. Doppler guided hemorrhoidal artery ligation (HAL) for the treatment of hemorrhoids. Results in 1415 patients. Patients studies 2000 [cited, Oct 10, 2008]. Available from: URL: [www.pharma.it/eng/pati.htm](http://www.pharma.it/eng/pati.htm).
12. Goligher C, editor. Surgery of the anus, rectum and colon. London: Bailliere Tindal; 1980.
13. Milson JW. Hemorrhoidal disease. In: Wexner SD, Beck DE, editors. *Fundamentals of Anorectal Surgery.* New York: McGraw Hill; 1992. p. 192-214.
14. Milito G, Cortese F, Brancalone C, Casciani CD. The role of prophylactic metronidazole in the management of post-operative pain after haemorrhoidectomy. *Tech Coloproctol.* 1996;4:84-6.
15. Sutherland LM, Burchard AK, Matsuda K, Sweeney JL, Bokey EL, Childs PA, et al. A systematic review of stapled hemorrhoidectomy. *Arch Surg* 2002;137:1395-406.
16. Palazzo FF, Francis DL, Clifton MA. Randomized clinical trial of Ligasure versus open haemorrhoidectomy. *Br J S.* 2002;89:154-7.
17. Milito G, Gargiani M, Cortese F. Randomized trial comparing Ligasure haemorrhoidectomy with the diathermy dissection operation. *Tech Coloproctol.* 2002;6:171-5.
18. Franklin EJ, Seetharan S, Lowney J, Horgan PG. Randomized, clinical trial of Ligasure vs. conventional diathermy in hemorrhoidectomy. *Dis Colon Rectum.* 2003;46:1380-3.