

CLINICAL CASE

## Laparoscopic cholecystectomy in a patient with ventriculoperitoneal shunt system

Wilver Ernesto Herrera García<sup>a,\*</sup>, Jesús Pérez Vertí Ramírez<sup>a</sup>, Ismael Lares-Asseff<sup>b</sup>

<sup>a</sup>*Servicio de Cirugía General, Hospital General de Ensenada, Ensenada, Baja California, Mexico*

<sup>b</sup>*Instituto Politécnico Nacional, Centro Interdisciplinario de Investigación para el Desarrollo Integral Regional Unidad Durango (CIIDIR-IPN Unidad Durango), Durango, Mexico*

Received 4 March 2014; accepted 17 September 2014

### Abstract

**Background:** Pediatric patients with hydrocephalus and ventriculoperitoneal (VP) shunt systems are not exempt from suffering from gastrointestinal diseases. Today, with technological advances it would be controversial to not offer the benefits of minimally invasive surgery. To date, no studies have been carried out comparing different techniques to assess the best way to prevent intracranial hypertension. However, there are increasing reports of safe surgery in children with VP shunt operated by laparoscopy.

**Case report:** We present the case of a 14-year-old male who presented for laparoscopic cholecystectomy with a VP shunt system. The patient had clinical data of cholecystitis; therefore, it was decided to perform laparoscopic cholecystectomy. The patient experienced a satisfactory evolution with hospital discharge at 72 h postoperatively.

**Conclusions:** Currently, it is common that children with hydrocephalus and VP systems may require some type of laparoscopic surgery. This surgery is safe for various procedures including gallbladder and ovarian pathology. Satisfactory results will help the surgeon make a better surgical decision in this type of pediatric patient.

© 2014 Hospital Infantil de México Federico Gómez. Published by Masson Doyma México S.A. All rights reserved.

\*Corresponding author.

E-mail: [wwwilver@hotmail.com](mailto:wwwilver@hotmail.com) (W.E. Herrera García).

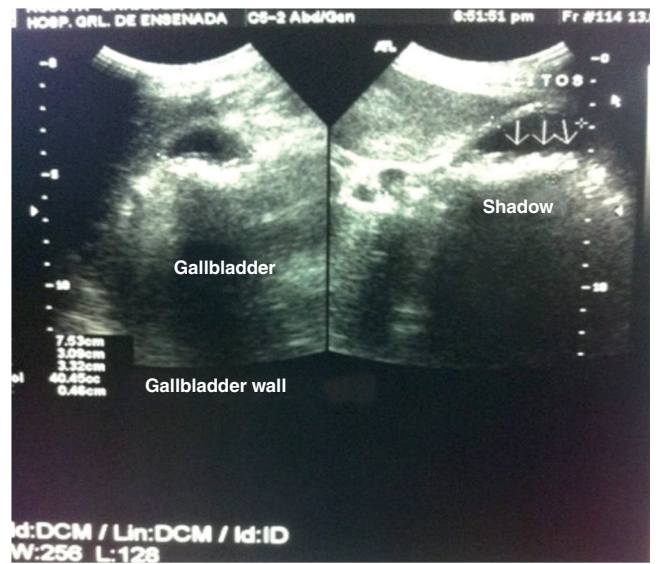


Figure 1 Gallbladder ultrasound where gallstones are visualized.



