

Hepatic fascioliasis

Raul Pichardo-Bahena MD,¹ Paloma Almeda-Valdés MD,² Nahum Méndez-Sánchez MD, PhD³

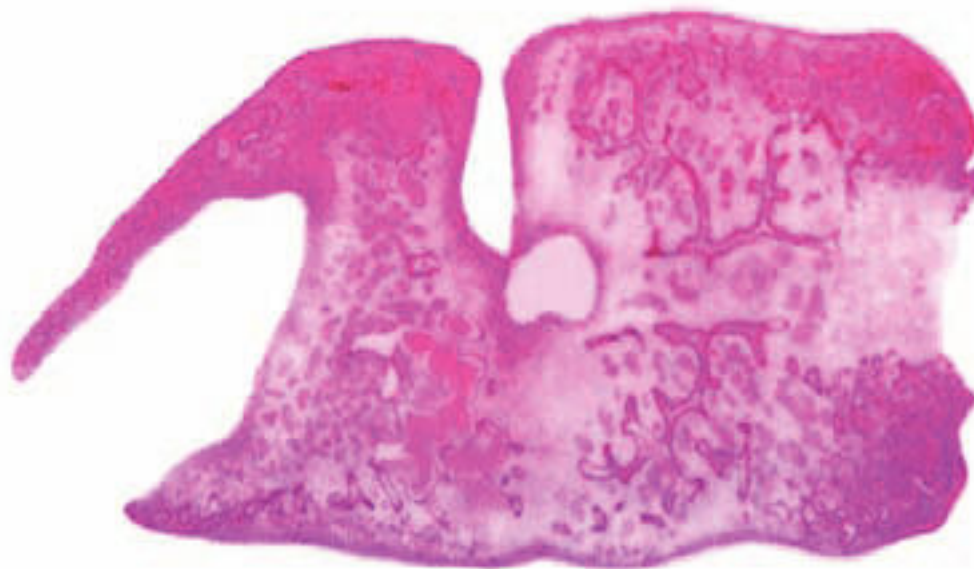


Figure 1.

A 76-year old female originally from Malinalco, Estado de Mexico (a central Mexican State) was admitted to the hospital. The patient had a laparoscopic colecistectomy in 1975. In 1985 an endoscopic colangiography was performed because of right upper abdominal pain, the report was of stenosis of choledocian. Open surgery was performed in 2000 and a biliary stent was placed. She was admitted on May 14, 2003 with again right upper abdominal pain. Laboratory test were performed: Normal hematologic and blood chemical tests, aspartate aminotransferase 35 U/L, alanine aminotransferase 63 U/L, bilirubin 1.4 mg/dL, alkaline phosphatase 150 U/L, glutamil transpeptidase 203 U/L.

An endoscopic colangiography was performed with findings of Vater papilla cicatricial stenosis and significant biliar duct dilation, and the founding is shown.

Medica Sur Clinic & Foundation

¹ Department of Pathology.

² Department of Medicine.

³ Gastroenterology and Liver Unit.

Address for correspondence:

Raúl Pichardo-Bahena, MD

Department of Pathology, Medica Sur Clinic & Foundation.

Puente de Piedra 150, Col. Toriello Guerra, Mexico City, Mexico