

Use of a stiff guidewire in transjugular liver biopsy in patients with a pronounced angle of the suprahepatic veins

Andrés de Hoyos;¹ Ma. Lilia Loredó;² Marco A. Martínez;³ Manuel R. Gil;³

Abstract

In the performance of a transvascular liver biopsy, the Trucut-type transjugular liver biopsy set is advance over a multipurpose catheter place in the suprahepatic vein. Occasionally there is a sharp bend between the suprahepatic veins and the inferior vein cava and the multipurpose catheter does not provide sufficient support to track the biopsy access set. To deal with this problem we describe the use of a stiff guidewire for an easy introduction of the biopsy set.

Key words: Stiff guidewire, transjugular liver biopsy, trucut-type needle.

Introduction

Transjugular hepatic biopsy has become a useful and relatively easy to perform technique. The use of the Trucut-type transjugular needle has contributed in making the majority of these procedures successful.¹ This technique allows diagnosis in more than 90% of the cases, even when hepatic cirrhosis or extensive fibrosis are present.^{1,2} Furthermore, complications are minor, with a minimum mortality.³ However, technical problems may occasionally limit the success of the procedure. A pronounced angle of the suprahepatic vein may be an obstacle for the adequate introduction of the biopsy set to the intrahepatic region. In our experience, this occurs in approximately 5% of the cases (unpublished data). In these cases, the use of a metallic

guide which provides greater support may be of use. We describe here this technical difficulty and the use of a stiff guidewire to solve the problem (*Figure 1*).

Material and methods

Technical difficulty: Routinely, we use a multipurpose catheter to descend the hepatic biopsy set (a 7-F sheath and a stiffing cannula).¹ However, the multipurpose catheter does not offer enough support to track the biopsy access set, which has a rigid metal sheath, making it difficult to descend the set to the intrahepatic region when the angle formed between the suprahepatic vein and the inferior cava is pronounced. Thus, the multipurpose catheter bends and cannot offer the support needed to introduce the set.

Technical modification: For these cases, we used a 0.035inx260cm Amplatz Super Stiff guidewire with a J distal tip (Medi-Tech, Boston Scientific Corporation), and introduced it through the multipurpose catheter. The combination provided better support allowing the easy descent of the access set to the intrahepatic region, and the biopsy (*Figure 2*). Asking the patients to

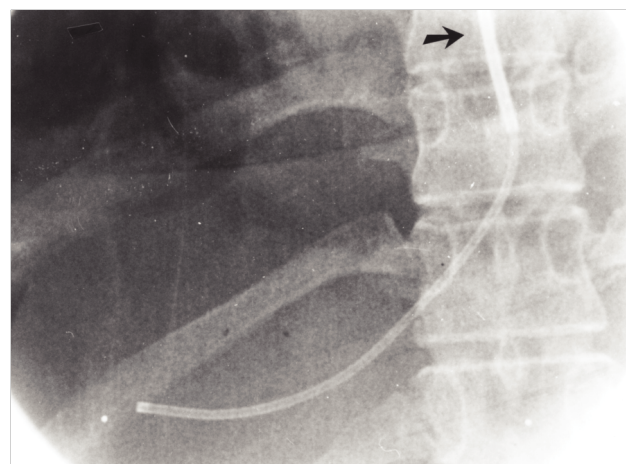


Figure 1. Transjugular liver biopsy of a 32 year old patient with inactive rheumatic cardiopathy and cardiogenic hepatopathy. The multipurpose catheter does not provide sufficient support to track the biopsy access set (arrow).

¹ From the Department of Gastroenterology.

² Pathology.

³ Hemodynamics.

Instituto Nacional de Cardiología “Ignacio Chávez”, Mexico, City.

Address for correspondence:

Dr. Andrés De Hoyos, Departamento de Gastroenterología, Instituto Nacional de Cardiología “Ignacio Chávez”. Juan Badiano No. 1. Sección XVI. Tlalpan. México, D.F. 14080 FAX (5) 5573 0994 E-mail: andehoyos@yahoo.net.mx

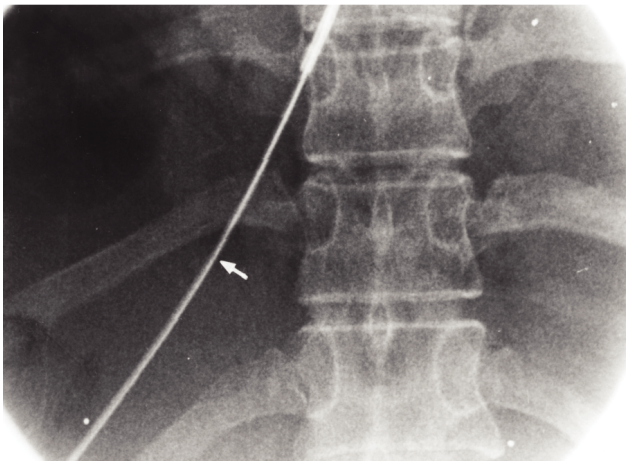


Figure 2A.

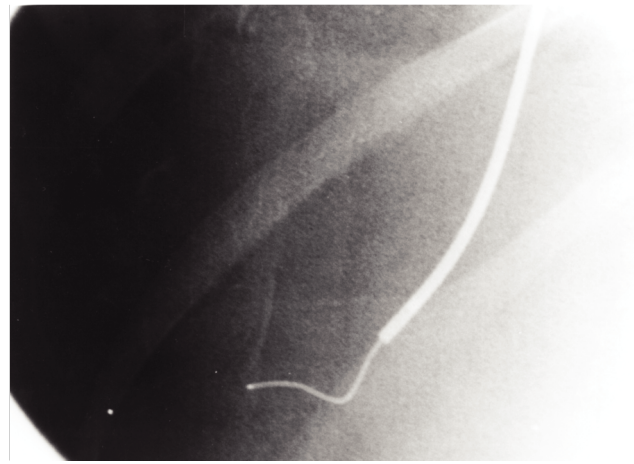


Figure 2B.

Figure 2. The use of a guidewire facilitate to the descend of the access set. (A) The guide (arrow) is introduced through the multipurpose catheter, (B) allowing to descend the hepatic biopsy access set to the right hepatic vein.

inhale deeply at the moment of descending the set facilitates its introduction to the intrahepatic veins.

Discussion

When this technical difficulty occurs, the metallic guidewire offers better support than the multipurpose catheter to descend the liver biopsy access set. Therefore, we recommend that this type of guidewire or any other rigid guide should be available during the performance of this procedure to avoid this type of problems, and to perform the procedure efficiently and rapidly. In the future a more flexible hepatic biopsy set should

be developed to overcome this problem, which could be easily introduced in the suprahepatic veins.

References

1. De Hoyos A, Loredó ML, Martínez-Ríos MA, Gil MR, Kuri J, Cárdenas M. Transjugular Liver Biopsy in 52 Patients with an automated Trucut-Type Needle. *Dig Dis Sci* 1999; 44-1: 177-180.
2. Kardabhe M, Soyer P, Boudiaf M, Cochand-Priollet B, Pelage JP, Rymer R. Transjugular liver biopsy with an Automated Device. *Interventional Radiology* 1997; 204: 369-372.
3. McAfee JH, Keeffe EB, Lee Rösch J. Transjugular liver biopsy. *Hepatology* 1992; 15: 726-32.