

Biliary stricture caused by portal biliopathy: Case report and literature review

Ignacio Guerrero Hernández;¹ Mariana Weimersheimer Sandoval;² Eric López Méndez;¹
Jorge Hernández Calleros;¹ Alberto Rubio Tapia;¹ Misael Uribe¹

Abstract

Portal biliopathy is a rare condition that is usually not diagnosed and only in few cases causes symptoms. Those symptoms are caused by vascular obstruction of the biliary tree in patients with portal hypertension. We report a case of a 29 years man who presented with history of intermittent jaundice, persistent elevation of hepatic function test and hematemesis as a manifestation of portal hypertension without liver damage. We present the clinical, radiological and pathological characteristics and literature review of the cases that had been reported, their diagnoses, treatment and clinical implication.

Key words: Portal hypertension, portal biliopathy, bile-duct strictures.

Introduction

Benign bile-duct strictures usually are caused by stones, bile-duct injury, sclerosing cholangitis, chronic pancreatitis and congenital abnormalities. Portal hypertension-related bile-duct changes represent another group of uncommon causes of benign stricture, which can result in biliary obstruction, choledocolithiasis, and cholangitis.¹

The earliest evidence of portal cholangiopathy was noted by Hunt in 1965.² Meredith et al. and others report-

ed a few cases of common bile duct obstruction caused by extensive collateral venous circulation of portal vein.^{3,5}

Portal biliopathy is a rare condition that is usually not diagnosed. It is associated with presence of varices around bile duct with concomitant ischemic damage and structural alteration of the bile duct wall.⁴

Case report

A 29-year-old man with history of steroids abuse, who had history of intermittent jaundice, persistent hepatic function test elevation for 3 years, and history of esophageal varices bleeding and cholangitis four months ago, was evaluated at our institute. At initial evaluation the patient was afebrile, the physical examination revealed jaundice and hepatosplenomegaly, but was otherwise unremarkable. There was no ascitis or peripheral stigmata of liver disease. Laboratory test results were the following: Haemoglobin, 15.8 g/dL; platelets, 55,000; alkaline phosphatase, 1,036 U/L; aspartate aminotransferase, 273 U/L; alanine aminotransferase, 290 U/L; total bilirubin 7 mg/dL; albumin, 3.7 g/dL; Serum electrolytes were within normal ranges.

Transabdominal US revealed splenomegaly (24 cm), hepatomegaly (16 cm) and no biliary dilation. Upper endoscopy showed large esophageal varices. We performed a transjugular hepatic biopsy and suprahepatic pressure measurement and found both within normal limits (*Figure 1*). Endoscopic retrograde cholangiopancreatography disclosed a biliary stenosis, and absence of stones (*Figure 2*). A biliary stent was placed. Computed tomography also demonstrated spontaneous splenorenal shunt (*Figure 3*). Angiography was performed, and discard portal vein cavernomatous transformation.

He underwent Sugiura's surgery without complications.

Discussion

Portal biliopathy is a rare disorder characterized by biliary ductal and gallbladder wall abnormalities seen in patients with portal hypertension for any cause. This changes have been reported to be more common in patients with extrahepatic portal vein obstruction (EHPVO) than in pa-

¹ Departamento de Gastroenterología.

² Departamento de Patología.

Instituto Nacional de Ciencias Médicas y Nutrición
"Salvador Zubirán". México Distrito Federal.

Address for correspondence:
Dr. Ignacio Guerrero Hernández.
Departamento de Gastroenterología.
Instituto Nacional de Ciencias Médicas y Nutrición
"Salvador Zubirán".
México Distrito Federal.
Tel. 54-87-09-00 Ext. 2706.
E-mail: guerrerogallo@yahoo.com

Manuscript received: 16 August, 2005 and accepted: 18 October, 2005.

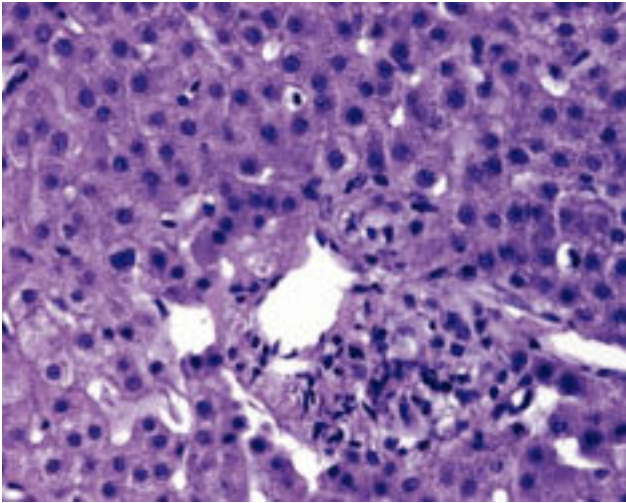


Figure 1. Trasyugular hepatic biopsy showing normal hepatic tissue and a portal space without alterations.

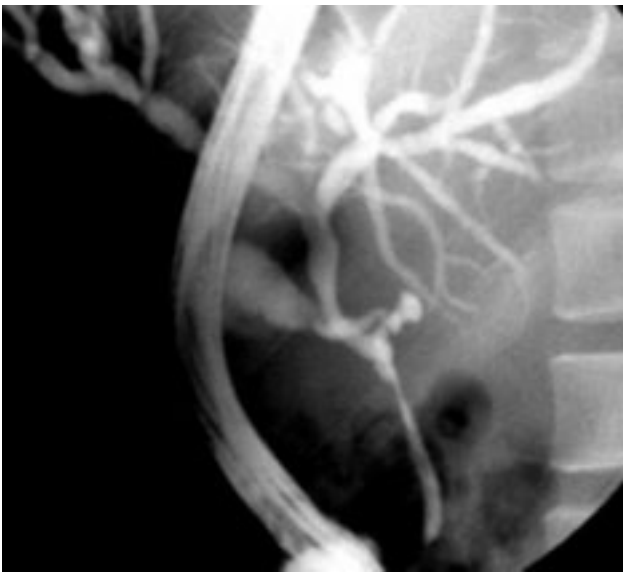


Figure 2. Endoscopic retrograde cholangiopancreatography showing a choledocal stenosis, and absence of stones.

tients with non-cirrhotic portal fibrosis or cirrhosis of the liver.⁶ Biliary ductal abnormalities caused by portal venous collaterals occurs in 80% to 100% of patients with EHPVO and less commonly in patients with cirrhosis or non-cirrhotic portal fibrosis, but symptomatic portal biliopathy is seen in less than 10%.¹

The venous drainage of the common bile duct (CBD) is mostly by veins that ascend along its course. They form epicholedochal venous plexus and paracholedochal venous plexus. The former forms a fine reticular venous plexus on the common bile duct and hepatic ducts, and is in intimate contact with their outer surface. The paracho-

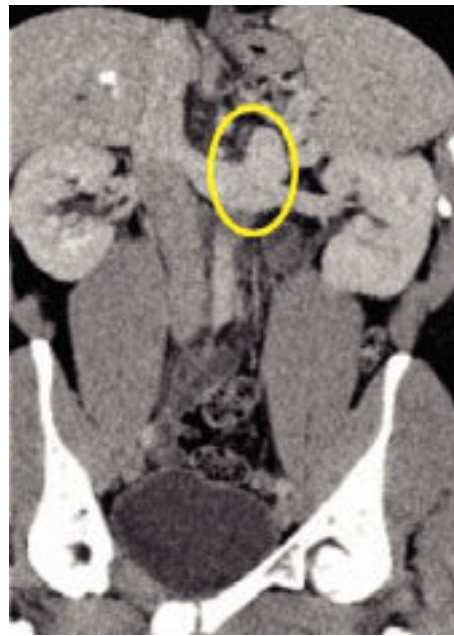

Figure 3. Computed tomography showing spontaneous splenorenal shunt.

ledochal veins course parallel to the CBD and are connected to the gastric veins, the pancreaticoduodenal vein, the portal vein and to the liver directly. For that reason the high portal venus pressure can be transmitted to this venous system and produce a irregular mural changes in the CBD.⁷ Other mechanism by which portal hypertension cause bile duct obstruction is by bile duct compression by enlarging collaterals.⁸

Portal biliopathy produces symptoms that are caused by partial or rarely, complete bile duct obstruction. Abdominal pain, recurrent fever and jaundice, alone or in combination, suggest the possibility of biliary obstruction, but the majority of the patients are asymptomatic and demonstrate characteristic changes on endoscopic retrograde cholangiopancreatography (ERCP), and elevation in alkaline phosphatase only.⁹ Ductal anomalies are likely to contribute to large extent to jaundice because extrahepatic portal vein obstruction patients generally have near normal liver function.⁸

The gold standard for diagnosis is the ERCP. Doppler ultrasound studies are complementary to ERCP findings and show gallbladder varices in 34% of patients with EHPVO, 24% of patients with non-cirrhotic portal fibrosis and 13% of patients with cirrhosis. Magnetic resonance cholangiography needs to be evaluated in patients with suspected portal biliopathy and could be compared with the results of ERCP studies.⁸

At present, strategies for the management of portal biliopathy are selective and directed to symptomatic patients only. Asymptomatic patients do not need any treatment, especially if the liver function tests are normal.

Sometimes, obstructive jaundice can be caused by a dominant stricture or significant abnormalities of the bile

duct without any evidence of CBD stones. In such patients, the placement of a biliary stent with balloon dilatation is recommended. The stents often need to be changed, and two or more stents need to be placed to keep the lumen patent.⁸ In the presence of symptomatic biliary obstruction not amenable to endoscopic therapy, a porto-systemic shunt is indicated.¹¹ This may relieve the symptoms of biliary obstruction through portal decompression. If the obstruction and symptoms persist, hepaticjejunostomy is indicated.

References

1. Jason L, Umphress R, Pecha E, Urayama S. Biliary stricture caused by portal biliopathy: diagnosis by EUS with Doppler US. *Gastrointestinal Endoscopy* 2004; 60: 1021-1024.
2. Hunt AH. Compression of the common bile duct by an enlarging collateral vein in case of portal hypertension. *Br J Surg* 1965; 52: 636-7.
3. Meredith HC, Vujic I, Schabel SL, D'Brien PH. Obstructive jaundice caused by cavernous transformation of portal vein. *Br J Radiol* 1978; 51: 1011-12.
4. Mercado-Diaz MA, Hinojosa Ca, Chan C, et al. Portal biliopathy. *Rev Gastroenterol Mex* 2004; 69(37): 41.
5. Spira R, Widrich WC, Keusch KD, et al. Bile duct varices. *Arch Surg* 1985; 120: 1194-6.
6. Sarin SK, Bhatia V, Makwane U. Portal biliopathy in extrahepatic portal vein obstruction. *Ind J Gastroenterol* 1992; 2: A82.
7. Shapiro AL, Robillard GL. The arterial blood supply of the common and hepatic bile ducts with reference to problems of common duct injury and repair: Based on a series of 23 dissections. *Surgery* 1948; 23: 1-4.
8. Ramesh Ch, Dharmesh K, Ajith T, et al. Portal biliopathy. *Journal of Gastroenterol Hepatol* 2001; 16: 1086.
9. Khuroo MS, Yattoo GN, Zargar S, et al. Biliary abnormalities associated with extrahepatic portal vein obstruction. *Hepatology* 1993; 17: 807-13.
10. Chawla A, Dewan R, Sarin SK. The frequency and influence of gall bladder varices on gall bladder functions in patients with portal hypertension. *Am J Gastroenterol* 1995; 90: 2011-14.
11. Mork H, Weber P, Schmidt H, Georing RM, et al. Cavemomatous transformation of the portal vein associated with common bile duct structures. *Gastrointest Endosc* 1998; 47: 79-83.