

The rolling stone

Ariela Rauchwerger;¹ Rivka Zissin;² Fred M. Konikoff¹

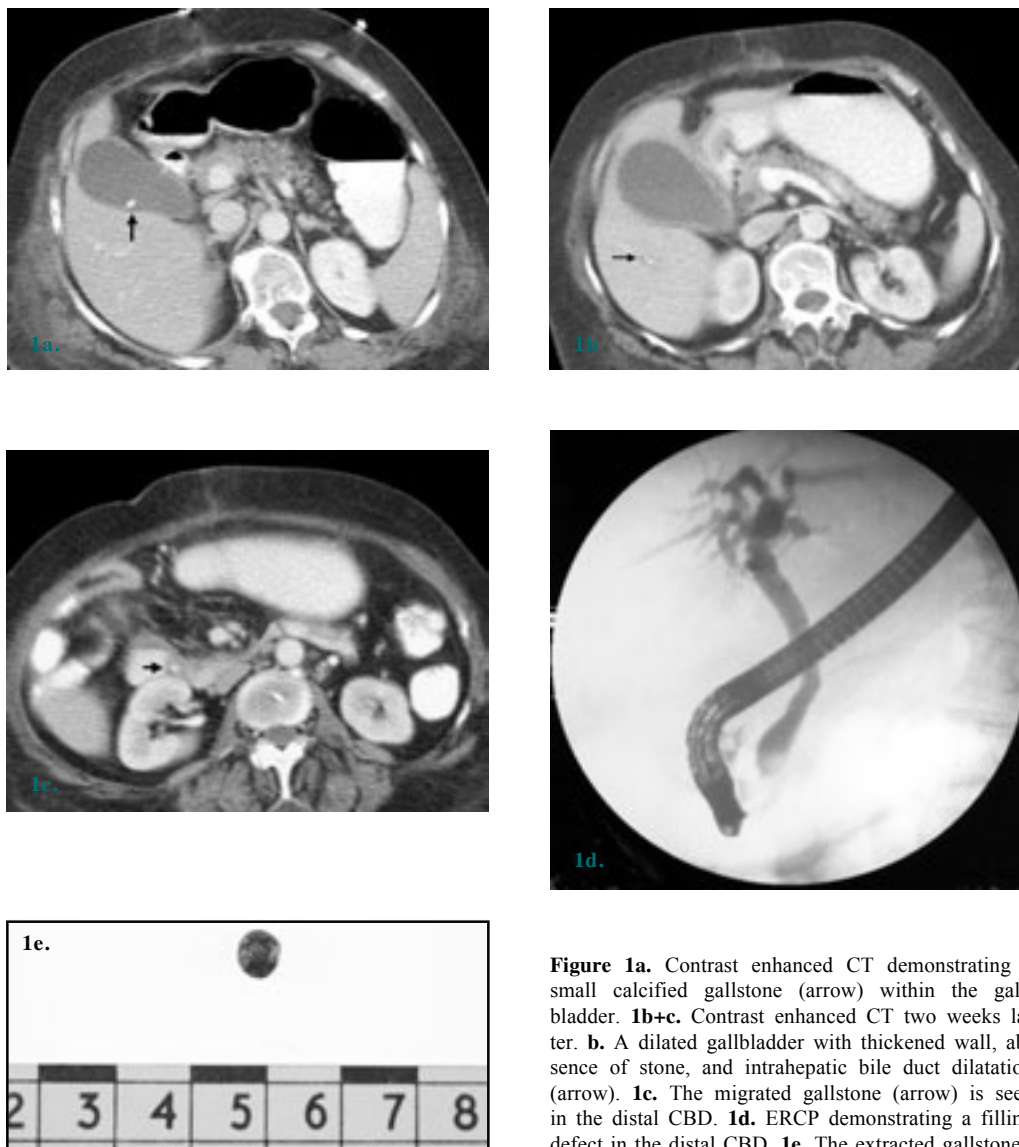


Figure 1a. Contrast enhanced CT demonstrating a small calcified gallstone (arrow) within the gallbladder. **1b+c.** Contrast enhanced CT two weeks later. **b.** A dilated gallbladder with thickened wall, absence of stone, and intrahepatic bile duct dilatation (arrow). **1c.** The migrated gallstone (arrow) is seen in the distal CBD. **1d.** ERCP demonstrating a filling defect in the distal CBD. **1e.** The extracted gallstone.

¹ Departments of Gastroenterology and Hepatology.

² Department of Radiology.

Meir Medical Center, Kfar Saba, and Sackler School of Medicine, Tel Aviv University, Israel.

Address for correspondence:

Dr. Ariela Rauchwerger. Department of Gastroenterology and Hepatology

Meir Medical Center, 59 Tshernichovsky Street, Kfar Saba 44281, Israel Tel: +972-9-7472580 Fax: +972-9-7472725

E-mail: ariela.rauchwerger@clalit.org.il

Manuscript received and accepted: 19 September, 2005.

A 58-year-old woman was admitted to the hospital due to vomiting and abdominal pain with a clinical picture consistent with incarcerated post-operative ventral hernia, several years after undergoing a hysterectomy.

A contrast-enhanced CT demonstrated an incarcerated right colon within a post-operative ventral hernia. A single stone in the gallbladder was also seen (*Figure 1a*).

The patient underwent an emergent laparotomy with resection of the ischemic right colon and primary anastomosis.

Two weeks post-operatively, the patient developed fever, abdominal pain and jaundice consistent with cholangitis. Laboratory examinations revealed hyperbilirubinemia and elevated liver enzymes with a predominantly cholestatic pattern (total bilirubin-3.7 mg/dL, direct bilirubin-2.7 mg/dL, alkaline phosphatase-516 U/L, γ glutamyltransferase-731 U/L, alanine aminotransferase-107 and aspartate aminotransferase-152).

A repeat abdominal CT demonstrated a dilated, thickened walled gallbladder, dilatation of intra and extrahepatic bile ducts and the previously demonstrated gallbladder stone was now located within the distal choledochus (*Figures 1b+c*).

Antibiotics were started and the patient underwent an emergent ERCP demonstrating the migrated stone within the distal choledochus (*Figure 1d*). A sphincterotomy was performed and a single black pigment stone (*Figure 1e*) was successfully extracted.

After the procedure the abdominal symptoms and fever resolved and the liver enzymes normalized.

Although gallstones are very common in industrialized countries, stones in the bile ducts are less prevalent. It is estimated that about 8% to 18% of symptomatic gallstones patients will have concomitant bile duct stones at the time of cholecystectomy.¹ Moreover, while the natural history and symptomatology of gallbladder stones are relatively well established, the same is not true for bile duct stones. In Western societies, most bile duct stones are believed to be secondary stones that have migrated into the bile ducts from the gallbladder. Since some of the bile duct stones have a diameter that clearly exceeds that of the cystic duct, it seems that stones can remain in the bile ducts and grow there in size during significant periods of time.

Our patient is unique in terms of a clear documentation of the stone passage and evolution from an asymptomatic gallbladder stone to a symptomatic choledochal stone. This maybe more prevalent in patients having small stones such as our patient, as has been shown to be true in patients with biliary pancreatitis.²

References

1. Cynthia W. Ko, Sum P. Lee, et al. Epidemiology and natural history of common bile duct stones and prediction of disease. *GI endoscopy* 2002; 56(6): 165-9.
2. Diehl AK, Holleman Jr DR, Chapman JB, et al. Gallstone size and risk of pancreatitis. *Arch Intern Med* 1997; 157: 1674.