

## Case Report

# An unusual cause of bilioenteric anastomotic dysfunction after iatrogenic bile duct injury

Miguel Ángel Mercado;<sup>1</sup> Daniel Borja-Cacho;<sup>1</sup> Ismael Domínguez;<sup>1</sup> Eduardo Carrillo Maravilla;<sup>2</sup> Norberto Sánchez;<sup>1</sup> Eli Zavaleta-Martínez;<sup>2</sup> Arturo Ramírez-Muciño;<sup>1</sup> Alexandra Barajas-Olivas;<sup>1</sup> Ricardo Arceo-Olaiz<sup>1</sup>

## Abstract

**Roux en Y hepatojejunostomy is the surgery of choice for bile duct repair. Anastomotic dysfunction after reconstruction has several etiopathologies. Besides technical factors, ischemia of the duct is responsible for late obstruction. Bile colonization with secondary stones and sludge can also be identified as a cause. An unusual cause of anastomotic dysfunction secondary to ascaris biliary infestation after biliary reconstruction is reported herein. The patient had intermittent cholangitis and eosinophilia. At operation, the worm was found obstructing the anastomosis.**

**Key words: Biliary ascaris, hepatojejunostomy, bile duct injury.**

## Introduction

Injuries to the bile duct associated to laparoscopic cholecystectomy have a constant frequency all over the world (0.3–0.6 percent).<sup>1</sup> Complex injuries are defined as those that require a bilioenteric anastomosis. Roux en Y hepatojejunostomy is the surgery of choice in most centers devoted to bile duct repair after iatrogenic injury. This type of anastomosis has the best results in most centers because the long defunctionalized limb prevents reflux of the intestinal contents, warranting adequate drain-

age of the biliary tree. The outcome of those cases in which the bifurcation of the biliary tree is preserved is excellent in the long term.<sup>3</sup>

It has been a regular practice of our group to do hepatojejunostomies as the standard procedure for repair. Herein we report a case that developed an anastomotic dysfunction 6 years after the initial repair.

## Case report

A 62 year old female patient who was operated for cholecystectomy on 1999, had a complex injury (Strasberg E-3)<sup>4</sup> and was referred to our hospital with an external biliary fistula and abnormal liver function test. After complete preoperative evaluation the patient went into surgery where we performed a Roux en Y hepatojejunostomy at the bifurcation level. A 60 cm defunctionalized limb was constructed and an anastomosis was done at the confluence level with extension to the left duct after partial removal of segment IV and V. A high quality bilioenteric anastomosis was achieved using absorbable 5-0 monofilament sutures with everted knots, it is important to emphasize that the ducts were healthy, the anastomosis was tension free and with a wide lumen. Postoperative course was uneventful, the patient had follow-up every 6 months showing to be asymptomatic until the beginning of the 4<sup>th</sup> year after surgery. Abdominal ultrasound and hepatic function test were normal. She returned on February 2006 due to intermittent symptoms fully compatible with cholangitis (fever and jaundice). In a period of 10 to 18 days she developed 3 episodes that lasted 2 to 4 days each. A physician outside the hospital prescribed ursodeoxycholic acid and antibiotic therapy. When she returned to our hospital the only symptom she presented was mild choloria. Physical examination only revealed jaundice.

Hepatic function tests showed elevation of the alkaline phosphatase, transaminasemia (range of 100U) and hiperbilirrubinemia (at expense of the direct bilirubin). The patient had leukocytosis with 53% of eosinophiles.

Both magnetic resonance and cholangioresonance were done, showing partial defects at different levels near the anastomosis (*Figure 1*). With the diagnosis of late postoperative bilioenteric stenosis and/or lithiasis, the pa-

<sup>1</sup> Department of Surgery.

<sup>2</sup> Department of Internal Medicine.

Instituto Nacional de Ciencias Médicas y Nutrición "Salvador Zubirán".

Address for correspondence:

Miguel Ángel Mercado MD

Department of Surgery

Instituto Nacional de Ciencias Médicas y Nutrición "Salvador Zubirán".

Vasco de Quiroga Núm. 15

Tlalpan 14000 México, D.F.

Tel: (55) 5573 93 21

Fax: (55) 5573 93 21

E-mail: mercadiazma@yahoo.com

Manuscript received: 10 April, 2006

and accepted: 20 April, 2006.

tient went into surgery again. Interventional radiologist rejected the case for percutaneous dilatation.

During surgery, after isolation of the jejunal limb, the anastomosis was identified and an anterior opening was done obtaining sludge, debris and very small stones with a high mucous component. The anastomosis was completely dismantled and a tubular, mobile structure was identified crossing the anastomosis with the distal end returning to the biliary tree (Figure 2). After removing all the debris the tubular structures were extracted and a 25 cm *Ascaris lumbricoides* was obtained. Complete removal of debris, sludge and mucous was done and a new high quality bilioenteric anastomosis was done. Postoperative course was uneventful, the patient was able to leave the hospital 7 days after surgery. She renewed treatment with antibiotics and albendazol.

## Discussion

The nematode *Ascaris lumbricoides* is common in Asia, Africa and Central America. In endemic regions the frequency of infection can be as high as 90%. With the actual trip and migration opportunities *Ascaris* can now be observed world wide.

In humans, the adult worm can produce over 2,000,000 eggs/day. These are excreted with feces and later on they are eaten by the host. In humans they mature in the duodenum, producing larvae that cross the intestinal wall and reach the portal vein and the cardiopulmonar circulation. Larvae cross the alveoli ascending through the lumen of the trachea, once in the pharynx they are swallowed reaching the initial lumen where they reach their adult size and longitude (20–30 cm) with a life expectancy of 1 or 2 years.<sup>5</sup>

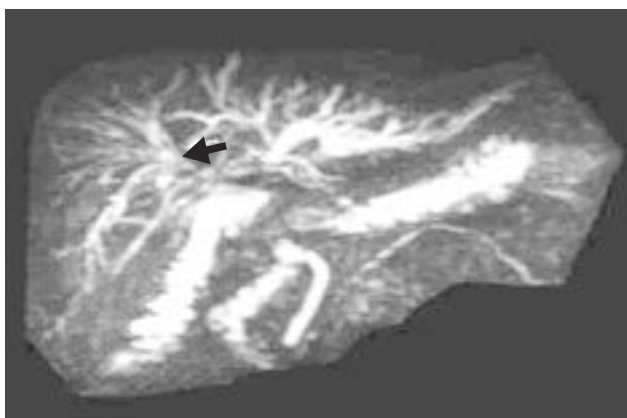
It is well known that the worm has the ability to reach the choledochus. Usually only one worms reaches the bile duct. Due to it size, part of the body remains in the duodenum with the consequent intermittent obstruction. Biliar obstruction also causes a chemical cholangitis and

can also be secondary to bacterial infection, causing an overlapped syndrome of bacterial cholangitis. Death worms can also cause a severe inflammatory reaction to the ducts producing sludge and calculi around the keratin component.<sup>6</sup>

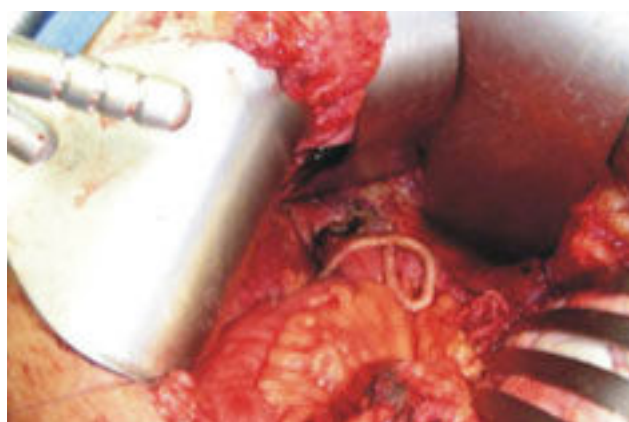Rarely, impacted worms in the liver produce worm nests that subsequently die because of immobilization. Abscesses can have rupture to the abdominal cavity or through the diaphragm to the lungs. Hemobilia has been described as well as pancreatitis.<sup>7–10</sup>

In patients with anatomical normal bile ducts and ascariasis infestation, indications of surgery are: persistent defects on cholangiography, cholangitis and/or obstructive symptoms refractory to medical treatment and complications related to stenosis and chemical inflammation of the ducts. The worms are most commonly removed with endoscopes, biopsy forceps and/or Dormia basket.<sup>11,12</sup> Pharmacologic treatment should not be delayed more than 6 weeks due to the risk of inflammatory reaction secondary to the worm death.<sup>13</sup>

Anastomotal dysfunction after bile duct reconstruction has several etiopathologies. Besides technical factors related to the reconstruction, ischemia is responsible for late stenosis of the anastomosis. Indeed, many surgeons not familiar with reconstructions techniques perform non high quality anastomosis, using inadequate sutures for small ducts. Also tension of the anastomosis is responsible for late dysfunction.<sup>14</sup> Other factors are related to colonization of bile that promotes sludge, micro stones and debris development. Other causes of dysfunction are sporadic and individual in their origin. To our knowledge this is the first case reported of anastomotal dysfunction related to *Ascaris* infection. The predominant symptoms were cholangitis and peripheral eosinophilia secondary to partial and intermittent obstruction of the worm. Although radiological findings of hepatic ascariasis have been well described,<sup>15</sup> only retrospectively the radiological image of the worm was identified.



**Figure 1.** MRI showing *Ascaris* contour. (Black arrow).



**Figure 2.** Operative scenery.

## References

1. Flum DR, Dellinger EP, Cheadle A, Chan L, Koepsell T. Intraoperative cholangiography and risk of common bile duct injury during cholecystectomy. *JAMA* 2003; 289: 1639-44.
2. Sicklick JK, Camp MS, Lillemoe KD, Melton GB, Yeo CJ, Campbell KA, Talamini MA. Surgical management of bile duct injuries sustained during laparoscopic cholecystectomy. *Ann Surg* 2005; 241: 786-98.
3. Mercado MA, Chan C, Orozco H, Hinojosa CA, Podgaetz E, Ramos-Gallardo G, Galvez-Treviño R, et al. Prognostic implications of preserved bile duct confluence after iatrogenic injury. *Hepatogastroenterology* 2005; 52: 40-4.
4. Strasberg SM, Herd M, Soper NJ. An analysis of the problem of biliary injury during laparoscopic cholecystectomy. *J Am Coll Surg* 1995; 180: 102-28.
5. Khuroo MS. Ascariasis. *Gastroenterol Clin North Am* 1996; 25: 553-77.
6. Van Severen M, Lengele B, Durevil J, Shapira M, Dive C. Hepatic ascariasis. *Endoscopy* 1987; 19: 140-42.
7. Lloyd DA. Massive hepato-biliary ascariasis in childhood. *British J Surg* 1981; 68: 468-73.
8. Pillay JP, Baker LW, Anjom IB. *Ascaris lumbricoides* producing obstructive jaundice. *J R Coll Surg Edinb* 1978; 23(1): 25-9.
9. Saw HS, Somasundaram K, Kamath K. Hepatic ascariasis. *Arch Surg* 1974; 108: 733-35.
10. Winters C Jr, Chobanian SJ, Benjamin SB, Ferguson RK, Cattau EL. Endoscopic documentation of *Ascaris*-induced acute pancreatitis. *Gastrointest Endosc* 1984; 30: 83-4.
11. Mirra SP, Dwivedi MR. Removal of *Ascaris lumbricoides* from the bile duct using balloon sphincteroplasty. *Endoscopy* 1998; 30: 56-7.
12. Ramírez-Degollado J, Peniche-Bojórquez J. Diagnosis and treatment of ascariasis of the choledochus by endoscope cholangiography. *Gac Med Mex* 1978; 114: 401-02.
13. Bahu Mda G, Baldisseroto M, Custodio CM, Stachler CZ, Mangili AR. Hepatobiliary and pancreatic complications of ascariasis in children: a study of seven cases. *J Pediatr Gastroenterol Nutr* 2001; 33: 271-78.
14. Mercado MA, Chan C, Orozco H, Villalta JM, Barajas-Olivas A, Eraña J, Domínguez I. Long term evaluation of biliary reconstruction after partial resection of segments IV and V in iatrogenic injuries. *J Gastrointest Surg* 2006; 10: 77-82.
15. Bude RO, Bowerman RA. Case 20: Biliary ascariasis. *Radiology* 2000; 214: 844-47.