

Concise Review

Hepatopulmonary syndrome - Past to present

Joye Varghese;¹ Haseeb Ilias-basha;² Ravishanker Dhanasekaran;² Shivakumar Singh;² Jayanthi Venkataraman¹

Abstract

Hepatopulmonary syndrome (HPS) is the one of the complication of liver cirrhosis with portal hypertension, irrespective of etiology, age and sex. It has also been observed in non cirrhotic portal hypertension and in acute hepatic conditions. Presence of hypoxemia or abnormal alveolar arterial oxygen tension with intrapulmonary vasodilation in liver cirrhosis is termed as HPS. Contrast echocardiogram is the better screening tool to demonstrate intrapulmonary shunt. Clinicians should be aware of other common chronic pulmonary and cardiac comorbid conditions, in particular COPD, tuberculosis, bronchial asthma and idiopathic pulmo-

nary fibrosis, etc. which may coexist with HPS. There is no specific clinical finding to diagnose but digital clubbing, cyanosis, dyspnoea, platypnoea, and spider naevi are more common among cirrhosis with HPS. The presence of HPS independently worsens prognosis of cirrhosis. Even though number of mechanisms have been proposed to explain arterial hypoxemia in HPS, role of nitric oxide is the major one along with cytokines. Liver transplantation is the choice of treatment though mortality is comparatively high. There is no still effective recommended medical therapy to reverse this condition and anti cytokine/ nitric oxide inhibitors, etc are under preliminary stage.

Key words: Hepatopulmonary syndrome, intra pulmonary vasodilation, hypoxia in cirrhosis.

¹ Medical Gastroenterology

² Department of Medicine

Stanley Medical College Hospital, Chennai, India.

Abbreviations

HPS - Hepatopulmonary syndrome
POPH - Portopulmonary hypertension
P (A-a)O₂ - Alveolar - arterial oxygen tension gradient
PaO₂ - Arterial oxygen tension
SaO₂ - Arterial oxygen saturation
NO - Nitric oxide
NOS - Nitric oxide synthase
iNOS - inducible nitric oxide synthase
eNOS - endogenous nitric oxide synthase
NG-LNAME - NG-nitro-L-arginine methyl ester
Cyclic GMP - Cyclic guanosine monophosphate
ET-B receptors - Endothelin B receptor
TNF α - Tumor necrotizing factor- α
sGC - Soluble guanylyl cyclase
MARK - Mitogen-activated protein kinase
CBDL - Common Bile Duct Ligation
cAMP - cyclic adenosine monophosphate
ABG - Arterial blood gas
ERS Task Force - European Respiratory Society Task Force
Tc-99m MAA - 99mTechnetium macroaggregated albumin
DLCO - Carbon monoxide diffusing capacity
CT - Computerized tomography
TIPS - Transjugular intrahepatic portosystemic shunt

Address for correspondence:

Dr. Joye Varghese MD

Department of Medical Gastroenterology,

Stanley Medical College Hospital,

Chennai, India

E-mail: joyevargese@gmail.com

Manuscript received and accepted: 22 April and 7 July 2007

Introduction

Hepatopulmonary syndrome (HPS) is a pulmonary vascular disorder, complicating hepatic diseases, most frequently liver cirrhosis and even though it is an indication for liver transplant, it is responsible for an increased morbidity and mortality among patients awaiting liver transplantation.^{1,2} Interestingly, the relationship between hepatopulmonary syndrome and liver cirrhosis dates back to 1884 when Fluckiger first described based on an observation of a woman with cyanosis, clubbing and cirrhosis.³ However, the term "Hepatopulmonary syndrome" was coined by Kennedy and Knudson in 1977.⁴ The prevalence of HPS in the setting of cirrhosis ranges between 4% - 30%.⁵⁻⁸ Portopulmonary hypertension (POPH) is another distinct pulmonary complication of chronic liver disease but prevalence is 2-16% and is only considered proven, if other causes of the pulmonary hypertension than the high portal pressure are excluded.⁵ Transplant hospitalization mortality was 16% in patients with HPS and 36% in patients with Portopulmonary hypertension.⁹

Definition

HPS may be classically defined by a widened alveolar - arterial oxygen gradient P (A-a)O₂ in room air (> 15 mmHg, or > 20 mmHg in patients > 64 years of age) with or without hypoxemia resulting from intrapulmonary vasodilation in the presence of hepatic dysfunction or por-

tal hypertension.¹⁰⁻¹² It is now evident that HPS can co exist with other cardio pulmonary abnormalities and can contribute to gas exchange abnormalities in this setting.^{13,14} In addition, as the $P(A-a)O_2$ normally increases with age and varies significantly even in healthy individuals, it is therefore recommended to use values above the 95% confidence interval for the age- corrected $P(A-a)O_2$ to avoid over – diagnosis of HPS.¹⁵ The intrapulmonary vasodilation is characterized by either diffuse or localized and, less commonly, pleural and pulmonary arteriovenous communications. Although HPS is predominantly seen in middle-aged patients without sex difference, it can also occur in children.^{16,17}

Etiopathogenesis

The etiopathogenesis of this syndrome remains unknown. The most commonly accepted hypothesis postulates that there is inadequate synthesis or metabolism of pulmonary vasoactive substances such as nitric oxide, prostaglandins, vasoactive intestinal peptide, calcitonin, glucagon, substance P and atrial natriuretic factor, by the impaired liver leading to a functional vasodilatation of the pulmonary vasculature producing hypoxemia.¹⁸⁻²⁶ HPS is found most commonly in the setting of cirrhosis, both less and advanced forms.²⁷⁻²⁹ HPS is also recognized in patients with portal hypertension in the absence of cirrhosis such as in portal vein thrombosis, nodular regenerative hyperplasia, congenital hepatic fibrosis and Budd- Chiari syndrome²⁹⁻³² and also in the setting of acute and chronic hepatitis in the absence of portal hypertension.^{33,34} Transient HPS is been reported in acute hepatitis A.¹²

Following are the mechanisms underlying impaired gas exchange in HPS³⁵

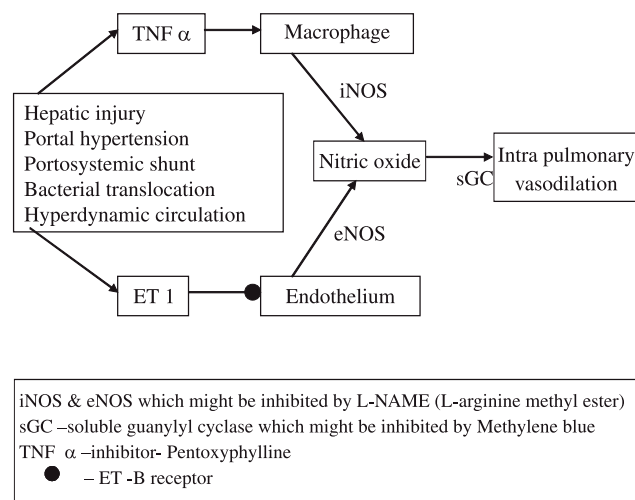
- changes in the affinity of hemoglobin for oxygen³⁶⁻³⁸
- intrapulmonary and portopulmonary shunt^{6,39-42}
- alveolar capillary diffusion limitation^{6,40}
- ventilation-perfusion inequality⁴³⁻⁴⁷ and
- combinations of these factors.

The pathogenetic hallmark of HPS is microvascular dilatation within the pulmonary arterial circulation.^{6,41} These changes may result from decreased pre-capillary arteriolar tone alone or could involve additional mechanisms such as angiogenesis, remodeling, and vasculogenesis, which have been recently suggested.⁴⁸ In human models, the vasodilatation is assumed to result from excessive vascular production of vasodilators, particularly nitric oxide (NO). This has been based on the observation that exhaled NO levels, a measure of pulmonary production, is increased in cirrhotic patients with HPS⁴⁹ and normalizes after OLT⁵⁰⁻⁵² as HPS resolves. Pulmonary alveoli is a major source of increased NO production in cirrhotic patients⁵³ and also overexpression of both inducible

(iNOS) and constitutive (eNOS) isoforms are seen in alveolar macrophages and pulmonary endothelial cells of cirrhotics, respectively.^{54,55}

In addition, a case report revealed that acute inhibition of NO production or action with NG-nitro-L-arginine methyl ester (LNAME) or cyclic GMP inhibitor methylene blue, respectively, transiently improves HPS.⁵⁶⁻⁵⁸ However, a recent study found that administration of inhaled L-NAME did not acutely improve intrapulmonary vasodilatation,⁵⁰ raising the possibility that factors other than NOS-derived NO effects on vascular tone contribute to HPS. Early studies have proposed that hemoglobin acts solely as a sink limiting NO access to vascular smooth muscle and opposing its vasodilatation role and inactivating it.⁵⁹ An emerging hypothesis is that NO additionally functions as a hormone. More recent work has shown that hemoglobin functions as both a reservoir and a vehicle for NO bioactivity.^{60,61}

Sztrymf et al.,⁶² demonstrated that inhibition of TNF- α synthesis and iNOS induction by pentoxifylline prevented HPS and the hyperdynamic circulatory syndrome. Overexpression of pulmonary ET-B receptors, also stimulates NO release in HPS.^{63,64}



Intestinal endotoxemia accompanying cirrhosis may be an important factor in the development of hepatopulmonary syndrome.⁶⁵ The mononuclear-phagocyte system of the liver is important in clearing organisms from the portal circulation. During genesis of cirrhosis, the drained portal blood is obstructed, leading to swollen mucosa and weakened intestinal movements and decreased secretion of bile, which bring about the massive bacterial overgrowth in the lumen of the bowel, particularly profusion of Gram-negative enteric organisms and the production of endotoxin. On the other hand, defects in mucosal barrier function, reduction in healthy normal functioning hepatocytes and Kupffer cells and portal-systemic shunts can cause invasion of enteric organisms/en-

dotoxin into blood and resulted in bacteremia and intestinal endotoxemia. Endotoxin itself in turn impairs mitochondria and lysosome in enteric epithelial cells with cell autolysis. Ultimately, a vicious cycle is formed between intestinal endotoxemia and the permeability of enteric mucosa.⁶⁶ Overproduction of TNF- α due to endotoxin stimulation of Kupffer cells via mitogen-activated protein kinase (MAPK) signal transduction pathway may be a major mechanism mediating the pathological alterations of hepatopulmonary syndrome.⁶⁵

In addition, whether other mediators such as heme oxygenase derived carbon monoxide might contribute to intrapulmonary vasodilatation and would explain the lack of improvement of HPS with NO inhibition in some patients has not yet been established.⁶⁶

In animal models, however, there was a close correlation between decreased O_2 and endotoxin. Metabolic acidosis accompanying respiratory alkalosis is the primary type of acid-base imbalance. The alveolar-arterial oxygen gradient is sharply widened. Massive accumulation of giant macrophages in the alveolar spaces and its wall and widened alveolar wall architecture have been observed. The ratio of TC99M-MAA brain-over-lung radioactivity is increased. Endotoxin, TNF- α , endothelin-1 (ET-1), nitric oxide (NO) in plasma and carbon monoxide (CO) in lung homogenates are increased.⁶⁵ The number of bacterial translocations in mesenteric lymph nodes are increased.

In addition, prolonged treatment of CBDL (common Bile Duct Ligation) animals, at the time of ligation with norfloxacin to inhibit bacterial translocation and tumor necrosis factor- α (TNF- α) production, decreases macrophage accumulation and prevents the transient increase in iNOS,⁶⁸ supporting that TNF- α contributes to macrophage accumulation. Further, pentoxifylline, a non-specific phosphodiesterase inhibitor that increases intracellular cAMP levels and also inhibits TNF- α production in macrophages,⁶⁹ given over a similar time frame can prevent the onset or decrease the severity of HPS.⁶² These agents initiated at the onset of liver injury can influence the development of the hyperdynamic state and may modify endothelin type B receptor expression and endothelin related signaling events in the pulmonary microvasculature.

Hypoxemia is postulated to be due to decreased oxygen diffusion across the dilated vessels along with a decrease in intrapulmonary blood transit time. The blood transit time is decreased due to the low vascular resistance in the intrapulmonary dilatations and the associated hyperdynamic circulation characteristic of liver disease.⁷⁰ Therefore, there is no true shunt and the PaO_2 can be significantly improved by supplementing oxygen. Finally, HPS patients have also been found to have decreased hypoxic pulmonary vascular constriction.^{45,71} Moreover, it is now evident that intrapulmonary vascular dilatations oc-

cur in one of the two patterns, viz. the more common Type I lesions characterized by diffuse pulmonary vascular dilatations with a good PaO_2 response to 100% oxygen, and Type II lesions are more discrete, localized dilatations that have a poor response to oxygen.⁷²

Clinical features

The clinical features of HPS typically manifest as respiratory complaints and findings associated with chronic liver disease. The insidious onset of dyspnoea, particularly on exertion, is the most common complaint⁷³ but is non-specific. Platypnoea (shortness of breath exacerbated by sitting up and improved by lying supine) is a usual symptom.⁷⁴

Orthodeoxia, defined as arterial deoxygenation accentuated in the upright position *versus* the supine position, has been observed in a variety of conditions such as post-pneumonectomy, recurrent pulmonary thromboemboli, and atrial septal defects. It is highly specific for HPS in the setting of liver disease.⁷⁵ The sensitivity of orthodeoxia for HPS is relatively low, but increases in cases of severe HPS.^{76,77} A cutoff value for orthodeoxia is defined by a PaO_2 decrease of 5% or more, or 4 mmHg or more from the supine to upright position.⁵⁰ Its reported prevalence range is from 20% to 80% in patients with HPS.⁷³

Cough is not a common in HPS. Spider angiomas are commonly reported in HPS but are frequently seen in cirrhotic patients without HPS. One study observed that patients with these cutaneous lesions had more pulmonary vasodilatation and higher alveolar-arterial oxygen gradients than those without vascular spiders (A-a PO_2 : 20 mmHg *versus* 8 mmHg).⁷⁸ Clubbed fingers are common and the presence of spider nevi has been considered as one of the most sensitive clinical marker.⁷⁹

Diagnosis

A key factor in the diagnosis of HPS is the exclusion of causes other than HPS that may be involved in cirrhosis presenting with hypoxemia. These include intrinsic cardiopulmonary abnormalities, pulmonary atelectasis, pneumonia, ascites, pulmonary edema or hepatic hydrothorax. In cirrhotic patients with clinical symptoms and arterial blood gas compatible with hypoxemia, a chest X-ray must first be taken to rule out reversible conditions. Pulmonary function test should be performed to rule out the common intrinsic pulmonary disorders such as chronic obstructive pulmonary disease. HPS should be suspected in patients who have persistent hypoxia despite a normal chest X-ray or after following optimal treatment of the underlying conditions.⁷⁹

The P (A-a) O_2 seems to be an ideal parameter for the assessment of abnormalities of arterial oxygenation⁸⁰ in HPS. In cirrhosis patients, pulse oximetry may overestimate SaO_2 in nearly one half of patients.⁸¹ In all cirrhosis

patients, in order to reliably detect hypoxemia, arterial blood gas analysis (ABG) analysis should therefore be considered when the SaO_2 value is 97% or less. In addition, if hypoxemia or HPS is strongly suspected based on history and physical examination, ABG analysis should be performed while breathing room air regardless of pulse oximetry. In HPS, ABG reveal an elevated age-adjusted $\text{P}(\text{A-a})\text{O}_2$ with or without hypoxemia. The expected upper limit of normal for room-air $\text{P}(\text{A-a})\text{O}_2$ at a given age ($> 95\%$ confidence interval) can be calculated using the following equation: $\text{P}(\text{A-a})\text{O}_2 = [0.26 \text{ age} - 0.43] + 10$.¹⁵

The ERS Task Force⁽¹²⁾ has proposed a classification system that uses arterial oxygen tension (PaO_2) to stage the severity of HPS. According to this system, a $\text{PaO}_2 < 50$ mmHg indicates very severe HPS, a PaO_2 in between 50 to 60 mmHg suggests moderate HPS and a PaO_2 in between 60 and 80 mmHg corresponds with mild HPS. (Table) Staging the severity of HPS is important as a means of predicting survival and determining the timing and risks of orthotopic liver transplantation.⁸²

Stage	$\text{P}_{(\text{A-a})\text{O}_2}$ mmHg	P_{aO_2} mmHg
Mild	≥ 15	≥ 80
Moderate	≥ 15	$< 80 - \geq 60$
Severe	≥ 15	$< 60 - \geq 50$
Very severe	≥ 15	< 50

Contrast enhanced echocardiography is the preferred screening test for HPS.⁸³ It uses agitated saline or indocyanine green to produce microbubbles at least 15 μm in diameter which are then injected intravenously. Under normal circumstances, these microbubbles are trapped in the pulmonary microvasculature and then absorbed.^{84,85} In patients with intracardiac or intrapulmonary shunting, these microbubbles appear in the left sided of the cardiac chamber.⁸⁶ Differentiation between intracardiac and intrapulmonary shunting is based on the timing of when these bubbles are found in the left side chamber of the heart. In intracardiac right-to-left shunts, these bubbles appear in the left chamber of the heart within 3 heartbeats after they appear in the right chamber of the heart. In intrapulmonary shunts, these bubbles appear in 4-6th heartbeats. Moreover studies revealed that transesophageal echocardiography is more sensitive than transthoracic echocardiography in demonstrating intrapulmonary shunting.⁸⁷ In a patient with liver disease or portal hypertension, hypoxemia with positive contrast echocardiogram in the absence of significant cardiopulmonary disease, the diagnosis of hepatopulmonary syndrome can be considered. The disadvantages are, it cannot quantify the shunting, it cannot differentiate between intrapulmonary vascular dilatation and direct arteriovenous communication and, even though contrast echocardiography is highly sensitive for HPS, it lacks specificity.⁸⁸ Finally, in pa-

tients with concomitant intrinsic lung diseases, the contribution of HPS to arterial desaturation cannot be defined by contrast echocardiography.⁸²

In order to overcome the disadvantages of contrast echocardiography, 99mTechnetium macroaggregated albumin (Tc-99m MAA) lung perfusion scan is used to diagnose HPS.⁸⁹⁻⁹¹ The albumin macroaggregates are more than 20 μm in diameter. Under normal circumstances, they are entrapped in the pulmonary vasculature. In patients with intracardiac or intrapulmonary shunts, these albumin macroaggregates can escape from the pulmonary vasculature and be taken up by other organs. In healthy individuals, less than 5% of isotope can be quantified in the brain. In HPS patients, the fraction is more than 6%. In a cohort study, Tc-99m MAA lung perfusion scan identified all cirrhotic patients with HPS who presented with moderate to severe hypoxemia, and yielded negative results in those without HPS and in all non-cirrhotic hypoxic patients with intrinsic lung disease. Thus, Tc-99m MAA scan may be useful test for the diagnosis of HPS. In cirrhotic patients with concomitant intrinsic pulmonary disorders, the fraction of Tc-99m MAA scan can define the significance of the HPS in clinical hypoxemia.¹⁴ That study also showed an inverse correlation between the magnitude of the shunt fraction and arterial oxygen saturation. The major disadvantage of Tc-99m MAA scan is that it cannot differentiate intracardiac from intrapulmonary shunting. The shunt fraction of Tc-99m MAA scan also does not correlate with the response of PaO_2 after institution of 100% oxygen.

While abnormal pulmonary function studies are frequently observed in HPS, these lack specificity.⁸² In the absence of concomitant obstructive or restrictive lung disease, measurements of total lung capacity and expiratory flow rates in HPS patients are generally normal. Diffusion impairment is commonly seen in HPS.⁸⁸ In one study, the diffusing capacity for carbon monoxide (DLCO) was less than 80% of the predicted value in 15 of 18 patients with HPS.⁷⁸ However, the presence of decreased DLCO with normal spirometry is not specific for HPS, and is routinely observed in patients with early interstitial lung disease, vasoocclusive disease, and profound anemia.

A pulmonary arteriography study in patients with HPS reveal two types of vascular patterns,⁸⁹ type I or diffuse pattern and the type II or focal pattern. The minimal diffuse type I pattern is characterized by the presence of normal vessels or finely diffuse spiderly vascular abnormalities. The advanced type I pattern is characterized by a diffuse spongy or blotchy appearance. The type II pattern is a less frequent finding. Patients with advanced type I or type II patterns show a poor response to 100% oxygen. Pulmonary angiography is expensive and invasive and has a low sensitivity for detecting intrapulmonary vasodilatation. Therefore, it is not routinely utilized in the diagnosis of HPS.

High-resolution chest computerized tomography (CT) and evaluation of pulmonary blood transit time are newer diagnostic modalities for assessing HPS. In one study, the degree of pulmonary microvascular dilation observed on chest CT correlate with the severity of gas exchange abnormalities in patients with HPS, suggesting that quantification of intrapulmonary vasodilatation was possible.⁹⁰ In yet another study, pulmonary transit time of erythrocytes, measured by echocardiographic analysis of human serum albumin air microbubble complexes through the heart, also correlated with gas exchange abnormalities in a small group of patients with HPS.⁹¹ Whether these techniques have diagnostic utility for HPS remains to be determined.

Treatment and prognosis

Liver transplantation is the only established effective therapy for HPS based upon the total resolution or significant improvement in gas exchange post-operatively in more than 85% of reported patients.⁹² In a retrospective study by Krowka et al.⁹³ an improvement or normalization of hypoxemia in about 80% of patients after liver transplantation. However, duration for arterial hypoxemia to normalize after transplantation is variable and may be more than 1 year.⁹² In addition, mortality is increased after transplantation in patients who have HPS compared with subjects who do not have HPS,⁹⁴ and unique post-operative complications, including pulmonary hypertension,⁹⁵ cerebral embolic hemorrhages,⁹⁶ and immediate postoperative deoxygenation requiring prolonged mechanical ventilation.⁹⁷ Innovative approaches such as frequent body positioning⁹⁸ or inhaled NO^{93,99} have been used to improve post-operative gas exchange even though exact pathophysiology is unknown. Further investigations have focused on the peri-operative medical management of HPS patients to optimize survival.

Oxygen supplementation remains the mainstay of therapy for HPS patients when $\text{PaO}_2 < 60$ mmHg or in conditions with exercise-induced oxygen desaturation. Anecdotal evidence supports that enhancement of arterial oxygenation improves exercise tolerance and quality of life in hypoxemic patients with HPS. Hypoxemia is well recognized to adversely affect hepatocyte function¹⁰⁰ and so oxygen supplementation is a low risk treatment option.

The effects of transjugular intrahepatic portosystemic shunt (TIPS) on HPS in cirrhosis are limited and controversial. In one study, TIPS failed to improve oxygenation in one patient and in two patients HPS was precipitated in the setting of functional TIPS.¹⁰¹

There are currently no effective medical therapies for HPS. Small uncontrolled studies have reported a lack of efficacy using sympathomimetic agents, somatostatin, almitrine, indomethacin, and plasma exchange.²⁵ Aspi-

rin increased arterial oxygenation in two children who had HPS.¹⁰² A case report¹⁰³ and subsequent open label trial¹⁰¹ using garlic also suggest a beneficial effect. In the latter trial, garlic powder was administered for a minimum of 6 months. Six of 15 (40%) patients with HPS showed improvements greater than 10 mmHg in the PaO_2 , and one subject have had resolution of hypoxemia (PaO_2 : 46-80 mmHg) over a 1.5-year period. Acute infusion of methylene blue, a dye that inhibits the effect of NO on soluble guanylate cyclase, has also shown a transient improvement in oxygenation in eight patients.⁵⁷ Acute administration of inhaled L-NAME, to inhibit nitric oxide production, also transiently has improved oxygenation in one patient (PaO_2 : 52-70 mmHg), but failed to significantly alter oxygenation in another group of 10 patients.⁵⁸ Finally, a single case report suggests that norfloxacin also may have contributed to improvement in oxygen saturation in HPS.¹⁰⁴ These reports do underscore the need to evaluate agents targeted at likely pathogenetic mechanisms in randomized multi-center trials.

Conclusion

HPS occurs when pulmonary microvascular dilatation impairs arterial oxygenation in the setting of liver disease or portal hypertension. The syndrome is found in up to 15-20% of patients with cirrhosis and should be considered in any patient with chronic liver disease who develops dyspnoea or hypoxemia. The presence of HPS increases mortality in the setting of cirrhosis and may influence the frequency and severity of complications of portal hypertension. The recognition in experimental models that a unique sequence of molecular alterations leads to endothelin-1 and TNF- α modulation of pulmonary microvascular tone may lead to the development of novel and effective medical therapies. Contrast echocardiography and standard cardiopulmonary testing are generally sufficient to make the diagnosis of HPS but further testing may be needed in patients who have both intrinsic cardiopulmonary disease and intrapulmonary vasodilatation. Treatment comprises of supplemental oxygen and orthotopic liver transplantation if significant hypoxemia is present.

References

1. Mazzeo AT, Bottari G, Pratico C, Penna O, Mandolino T, Santamaria LB. Significance of hypoxemia screening in candidates for liver transplantation: our experience. *Transplant Proc* 2006; 38(3): 793-794.
2. Allgaier HP, Haag K, Blum HE. Hepatopulmonary syndrome. *Z Gastroenterol* 1998; 36(3): 247-251.
3. Fluckiger M. Vorkommen von trommelschlägelförmigen fingerendphalangen ohne chronische veränderungen an der lungen oder am herzen. *Wien Med Wschr* 1884; 34: 1457.
4. Kennedy TC, Knudson RJ. Exercise aggravated hypoxemia and orthodeoxia in cirrhosis. *Chest* 1997; 72: 305-319.

5. Dollinger MM. Pulmonary complication in liver disease. *Schweiz Rundsch Med Prax* 2006; 95(40): 1539-1542.
6. Krowka MJ, Tajik AJ, Dickson ER, Wiesner RH, Cortese DA. Intrapulmonary vascular dilatations (IPVD) in liver transplant candidates: screening by two-dimensional contrast-enhanced echocardiography. *Chest* 1990; 97: 1165-1170.
7. Stoller J, Lange P, Westveer M, Carey W, Vogt D, Henderson M. Prevalence and reversibility of the hepatopulmonary syndrome after liver transplantation—the Cleveland Clinic experience. *West J Med* 1995; 163(2): 133-138.
8. Abrams GA, Jaffe CC, Hoffer PB, Binder HJ, Fallon MB. Diagnostic utility of contrast echocardiography and lung perfusion scan in patients with hepatopulmonary syndrome. *Gastroenterology* 1995; 109: 1283-1288.
9. Stoller JK, Moodie D, Schiavone WA. Reduction of intrapulmonary shunt and resolution of digital clubbing associated with primary biliary cirrhosis after liver transplantation. *Hepatology* 1990; 11(1): 54-58.
10. Lange PA, Stoller JK. The hepatopulmonary syndrome. *Ann Intern Med* 1995; 122: 521-529.
11. Schenk P, Fuhrmann V, Madl C, Funk G, Lehr S, Kandel O, Muller C. Hepatopulmonary syndrome: prevalence and predictive value of various cut offs for arterial oxygenation and their clinical consequences. *Gut* 2002; 51: 853-859.
12. Rodriguez-Roisin R, Krowka MJ, Herve P, Fallon MB. Pulmonary-Hepatic vascular Disorders. *Eur Respir J* 2004; 24: 861-880.
13. Martinez G, Barbera J, Navasa M, Roca J, Visa J, Rodriguez-Roisin R. Hepatopulmonary syndrome associated with cardiorespiratory disease. *J Hepatol* 1999; 30: 882-889.
14. Abrams G, Nanda N, Dubovsky E, Krowka M, Fallon M. Use of macroaggregated albumin lung perfusion scan to diagnose hepatopulmonary syndrome: a new approach. *Gastroenterology* 1998; 114: 305-310.
15. Harris E, Kenyon A, Nisbet H, Seelye E, Whitlock R. The normal alveolar-arterial oxygen-tension gradient in man. *Clin Sci Mol Med* 1974; 46: 89-104.
16. Silverman A, Cooper MD, Moller JH, Good RA. Syndrome of cyanosis, digital clubbing, and hepatic disease in siblings. *J Pediatr* 1968; 72: 70-80.
17. Crary GS, Burke BA, Alford BA, du Cret RP, Wood BP. Radiological cases of the month. Pulmonary arteriovenous shunting in a child with cirrhosis of the liver. *Am J Dis Child* 1989; 143: 749-751.
18. Krowka MJ, Mandell MS, Ramsay MA, et al. Hepatopulmonary syndrome and portopulmonary hypertension: a report of the multicenter liver transplant database. *Liver Transpl* 2004; 10(2): 174-182.
19. Jiva TM. Unexplained hypoxemia in liver disease: The hepatopulmonary syndrome. *J Crit Illness* 1994; 9(10): 934-47.
20. Bruix J, Bosch J, Kravetz D, et al. Effects of prostaglandin inhibition on systemic and hepatic hemodynamics in patients with cirrhosis of the liver. *Gastroenterology* 1985; 88: 430-435.
21. Pizcueta P, Pique JM, Fernandez M, et al. Modulation of the hyperdynamic circulation of cirrhotic rats by nitric oxide inhibition. *Gastroenterology* 1992; 103: 1909-15.
22. Henriksen JH, Staun-Olsen P, Fahrenkrug P, et al. Vasoactive intestinal polypeptide in cirrhosis Arteriovenous extraction in different vascular beds. *Scand J Gastroenterol* 1980; 15: 787-792.
23. Krowka MJ, Cortese DA. Hepatopulmonary syndrome: an evolving perspective in the era of liver transplantation. *Hepatology* 1990; 11: 138-142.
24. Macro J, Diego J, Vilanueva ML, et al. Elevated plasma glycogen levels in cirrhosis of the liver. *N Engl J Med* 1973; 289: 1107-1111.
25. Hortnagl H, Singer EA, Lenz K, et al. Substance-P is markedly increased in plasma of patients with hepatic coma. *Lancet* 1984; 1: 480-483.
26. Gines P, Jimenez W, Arroyo V, et al. Atrial natriuretic factor in cirrhosis with ascites: Plasma levels, cardiac release and splanchnic extraction. *Hepatology* 1988; 8: 636-642.
27. Krowka M, Wiseman G, Burnett O, Spivey J, Therneau T, Porayko M, Wiesner R. Hepatopulmonary syndrome: a prospective study of relationships between severity of liver disease, PaO₂ response to 100% oxygen, and brain uptake after 99mTc MAA lung scanning. *Chest* 2000; 118: 615-624.
28. Whyte M, Hughes J, Peters A, Ussov W, Patel S, Burroughs A. Analysis of intra pulmonary right to left shunt in hepatopulmonary syndrome. *J Hepatol* 1998; 29: 85-93.
29. Dimand RJ, Heyman MB, Bass NM, Lavine JE, Lake JR, Roberts JP. Hepatopulmonary syndrome: response to hepatic transplantation. *Hepatology* 1991; 141: 155.
30. Abrams G, Fallon M. Hepatopulmonary syndrome. *Clin Liver Dis* 1997; 1: 185-200.
31. Binay K, Sen S, Biswas PK, Sanyal R, Jumdar DM, Biswas J. Hepatopulmonary syndrome in inferior vena cava obstruction responding to cavoplasty. *Gastroenterology* 2000; 118: 192-196.
32. Gupta D, Vijaya DR, Gupta R, Dhiman RK, Bhargava M, Verma J. Prevalence of hepatopulmonary syndrome in cirrhosis and extrahepatic portal venous obstruction. *Am J Gastroenterol* 2001; 96: 3395-3399.
33. Regev A, Yeshurun M, Rodriguez M, Sagie A, Neff G, Molina E. Transient hepatopulmonary syndrome in a patient with acute hepatitis A. *J Viral Hep* 2001; 8: 83-86.
34. Teuber G, Teupe C, Dietrich C, Caspary W, Buhl R, Zeuzem S. Pulmonary dysfunction in non-cirrhotic patients with chronic viral hepatitis. *Eur J Intern Med* 2002; 13: 311-318.
35. Lange PA, Stoller JK. The Hepatopulmonary Syndrome. *Annals of Internal Medicine* 1995; 122: 521-529.
36. Keys A, Snell AM. Respiratory properties of the arterial blood in normal man and in patients with disease of the liver: Position of the oxygen dissociation curve. *J Clin Invest* 1938; 17: 59-67.
37. Caldwell PR, Fritts HW, Cournard A. Oxyhemoglobin dissociation curve in liver disease. *J Appl Physiol* 1965; 20: 316-20.
38. Astrup J, Rorth M. Oxygen affinity of hemoglobin and red cell 2,3-diphosphoglycerate in hepatic cirrhosis. *Scand J Clin Lab Invest* 1973; 31: 311-317.
39. Krowka MJ, Cortese DA. Hepatopulmonary syndrome (Editorial). *Chest* 1990; 98: 1053-1054.
40. Hedenstierna G, Soderman C, Eriksson LS, Wahren J. Ventilation-perfusion inequality in patients with non-alcoholic liver cirrhosis. *Eur Respir J* 1991; 4: 711-717.
41. Davis HH 2d, Schwartz DJ, Lefrak SS, Susman N, Schainker BA. Alveolar-capillary oxygen disequilibrium in hepatic cirrhosis. *Chest* 1978; 73: 507-511.
42. Calabresi P, Abelmann WH. Portocaval and porto-pulmonary anastomoses in Laennec's cirrhosis and in heart failure. *J Clin Invest* 1957; 36: 1257-1265.
43. Ruff F, Hughes JM, Stanley N, McCarthy D, Greene R, Aronoff A, et al. Regional lung function in patients with hepatic cirrhosis. *J Clin Invest* 1971; 50: 2403-2413.
44. Daoud FS, Reeves JT, Schaefer JW. Failure of hypoxic pulmonary vasoconstriction in patients in patients with liver cirrhosis. *J Clin Invest* 1972; 51: 1076-1080.
45. Naeije R, Hallemans R, Mols P, Melot C. Hypoxic pulmonary vasoconstriction in liver cirrhosis. *Chest* 1981; 80: 570-574.
46. Kobayashi S, Aida A, Aio K, Nishimura M, Kawakami Y. Liver cirrhosis with severe hypoxemia and paradoxical pulmonary vascular response to graded inspiratory oxygen tension. *Chest* 1993; 103: 958-960.
47. Melot C, Naeije R, Dechamps P, Hallemans R, Lejeune P. Pulmonary and extrapulmonary contributors to hypoxemia in liver cirrhosis. *Am Rev Respir Dis* 1989; 139: 632-640.
48. Gomez F, Barbera J, Roca J, Burgos F, Gistau C, Rodriguez-Roisin R. Effects of nebulized NG-nitro-L-arginine methyl ester in patients with hepatopulmonary syndrome. *Hepatology* 2006; 43: 1084-1091.
49. Dinh-Xuan AT. Endothelial modulation of pulmonary vascular tone. *Eur Respir J* 1992; 5: 757-762.
50. Rolla G, Brussino L, Colagrande P, et al. Exhaled nitric oxide and oxygenation abnormalities in hepatic cirrhosis. *Hepatology* 1997; 26: 842-847.

51. Rolla G, Brussino L, Colagrande P. Exhaled nitric oxide and impaired oxygenation in cirrhotic patients before and after liver transplantation. *Ann Intern Med* 1998; 129: 375-8.
52. Cremona G, Higenbottam TW, Mayoral V, Alexander G, Demoncheaux E, Borland C, Roe P, Jones GJ. Elevated exhaled nitric oxide in patients with hepatopulmonary syndrome. *Eur Respir J* 1995; 8: 1883-1885.
53. Delclaux C, Mahut B, Zerah-Lancner F, et al. Increased nitric oxide output from alveolar origin during liver cirrhosis versus bronchial source during asthma. *Am J Respir Crit Care Med* 2002; 165: 332-337.
54. Nunes H, Lebrec D, Mazmanian M, et al. Role of nitric oxide in hepatopulmonary syndrome in cirrhotic rats. *Am J Respir Crit Care Med* 2001; 164: 879-885.
55. Zhang J, Ling Y, Luo B, et al. Analysis of pulmonary heme oxygenase-1 and nitric oxide synthase alterations in experimental hepatopulmonary syndrome. *Gastroenterology* 2003; 125: 1441-1451.
56. Rolla G, Bucca C, Brussino L. Methylene blue in the hepatopulmonary syndrome. *N Engl J Med* 1994; 331: 1098.
57. Brussino L, Bucca C, Morello M, Scappaticci E, Mauro M, Rolla G. Effect on dyspnoea and hypoxaemia of inhaled NG-nitro-Larginine methyl ester in hepatopulmonary syndrome. *Lancet* 2003; 362: 43-44.
58. Schenk P, Madl C, Rezale-Majd S, Lehr S, Muller C. Methylene blue improves the hepatopulmonary syndrome. *Ann Int Med* 2000; 133: 701-706.
59. Jia L, Bonaventura J, Stamler JS. S-nitrosohaemoglobin: a dynamic activity of blood involved in vascular control. *Nature* 1996; 380: 221-226.
60. Gow AJ, Luchsinger BP, Pawloski JR, Singel DJ, Stamler JS. The oxyhemoglobin reaction of nitric oxide. *Proc Natl Acad Sci USA* 1999; 96: 9027-9032.
61. Ghittoni G, Valentini G, Spada C, et al. Hepatopulmonary syndrome. A review of the literature: *Panminerva Med* 2003; 45(2): 95-98.
62. Sztymf B, Rabiller A, Nunes H, Savale L, Lebrec D, Le Pape A, de Montpreville V, Mazmanian M, M Humbert, P Hervé. Prevention of hepatopulmonary syndrome and hyperdynamic state by pentoxifylline in cirrhotic rats. *Eur Respir J* 2004; 23: 752-758.
63. Zhang M, Luo B, Chen SJ, Abrams GA, Fallon MB. Endothelin-1 stimulation of endothelial nitric oxide synthase in the pathogenesis of hepatopulmonary syndrome. *Am J Physiol Gastrointest Liver Physiol* 1999; 277: 944-952.
64. Luo B, Liu L, Tang L, et al. Increased pulmonary vascular endothelin B receptor expression and responsiveness to endothelin-1 in cirrhotic and portal hypertensive rats: a potential mechanism in experimental hepatopulmonary syndrome. *J Hepatol* 2003; 38: 556-563.
65. Zhang HY, Han DW, Wang XG, Zhao YC, Zhou X, Zhao HZ. Experimental study on the role of endotoxin in the development of hepatopulmonary syndrome. *World J Gastroenterol* 2005; 11(4): 567-572.
66. Paul L, Steven G. Hemoglobin as a chariot for NO bioactivity. *Nat Med* 2002; 8: 657-658.
67. Arguedas MR, Drake BB, Kapoor A, Fallon MB. Carboxyhemoglobin levels in cirrhotic patients with and without hepatopulmonary syndrome. *Gastroenterology* 2005; 128: 328-333.
68. Rabiller A, Nunes H, Lebrec D, et al. Prevention of gram-negative translocation reduces the severity of hepatopulmonary syndrome. *Am J Respir Crit Care Med* 2002; 166: 514-517.
69. Ward A, Clissold S. Pentoxifylline. A review of its pharmacodynamic and pharmacokinetic properties and its therapeutic efficacy. *Drugs* 1987; 34: 50-97.
70. Krowka MJ, Cortese DA. Hepatopulmonary syndrome. Current concepts in diagnosis and therapeutic considerations. *Chest* 1994; 105: 1528-1537.
71. Rodriguez-Roisin R, Agusti AGN, Roca J. The hepatopulmonary syndrome: new name, old complexities. *Thorax* 1992; 47: 897-902.
72. Krowka MJ, Cortese DA. Hepatopulmonary syndrome: classification by arterial oxygenation and pulmonary angiographic appearance. *Chest* 1992; 102: 124.
73. Ghittoni G, Valentini G, Spada C, et al. Hepatopulmonary syndrome. A review of the literature: *Panminerva Med* 2003; 45(2): 95-98.
74. Gomez F, Martinez-Palli G, Barbera J, Roca J, Navasa M, Rodriguez-Roisin R. Gas exchange mechanism of orthodeoxia in hepatopulmonary syndrome. *Hepatology* 2004; 40: 660-666.
75. Seward JB, Hayes DL, Smith HC, et al. Platypnea-orthodeoxia: clinical profile, diagnostic work-up, management and report of seven cases. *Mayo Clin Proc* 1984; 59: 221.
76. Krowka MJ, Dickson ER, Cortese DA. Hepatopulmonary syndrome. Clinical observations and lack of therapeutic response to somatostatin analogue. *Chest* 1993; 104: 515-521.
77. Martinez GP, Barbera JA, Visa J, Rimola A, Pare JC, Roca J, Navasa M, Rodes J, Rodriguez-Roisin R. Hepatopulmonary syndrome in candidates for liver transplantation. *J Hepatol* 2001; 34: 651-657.
78. Rodriguez-Roisin R, Roca J, Augusti AG, Mastai R, Wagner PD, Bosch J. Gas exchange and pulmonary vascular reactivity in patients with liver cirrhosis. *Am Rev Respir Dis* 1987; 135: 1085.
79. Wang YW, Lin HC, et al. Recent Advances in Hepatopulmonary syndrome. *J Chin Med Assoc* 2005; 68(11): 500-536.
80. Lima B, Martinelli A, Franca AV. Hepatopulmonary syndrome: pathogenesis, diagnosis and treatment *Arq Gastroenterol* 2004; 41(4): 250-258.
81. Abrams GA, Sanders MK, Fallon MB. Utility of pulse oximetry in the detection of arterial hypoxemia in liver transplant candidates. *Liver Transpl* 2002; 8: 391-396.
82. Arguedas M, Abrams GA, Krowka MJ, Fallon MB. Prospective evaluation of outcomes and predictors of mortality in patients with hepatopulmonary syndrome undergoing liver transplantation. *Hepatology* 2003; 37: 192-197.
83. Castro M, Krowka MJ. Hepatopulmonary syndrome. A pulmonary vascular complication of liver disease. *Clin Chest Med* 1996; 17: 35-48.
84. Hind CR, Wong CM. Detection of pulmonary arteriovenous fistulae in patients with cirrhosis by contrast 2D echocardiography. *Gut* 1981; 22: 1042-1045.
85. Shub C, Tajik AJ, Seward JB, Dines DE. Detecting intrapulmonary right-to-left shunt with contrast echocardiography. Observations in a patient with diffuse pulmonary arteriovenous fistulas. *Mayo Clin Proc* 1976; 51: 81-84.
86. Meltzer RS, Tickner EG, Popp RL. Why do the lungs clear ultrasonic contrast? *Ultrasound Med Biol* 1980; 6: 263-269.
87. Vedrinne JM, Duperret S, Bizollon T, Magnin C, Motin J, Treppe C, Ducerf C. Comparison of transesophageal and transthoracic contrast echocardiography for detection of an intrapulmonary shunt in liver disease. *Chest* 1997; 111: 1236-1240.
88. Lima BL, Franca AV, Pazin-Filho A, et al. Frequency, clinical characteristics, and respiratory parameters of hepatopulmonary syndrome. *Mayo Clin Proc* 2004; 79: 42.
89. Krowka MJ, Cortese DA. Pulmonary aspects of liver disease and liver transplantation. *Clin Chest Med* 1989; 10: 593-616.
90. Lee KN, Lee HJ, Shin WW, Webb WR. Hypoxemia and liver cirrhosis (hepatopulmonary syndrome) in eight patients: comparison of the central and peripheral pulmonary vasculature. *Radiology* 1999; 211: 549-553.
91. Katsuta Y, Honma H, Zhang X, Ohsuga M, Komeichi H, Shimizu S, et al. Pulmonary blood transit time and impaired arterial oxygenation in patients with chronic liver disease. *J Gastroenterol* 2005; 40: 57-63.
92. Lange PA, Stoller JK. The hepatopulmonary syndrome: effect of liver transplantation. *Clin Chest Med* 1996; 17: 115-123.
93. Krowka MJ, Porayko MK, Plevak DJ, Pappas SC, Steers JL, Krom RA, Wiesner RH. Hepatopulmonary syndrome with progressive hypoxemia as an indication for liver transplantation: case reports and literature review. *Mayo Clin Proc* 1997; 72: 44-53.

94. Philit F, Wiesendanger T, Gille D, Boillot O, Cordier J. Late resolution of hepatopulmonary syndrome after liver transplantation. *Respiration* 1997; 64: 173-175.
95. Mandell MS, Groves BM, Duke J. Progressive plexogenic pulmonary hypertension following liver transplantation. *Transplantation* 1995; 59: 1488-1490.
96. Abrams GA, Rose K, Fallon MB, et al. Hepatopulmonary syndrome and venous emboli causing intracerebral hemorrhages after liver transplantation: a case report. *Transplantation* 1999; 68: 1-3.
97. Scott V, Mira A, Kang Y, et al. Reversibility of the hepatopulmonary syndrome by orthotopic liver transplantation. *Transplant Proc* 1993; 25: 1787-1788.
98. Meyers C, Low L, Kaufman L, Druger G, Wong LL. Trendelenburg positioning and continuous lateral rotation improve oxygenation in hepatopulmonary syndrome after liver transplantation. *Liver Transpl Surg* 1998; 6: 510-512.
99. Durand P, Baujard C, Grosse AL, Gomola A, Debray D, Dousset B, Devictor D. Reversal of hypoxemia by inhaled nitric oxide in children with severe hepatopulmonary syndrome, type 1, during and after liver transplantation. *Transplantation* 1998; 65: 437-439.
100. Henrion J, Schapira M, Luwaert R, Colin L, Delannoy A, Heller FR. Hypoxic hepatitis: clinical and hemodynamic study in 142 consecutive cases. *Medicine (Baltimore)* 2003; 82: 392-406.
101. Abrams GA, Fallon MB. Treatment of hepatopulmonary syndrome with *Allium sativum* (garlic): a pilot trial. *J Clin Gastroenterol* 1998; 27: 232-235.
102. Song JY, Choi JY, Ko JT, Bae EJ, Kim HS, Noh CI. Long-term aspirin therapy for hepatopulmonary syndrome. *Pediatrics* 1996; 97: 917-920.
103. Caldwell SH, Jeffers LJ, Narula OS, Lang LA, Ready KR, Schiff R. Ancient remedies revisited: does *Allium sativum* (garlic) palliate the hepatopulmonary syndrome? *J Clin Gastroenterol* 1992; 15: 248-250.
104. Anel RM, Sheagren JN. Novel presentation and approach to management of hepatopulmonary syndrome with use of antimicrobial agents. *Clin Infect Dis* 2001; 32: E131-E136.