

Autoimmune hepatitis with giant-cell transformation

José Estradas;¹ Virginia Pascual-Ramos;² Braulio Martínez;³ Misael Uribe;¹ Aldo Torre¹

Abstract

Background/Aims: Giant-cell hepatitis (GCH), also known as postinfantile or syncytial giant cell hepatitis, is a frequent pattern of liver injury in the neonate, primarily seen in the first three months of life. Few cases in adults have been reported, some of them associated to autoimmune diseases such as autoimmune hepatitis. **Methods:** We present a case of autoimmune hepatitis with giant cell transformation in a 39 year old male with polyarthritis. We discuss his clinical presentation and course. We made a review of the literature of agents associated to this diagnosis, the mechanisms involved in the formation of giant hepatocytes, the histological findings, clinical course, treatment options and prognosis of this rare entity. **Results and conclusions:** In conclusion, the clinical course varies from normalization of hepatic histology to progression to cirrhosis and liver failure. The prognosis is dictated by the underlying liver disease and in the setting of autoimmune hepatitis the clinical course is usually severe with most of the patients progressing to cirrhosis. Prolonged treatment with corticosteroids and immunosuppressants is usually effective in rendering the cirrhosis inactive.

Key words: Autoimmune hepatitis, giant-cell hepatitis, postinfantile giant cell hepatitis, syncytial giant cell hepatitis.

Case report

Giant-cell hepatitis (GCH), also known as postinfantile or syncytial giant cell hepatitis, is a frequent pattern of liver injury in the neonate, primarily seen in the first three months of life. Few cases in adults have been reported, some of them associated to autoimmune diseases such as autoimmune hepatitis.

We herein present a case of autoimmune hepatitis with giant cell transformation in a 39 year old male with polyarthritis involving the shoulders, elbows, wrists, metacarpophalangeal and proximal interphalangeal joints, knees, ankles and metatarsophalangeal joints. He had a 5 month history of asthenia, weight loss (20 kg), dry cough and morning stiffness. He admitted taking non-steroidal anti-inflammatory drugs (NSAIDs) for pain relief.

On physical examination the patient was found cachectic with arthritis of the mentioned joints. Neither hepatomegaly nor tenderness on the right upper quadrant was found on palpation.

Laboratory studies showed WBC 18.8 K/ μ L, hemoglobin 12.1 g/dL, platelets 611 K/ μ L, ALT 74 U/L, AST 59 U/L, GGT 158 U/L, bilirubins were within normal limits, alkaline phosphatase was of 226 U/L, albumin 2.76 g/dL, and globulines of 3.94.

The rheumatoid factor (nephelometry) was slightly positive: 40.51 UI/mL, anti-cyclic citrullinated peptide autoantibody (2nd generation ELISA) and antinuclear antibodies (immunofluorescence) were both negative, anti-neutrophil cytoplasmic autoantibodies (ANCA) (immunofluorescence) showed a c-ANCA pattern in a tittle of 1:320 with negative myeloperoxidase and proteinase-3 (ELISA). Serum levels of complement were decreased (C3 59.5 mg/dL, C4 9.0 mg/dL), the viral profile was negative.

The chest X ray showed an apparent widening of the mediastinum, a chest CT was performed and showed a nodular lesion with central necrosis in the anterior mediastinum and mediastinal adenomegalies. The mediastinal mass was found to be an atypical thymoma type B3 (World Health Organization Classification) after the surgical excision and pathological examination were performed, radiotherapy was indicated afterwards.

He was started on chloroquine, sulfasalazine and prednisone which relieved the rheumatologic symptoms, but after 6 months of treatment he became jaundiced and had

¹ Department of Gastroenterology.

² Department of Rheumatology and Immunology.

³ Department of Pathology.

Instituto Nacional de Ciencias Médicas y Nutrición Salvador Zubirán

Address for correspondence:

Aldo Torre, MD. M.Sc.

Instituto Nacional de Ciencias Médicas y Nutrición Salvador Zubirán

Vasco de Quiroga 15, Section XVI, Tlalpan, Mexico City

Telephone: +55 5573 3418

Fax: +55 5655 0942

E-mail: detoal@yahoo.com

Manuscript received and accepted:

10 September and 27 November, 2008

a progressive increment of bilirrubins (total bilirubins 11.2 mg/dL, direct bilirubins 6.4 mg/dL) and transaminases (ALT: 523 U/L, AST: 187 U/L) Serum globulines were within normal range and anti-mitochondrial antibodies were negative. Drug toxicity, biliary tract disease and infectious causes were excluded.

A liver biopsy was performed and showed interface hepatitis with mild portal and periportal lymphoplasmacytic inflammation, hepatocyte swelling and necrosis (*Figure 1*). Giant multinucleated hepatocytes were present in more than 50% of the biopsy, predominantly in periportal area (*Figure 2*); other histological findings were mild lobular inflammation, necrosis and mild inter-laminar fibrosis. The diagnosis of autoimmune hepatitis with giant cell transformation was concluded.

The final «Autoimmune Hepatitis Score» for the diagnosis of autoimmune hepatitis was: 20.¹

He was started on prednisone 40 mg and azathioprine 100 mg daily, he has been attending our clinic for regular check-ups and his clinical and biochemical profile have markedly improved after one year of treatment.

Giant cell hepatitis (GCH) is an infrequent presentation of liver injury in the adulthood. It is more commonly described in neonates as a response of immature hepatocytes to a variety of insults such as cholestasis,^{2,4} and when it occurs in adults, it is known as postinfantile giant cell hepatitis.^{2,4,5}

Agents that have been associated to this diagnosis include: infections such as hepatitis A, B and C viruses,⁶ HIV, EBV, and paramyxovirus;⁷ drugs as methotrexate, 6-mercaptopurine, p-aminosalicylic acid, chlorpromazine, vinyl chloride, clomethacin,² and a case of GCH after a human herpesvirus 6-induced adverse drug reaction has also been described;⁸ diseases like sickle cell anemia, autoimmune hemolytic anemia, chronic lymphocytic leu-

kaemia,⁹ non-Hodgkin's lymphoma involving the liver,⁴ polyarteritis nodosa,¹⁰ autoimmune hepatitis (type I and II^{5,11}), ulcerative colitis (suggesting that GCH may be included in the list of hepatic complications of inflammatory bowel disease),^{2,12} primary biliary cirrhosis¹³ and primary sclerosing cholangitis;³ congenital metabolic diseases such as alpha 1-antitrypsin deficiency or haemosiderosis, and in some other cases the etiology remains unclear.

Giant-cell transformation is a nonspecific reaction to various stimuli rather than a specific disease process.^{4,14} There are two possible mechanisms in the formation of giant hepatocytes: the fusion of individual cells to form a syncytium (therefore the used term «syncytial giant cell hepatitis»¹⁵) and the failure of the cytoplasm to divide at the time of nuclear division.^{4,5,14}

The diagnosis is made when multinucleated syncytial hepatocytes are observed in liver biopsy,³ they may be seen as isolated clusters of giant cells or multinucleated giant cells over mononuclear hepatocytes, appearing predominantly in zone 3 or 1 of the Rappaport acinus. Other histological findings include portal inflammation (more commonly lymphocytic, but plasma cells and neutrophils can also be seen), varying degrees of acinar inflammation, hepatocellular necrosis, ballooning degeneration, bile duct lesions (nonsuppurative destructive cholangitis, periductal scarring, and ductopenia), periportal fibrosis and cirrhosis.⁴

The clinical course may vary from normalization of hepatic histology, either spontaneously or by medical treatment, to progression to cirrhosis and liver failure.^{2,3} The prognosis is dictated by the underlying liver disease^{2,16} and in the setting of autoimmune hepatitis the clinical course is usually severe with most of the patients progressing to cirrhosis. Prolonged treatment with corticosteroids and immunosuppressants is usually effective

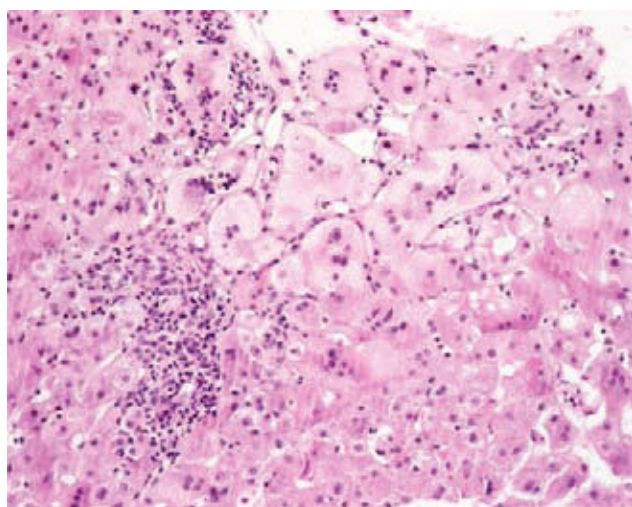


Figure 1. Microscopic view of the liver biopsy showing interface hepatitis with mild portal and periportal lymphoplasmacytic inflammation, hepatocytes swelling and necrosis.

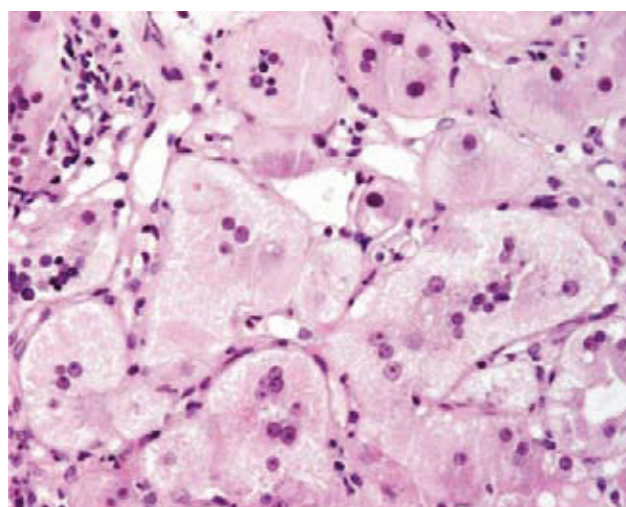


Figure 2. Giant multinucleated hepatocytes in more than 50% of the biopsy, predominantly in periportal area.

in rendering the cirrhosis inactive.⁵ A reduction in the number of giant hepatocytes after treatment of the autoimmune and cholestatic features has been reported previously, which may suggest that an autoimmune mechanism as well as cholestasis may be involved in the pathogenesis of giant cell transformation.^{2,3,5,17,18}

Most of the patients with GCH have an unfavorable prognosis, with a rapidly progressive course leading to death or the need for orthotopic liver transplantation, although GCH can recur in liver allograft.^{19,20}

References

1. Alvarez F, Berg PA, Bianchi FB, Bianchi L, Burroughs AK, Cancado EL, et al. International Autoimmune Hepatitis Group Report: review of criteria for diagnosis of autoimmune hepatitis. *J Hepatol* 1999; 31: 929-38.
2. Labowitz J, Finklestein S, Rabinovitz M. Postinfantile giant cell hepatitis complicating ulcerative colitis: a case report and review of the literature. *Am J Gastroenterol* 2001; 96: 1274-7.
3. Protzer U, Dienes HP, Bianchi L, Lohse AW, Helmreich-Becker I, Gerken G, Meyer zum Buschenfelde KH. Post-infantile giant cell hepatitis in patients with primary sclerosing cholangitis and autoimmune hepatitis. *Liver* 1996; 16: 274-82.
4. Devaney K, Goodman ZD, Ishak KG. Postinfantile giant-cell transformation in hepatitis. *Hepatology* 1992; 16: 327-33.
5. Ben-Ari Z, Broida E, Monseliese Y, Kazatsker A, Baruch J, Pappo O, et al. Syncytial giant-cell hepatitis due to autoimmune hepatitis type II (LKM1+) presenting as subfulminant hepatitis. *Am J Gastroenterol* 2000; 95: 799-801.
6. Kryczka W, Walewska-Zielecka B, Dutkiewicz E. Acute seronegative hepatitis C manifesting itself as adult giant cell hepatitis – a case report and review of literature. *Med Sci Monit* 2003; 9 Suppl 3: 29-31.
7. Philips MJ, Blendis LM, Poucell S, offterson J, Petric M, Roberts E, et al. Syncytial giant-cell hepatitis. Sporadic hepatitis with distinctive pathological features, a severe clinical course, and paramyxomal features. *N Eng J Med* 1991; 324: 455-60.
8. Kuntzen T, Friedrichs N, Fischer HP, Eis-Hübinger AM, Sauerbruch T, Spengler U. Postinfantile giant cell hepatitis with autoimmune features following a human herpesvirus 6-induced adverse reaction. *Eur J Gastroenterol Hepatol* 2005; 17: 1131-4.
9. Alexopoulou A, Deutsch M, Ageletopoulou J, Delladetsima JK, Marinos E, Kapranos N, et al. A fatal case of postinfantile giant cell hepatitis with chronic lymphocytic leukaemia. *Eur J Gastroenterol Hepatol* 2003; 15: 551-5.
10. Koskinas J, Deutsch M, Papaioannou C, Kafiri G, Hadzivannis S. Post-infantile giant cell hepatitis associated with autoimmune hepatitis and polyarteritis nodosa. *Scand J Gastroenterol* 2002; 37: 120-3.
11. Scheuer PJ, Lefkowitz JH. *Chronic hepatitis*. In: WB Saunders, eds. *Liver Biopsy Interpretation*. 6th ed. London, 2000: 164-166.
12. Anagnostopoulos GK, Margantinis G, Tsiakos S, Kostopoulos P, Grigoriadis K, Arvantidis D. Postinfantile giant-cell hepatitis associated with ulcerative colitis and autoimmune hepatitis. *J Gastroenterol Hepatol* 2006; 21: 1863-4.
13. Watanabe N, Takashimizu S, Shiraishi K, Kagawa T, Nishizaki Y, Mine T, et al. Primary biliary cirrhosis with multinucleated hepatocellular giant cells: implications for pathogenesis of primary biliary cirrhosis. *Eur J Gastroenterol Hepatol* 2006; 18: 1023-7.
14. Lau JY, Koukoulis G, Mieli-Vergani G, Portmann BC, Williams R. Syncytial giant-cell hepatitis - a specific disease entity? *J Hepatol* 1992; 15: 216-19.
15. Thaler H. Post-infantile giant cell hepatitis. *Liver* 1982; 2: 393-403.
16. Tordjmann T, Grimbert S, Genestie C, Freymuth F, Guettier C, Callard P, et al. [Adult multi-nuclear hepatitis. A study in 17 patients]. *Gastroenterol Clin Biol* 1998; 22: 305-10.
17. Pittau S, Morelli S, Venturini E, Boldorini R, Sartoi M. [Post-infantile giant cell hepatitis. Clinical and histological response to immunosuppressive therapy]. *Recenti Prog Med* 1998; 89: 126-9.
18. Eroglu Y, Düzovali O, Kavucku S, Irken G, Büyükgebiz B. Combination of steroid with azathioprine in treatment of giant cell autoimmune hepatitis. *Turk J Pediatr* 1997; 39: 565-71.
19. Pappo O, Yunis E, Jordan JA, Jaffe R, Mateo R, Fung J, et al. Recurrent and de novo giant cell hepatitis after orthotopic liver transplantation. *Am Surg Pathol* 1994; 18: 804-13.
20. Shah JA, Steinbrecher UP, Erb SR, Tha SP, Yoshida EM. Recurrent giant cell hepatitis in an 18 year old liver transplant patient. *Ann Hepatol* 2008; 7: 257.