

# Improvement of hepatic fibrosis by leukotriene inhibition in cholestatic rats

Sahar EL-Swefy;<sup>1</sup> Samia I. Hassanen<sup>2</sup>

## Abstract

**Chronic liver disease is characterized by inflammation and fibrosis. Angiogenesis which leading to new vasculature may have prognostic value in disease progression. This study examined the implication of 5-lipoxygenase pathway and angiogenic factors in hepatic fibrosis progression and whether, the inhibition of arachidonic acid cascade product (cysteinyl leukotrienes) can represent a potential target for therapy. Cholestasis and subsequent fibrosis was induced by common bile duct ligation and resection (BDL) for 5 weeks in rats. After surgery, Cysteinyl leukotrienes antagonist (montelukast) was orally and daily administered (10 mg/kg) for 34 days. Sham operated and drug control groups received either saline or montelukast immediately after operation. BDL significantly increased liver hydroxyproline (Hp), nuclear factor kappa B (NF- $\kappa$ B), transforming growth factor beta (TGF- $\beta$ ), tissue inhibitor metalloproteinase (TIMP-1), vascular endothelial growth factor (VEGF), and reduced the level of matrix metalloproteinase 9 (MMP-9). On the other hand, montelukast treatment reversed all these biochemical parameters and ameliorated histopathological changes which previously induced by BDL. Findings of the present study suggest that montelukast treatment may favor collagenolytic activity through modulating hepatic expression of TGF- $\beta$ , NF- $\kappa$ B, and MMP-9/TIMP-1 ratio. Amelioration of necroinflammatory liver injury and fibrogenesis may support such assumption.**

**Key words:** Hepatic fibrosis, inflammation, angiogenesis, leukotrienes antagonist, rats.

## Introduction

Liver fibrosis is a major feature of many chronic liver injuries including metabolic, viral, cholestatic and genetic disease.<sup>1</sup> Chronic cholestatic liver diseases are characterized by defective bile acid transport from the liver to intestine caused by primary damage to the biliary epithelium.<sup>2</sup> Fibrosis and subsequently cirrhosis are causal factors leading to morbidity and mortality related to liver disease.<sup>3</sup> Collective evidences indicated that liver fibrosis incorporates uncontrolled inflammation as a part of its etiology. Kupffer cells, which act as resident macrophages in the body represent the primary inflammatory effectors which initiate the inflammatory cascade leading to tissue remodeling and fibrosis.<sup>4</sup> As a result, such cascade leads to activation of hepatic stellate cells (HSCs) and initiation of unbalanced synthesis of collagen, proteoglycan and hyaluronate.<sup>5</sup> Enhanced matrix synthesis and diminished breakdown of connective tissue proteins may lead to increased deposition of extracellular matrix and subsequent hepatic fibrosis.<sup>6</sup> Matrix metalloproteinases (MMPs) are zinc dependent endopeptidases that catalyze the degradation of extracellular matrix proteins, thereby controlling physiological processes (tissue remodeling and wound healing) as well as pathological ones (liver fibrosis). Activity of MMPs is controlled by regulation of expression and secretion through proteolytic activation of proenzymes and the tissue inhibitors of metalloproteinases (TIMPs).<sup>7</sup> Transcription of TIMP-1 is induced by pro-inflammatory cytokines and transforming growth factor beta (TGF $\beta_1$ ).<sup>8</sup> An improper balance between MMPs and TIMP production is expressed as an important determinant of extracellular matrix deposition and breakdown.

Vascular endothelial growth factor (VEGF), an endothelial cell-specific mitogenic peptide is synthesized mainly due to hypoxia, endothelial cell damage, and tissue ischemia. It has a key role in vasculogenesis and angiogenesis.<sup>9</sup> VEGF also increases vascular permeability, in turn leakage of plasma proteins into the extra vascular space leading to edema and profound alterations in the extracellular matrix.<sup>10</sup> A wealth of evidence indicated that intrahepatic in-

<sup>1</sup> Biochemistry Dept., Faculty of Pharmacy, Zagazig University.

<sup>2</sup> Agricultural Research Center, Egypt.

Address for correspondence:  
Dr. Sahar EL-Swefy  
E-mail: saharelswefy@yahoo.com

Manuscript received and accepted:  
25 August and 25 October 2008

flammatory process, angiogenesis and up-regulation of vascular endothelial growth factor (VEGF) may play a central role in the current paradigm of liver fibrosis.<sup>11</sup> Therefore anti-inflammatory strategies are one of the proposed therapeutic approaches to hepatic fibrosis.

Leukotrienes, as products of 5-lipoxygenase (5LO) pathway can increase microvascular permeability and acting as potent chemotactic agents. Cysteinyl leukotrienes (CysLT), namely leukotrienes C4, D4, and E4 (LTC4, LTD4, LTE4) are secreted mainly by eosinophils, mast cells, monocytes and macrophages. They exert variety of actions which emphasize their importance as pathogenic elements in inflammatory states.<sup>12</sup> Role of leukotrienes as mediators of the gastric damage induced by ethanol or other noxious substances was reported before.<sup>13</sup> Recent evidences indicated that 5-LO pathway has converging functions in liver inflammation, tissue remodeling, and fibrosis.<sup>14,15</sup>

Present study aimed to examine firstly the relative contribution of 5LO and CysLT as pro-inflammatory and angiogenic pathways in relation to hepatic inflammation and fibrosis progression. Secondly study the effect of leukotrienes inhibition through CysLT receptor antagonist (montelukast) on hepatic fibrosis induced experimentally by bile duct ligated and resected (BDL) technique in rats.

## Materials and methods

### Experimental animals

Adult male albino rats (220-250 g) were supplied by Egyptian Organization for Biological Products and Vaccine (Helwan, Egypt). Rats were housed in stainless steel cages at constant temperature of  $25 \pm 2^\circ\text{C}$ , relative humidity of approximately 50%, illumination (12 h light/dark) and had free access to standard pellet chow and water ad libitum. All experiments were carried out in accordance with protocols approved by the local experimental ethics committee.

### Surgery and experimental design

Cholestasis was induced according to Yang et al.<sup>17</sup> The common bile duct was doubly ligated at the hilum of the liver with 4-0 silk and transected between the two ligations (bile duct ligated and resected group, BDL). In the sham-operated rats, abdominal incision was made without ligation or transection of the bile duct. Four groups of rats were used. The animals of the first group (n = 10) were sham operated and saline treated for 34 days (Sham-operated control). Second group (n = 10) was sham operated and treated with oral CysLT receptor antagonist, montelukast (Merk Sharp and Dome, USA) suspended in saline using gum acacia

(10 mg/kg/day)<sup>18</sup> (Drug control). Third group (n = 15) was BDL. The last one (n = 15) was BDL and treated with montelukast orally and daily for 34 days on the second day of surgery. At the end of 5 weeks, all animals from each group were anaesthetized with urethane (1.3 mg/kg) and blood samples were collected, subjected to serum separation and divided into aliquots. Fresh sera were tested for liver enzymes and other aliquots were stored at  $-20^\circ\text{C}$  for later biochemical analysis. Rats were then killed by decapitation; the livers were collected. The wet livers were weighed and samples from each rat were excised carefully and processed for paraffin section preparation and directed for histological examinations. The remaining livers were frozen in liquid nitrogen and subjected to biochemical assessment.

### Liver index calculation

Liver index was calculated according to the formula of Yang et al.<sup>19</sup> (liver weight/body weight)  $\times$  100.

### Liver function tests and membrane oxidation

Alanine aminotransferase (ALT),<sup>20</sup> alkaline phosphatase (ALP)<sup>21</sup> total bilirubin (TB) and direct bilirubin (DB)<sup>22</sup> were determined spectrophotometrically using commercial kits (Spinreact, Spain) lipid peroxide measured as malondialdehyde (MDA) were estimated as previously described.<sup>23</sup>

### Liver TGF $\beta_1$

0.25 gm of liver tissue was homogenized in 1mL lysis buffer for protein extraction which contained 0.0625 mol/L tris buffer (pH 6.8), 2% sodium dodecyl sulphate (SDS), 3% beta mercaptoethanol, 10% glycerol, 100 mmol/L sodium fluoride, 10  $\mu\text{g/mL}$  aprotinin and 1 mmol/L phenylmethylsulfonyl fluoride (Sigma, USA). Liver tissues were homogenized using a tissue homogenizer. After cell lysis the homogenate was centrifuged at  $10,000 \times g$  for 20 minutes at  $4^\circ\text{C}$  and the supernatant was examined for TGF $\beta_1$  using quantitative sandwich enzyme linked immunoassay using kits supplied from R&D Systems (Europe, Ltd. United Kingdom). We followed the instruction of the manufacturer.<sup>24</sup>

### Collagen content

Acid hydrolysis of collagen liberated hydroxyproline (Hp) and was followed by oxidation with chloramine T. Reaction of oxidation product with p-dimethylaminobenzaldehyde results in formation of colored complex measured in ELISA plate reader at 550 nm. Concentrations of Hp were calculated from plotted standard curve using Hp solution (0-200  $\mu\text{g/mL}$ ).<sup>25</sup>

### Detection of NF- $\kappa$ B, MMP-9, TIMP-1, and VEGF gene expression by Reverse transcription-polymerase chain reaction (RT-PCR):

#### RNA extraction

Total RNA was extracted from liver tissue by the acid guanidinium thiocyanate-phenol-chloroform method<sup>26</sup> RNA content and purity were measured by a UV spectrophotometer. The A260/A280 ratio should be 1.8 to 2.0. The RNA was detected by agarose gel electrophoresis.

#### RT-PCR experiments

RT-PCR was done using the extracted RNA for detection of NF- $\kappa$ B, MMP-9, TIMP-1, and VEGF genes.  $\beta$ -actin expression level was determined as loading control for each sample. For amplification of the target genes, reverse transcription and PCR were run in two separate steps. Briefly, equal amounts of total RNA (6  $\mu$ g) were denatured thermally and reverse transcribed by incubation at 42°C for 90 min with 12.5 U avian myeloblastosis virus reverse transcriptase (AMV) (Promega Corp., Madison, WI), 20 U ribonuclease inhibitor RNasin (Promega Corp.), 200 nM deoxy-nucleoside 5'-triphosphate mixture, and 1 nM oligo-dT primer in a final volume of 30  $\mu$ L of 1x AMV reverse transcriptase buffer. The reactions were terminated by heating at 97°C for 5 min and cooling on ice. The cDNA samples were amplified in 50  $\mu$ L of 1x PCR buffer in the presence of 2.5 U Taq DNA polymerase (Promega Corp.), 200 nM deoxy-nucleoside 5'-triphosphate mixture, and the appropriate primer pairs (1 nM of each primer). These sets of primers, annealing temperature and product size in *Table I*. PCR consisted in a first denaturing cycle at 97°C for 5 min, followed by a variable number of cycles of amplification defined by denaturation at 96°C for 1.5 min, annealing for 1.5 min, and extension at 72°C for 3 min. A final extension cycle of 72°C for 15 min was included.<sup>27</sup>

### Agarose gel electrophoresis

All PCR products were run on 2% agarose stained with ethidium bromide and visualized by UV transilluminator.

#### Semi-quantitative determination of PCR products

Semi-quantitation was performed using the gel documentation system (BioDO, Analyser) supplied by Biometra. according to the following amplification procedure. Relative expression of each studied gene (R) was calculated following the formula: R = Densitometrical Units of each studied gene/Densitometrical Units of  $\beta$ -actin.

#### Histopathological analysis

For light microscopic investigations, specimens from liver were fixed in 10% phosphate buffer formalin, dehydrated in alcohols and embedded in paraffin. Five micron tissue sections were stained with hematoxylin and eosin stain (H&E) for general histopathological examination<sup>28</sup> and Masson's trichrome stain for the determination of fibrosis.<sup>29</sup> Scoring of Histopathological changes were done as follow: (-) absent; (+) mild; (++) moderate; (+++) severe, (++++ extremely severe.

#### Statistical analysis

Results were expressed as means  $\pm$  S.D. Statistical evaluation was done using one-way analysis of variance (ANOVA) according to Snedecor and Cochran<sup>30</sup> and Tukey's multiple comparison test. Values of  $P < 0.05$  were considered significant.

### Results

#### Liver index, liver function and membrane oxidation

*Table II* shows that bile duct ligation and resection induced significant increase in liver index, TB and DB as

**Table I.** The oligonucleotide primers sequence of studied genes.

Item	Primer sequence	Annealing temp	Product size
MMP-9	Forward-primer: 5'CGGAGCACGGGGACGGGTATC-3' Reverse-primer: 5'-AAGACGAAGGGGAAGACGCACATC-3'.	65°C	541bp
TIMP-1	Forward-primer: 5'TCTGGCATCCTCTTGTGTGCT-3' Reverse-primer: 5'CACAGCCAGCACTATAGGTCTTT-3'.	55°C	418 bp
NF- $\kappa$ B	Forward-primer: 5'TACCATGCTGTTGGTTCA-3'. Reverse-primer:5'-TCAAGCTACCAATGACTTTC-3'.	65°C	208 bp
VEGF	Forwardprimer: 5'GCCCTGGAGTGCGTGCCACGTC-3' Reverse-primer: 5'-TGGCGATTTAGCAGCAGATA—3'.3'.	60°C	166 bp
$\beta$ -actin "house-keeping" gene	Forward-primer: 5-TGTTGTCCCTGTATGCCTCT-3 Reverse-primer: 5-TAATGTCACGCACGATTTCC-3	57°C	206 bp

well as the enzyme activities of ALT and ALP as compared to sham-operated control rats treated with either saline or montelukast ( $p < 0.05$ ). The MDA levels measured as a major degradation product of lipid peroxidation in liver tissues, were found to be significantly higher in BDL rats (124, 144%) as compared to those of the sham and drug control groups respectively. Cysteinyl leukotrienes antagonist administration for 34 days significantly reduced liver index (25%), the levels of hepatic function markers (36%) and MDA content (41%). However, it had no effect on bilirubin levels.

### Hepatic fibrotic markers

Table III shows that hepatic fibrosis was evident in BDL rats as indicated by 2.8 and 3.4 folds increase in liver content of  $TGF\beta_1$  and collagen (expressed as Hp) respectively compared to sham-operated control. Montelukast treatment dramatically reduced the previous indexes.

### RT PCR determination of NF- $\kappa$ B, MMP-9, TIMP-1 and VEGF

Liver from sham-operated control rats treated with either saline or montelukast expressed low levels of NF- $\kappa$ B, TIMP-1 and VEGF mRNA transcripts, whereas these parameters were significantly increased in BDL control group. However, the expression of MMP-9 mRNA transcript was higher in sham-operated and drug controls, it was dramatically reduced in BDL group. Montelukast therapy greatly reduced levels of NF- $\kappa$ B, TIMP-1 and VEGF mRNA transcripts and remarkably increased expression of MMP-9 (Figure 1). It also induced 3.4 folds

increase in MMP-9 / TIMP-1 ratio as compared to BDL group (Figure 2).

### Liver histopathological examination

Liver sections from the sham-operated control group rats showed normal hepatocytes, sinusoids and no fibrosis (Figures 3A & 3f). Sham-operated rats treated with montelukast showed mild edema, congestion and nearly normal hepatic cells architecture (Figures 3B & 3G). After BDL, liver of rats revealed extremely severe inflammation, necrosis, fibrosis and ductular proliferation. In addition, an important cellular migration around the portal triad and the central vein (CV) was observed and associated with the relocation of the Kupffer cells (Figures 3C & D). Prolonged biliary obstruction was joined with marked increase in collagen deposition around the portal triad and CV. This was evidenced by the Masson's trichrome stain that tinges the fibers of the collagen blue. Normal hepatic architecture was also lost, extended necrotic areas and moderate edema were frequently observed with marked ductular proliferation (Figures 3H & I) as compared to sham-operated control group. Montelukast treatment significantly changed the profile of collagen fiber deposition in BDL rats. Mild congestion, edema and few bile duct proliferations and degeneration were demonstrated as compared to BDL control. Moderate periportal fibrosis and focal necrosis were also observed (Figures 3E & J). Histopathological changes in liver tissue in the tested groups are illustrated in Table IV.

### Discussion

Human chronic liver diseases are often characterized by moderate inflammation and necrosis in spite of pro-

**Table II.** Effects of bile duct ligation and montelukast on liver index, cholestasis (serum total and direct bilirubin), liver damage markers (serum ALT and ALP activities) and membrane oxidation (liver MDA).

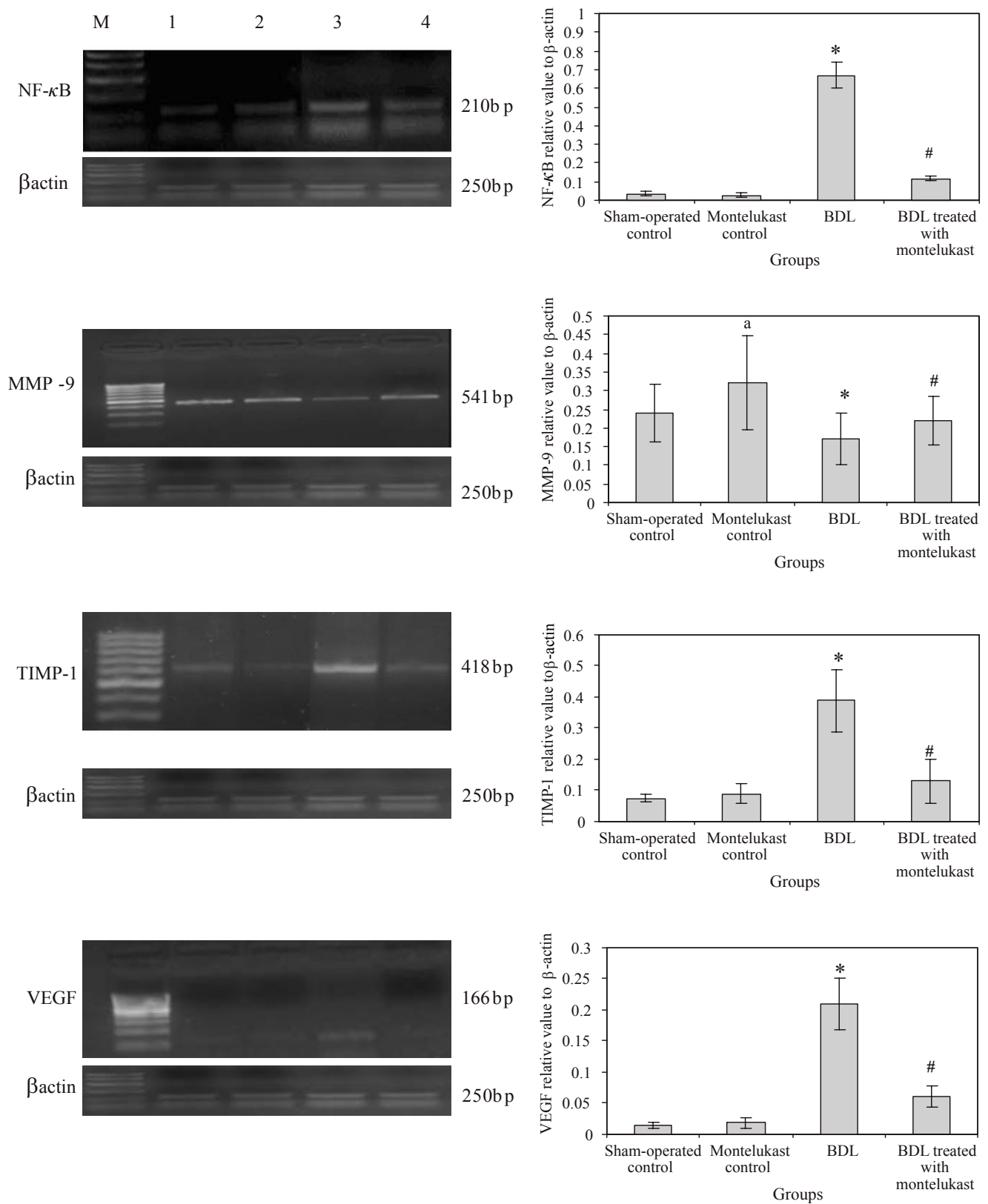
Parameters	Sham-operated control	Montelukast control	BDL	BDL treated with montelukast
Liver index (%)	3.46 $\pm$ 0.53	3.25 $\pm$ 0.43	5.56 $\pm$ 0.71*	4.20 $\pm$ 0.6 <sup>#</sup>
TB (mg/dL)	0.88 $\pm$ 0.12	0.95 $\pm$ 0.14	10.42 $\pm$ 1.6*	9.5 $\pm$ 1.8
DB (mg/dL)	0.37 $\pm$ 0.071	0.41 $\pm$ 0.088	8.56 $\pm$ 2*	7.8 $\pm$ 1.5
ALT (u/L)	17.5 $\pm$ 2.5	14.6 $\pm$ 2.06 <sup>a</sup>	44 $\pm$ 7.11*	28.1 $\pm$ 4.36 <sup>#</sup>
ALP (U/L)	40.8 $\pm$ 6	31 $\pm$ 7 <sup>a</sup>	115 $\pm$ 16*	72 $\pm$ 9 <sup>#</sup>
MDA (nmol/g)	155 $\pm$ 25	142.6 $\pm$ 22 <sup>a</sup>	347 $\pm$ 45*	206 $\pm$ 21 <sup>#</sup>

Values are mean  $\pm$  SD of eight observations, \* $p < 0.001$  vs sham-operated control and montelukast control, <sup>a</sup> $p < 0.01$  vs BDL group, <sup>#</sup> $p < 0.05$  vs sham-operated control.

**Table III.** Hepatic fibrotic markers in BDL rats and following treatment with leukotriene antagonist montelukast.

Parameters	Sham-operated control	Montelukast control	BDL	BDL treated with montelukast
$TGF\beta_1$ (pg/mg protein)	108 $\pm$ 14	116 $\pm$ 17	300 $\pm$ 56*	185 $\pm$ 23 <sup>#</sup>
Hp (mg/g tissue)	118 $\pm$ 16	125 $\pm$ 16	406 $\pm$ 92*	191 $\pm$ 29 <sup>#</sup>

Values are mean  $\pm$  SD of eight observations, \* $p < 0.001$  vs sham-operated control and montelukast control, <sup>#</sup> $p < 0.01$  vs BDL group.



**Figure 1.** mRNA expression levels of hepatic NF-κB, MMP-9, TIMP-1, VEGF, control gene (β-actin) in all rats (n=6 /group). Left panels representative RT-PCR in which Lane M: 100 bp DNA marker, Lane 1, 2, 3 and 4 are representative for sham operated control, montelukast control, BDL and BDL treated with montelukast groups respectively. Right panels illustrate the relative levels of mRNA of hepatic NF-κB, MMP-9, TIMP-1, VEGF to β-actin using RT-PCR. Values are mean ± SD of six observations \*p < 0.001 vs sham- operated control and montelukast control, #p < 0.01 vs BDL group.

gression to cirrhosis. The pathogenesis of liver injury during extrahepatic cholestasis induced by bile duct obstruction is poorly understood. Liver dysfunction and cell injury may be contributed.<sup>31</sup> In this study, serum levels of liver enzymes (ALT, ALP) and bilirubin were significantly higher in BDL rats than in sham-operated rats. Nishimura et al<sup>32</sup> referred to bilirubin as the major harmful factor of harm on the hepatic function during biliary obstruction, but currently the detergent action of bile salt has been emphasized.<sup>33</sup> Accumulation of bile salts in the tissue solubilizes membrane phospholipids which in turn can trigger the development of various pathological conditions mediated by cytokines including necrosis and fibrosis.<sup>34</sup> The results of the present study indicated that exacerbation of oxidative injury in liver of BDL rats was more than sham and drug control groups as evidenced by MDA levels. Accordingly, oxidative stress and free radical production may be an important mechanism of cholestatic liver injury.<sup>35</sup>

Fibrosis is an inherent process in liver cirrhosis where cytokines (TGF- $\beta$ , IL-1 $\beta$ ) are involved in triggering and activating of stellate cells (HSCs) to produce collagen.<sup>36</sup> Fibrosis was present in BDL rats and it was assessed by two techniques, quantification of collagen and histology with Masson's trichrome stain. This study demonstrated that BDL induced fibrosis in rats correlated with an increment of TGF- $\beta$  (important cytokine marker involved in fibrosis) and Hp content of liver tissue. Nuclear factor kappa B (NF- $\kappa$ B) is a nuclear transcriptional activator which plays a central role in the stress response and inflammation.<sup>37</sup> It also plays an important role in liver fibrosis by regulating the expression of inflammatory response genes and inhibiting apoptosis of HSCs.<sup>38</sup> This study reported also increased expression of NF- $\kappa$ B in liver tissue was joined with remarkable increase of liver MDA and TGF- $\beta$  contents.

Up on liver injury, it is generally accepted that the HSCs play major roles in lesions progression and secre-

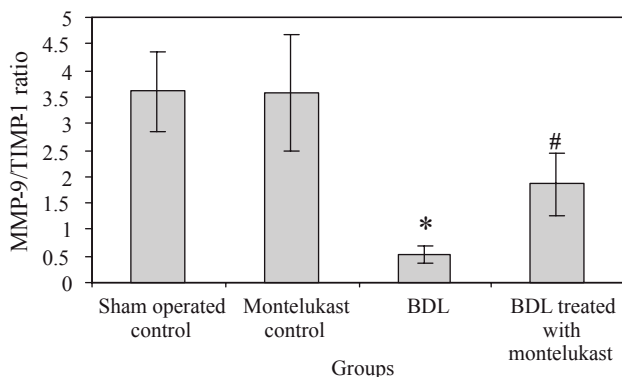
tion of extracellular matrix leading to fibrosis development<sup>39</sup>. Since collagen is the major component of the extracellular matrix deposited in hepatic fibrosis, most antifibrotic therapies have been directed toward the control of collagen metabolism. Present study evaluated changes in the expression and activity of metalloproteinase, MMP-9, and its inhibitor TIMP-1 during liver fibrosis exacerbations in BDL rats.

Enhanced cysteinyl leukotriene production can increase the tissue damage due to its vasoconstrictive, mutagenic, and chemotactic effects, resulting in more mononuclear cell recruitment.<sup>40</sup> Repetitive tissue damage induces repair processes in liver tissue which are mostly mediated by TGF- $\beta$ . The latter downregulates the gene encoding for MMP-9, associated with an upregulation of the gene for TIMP.<sup>41</sup> Since the action of MMPs is regulated by TIMPs, the MMPs/TIMPs ratio may be considered as evaluating marker for collagenolytic enzyme activity.

VEGF represents an important chemotactic mediator resulting in recruitment of mononuclear cells in damaged tissue. The current findings demonstrated that the inflammatory process occurred during liver cholestasis may involve intrahepatic angiogenesis and up-regulation of VEGF. This may be in close relationship to TGF- $\beta$  expression.<sup>42</sup> Experimental data supported the implication of angiogenic factors expressed by hepatocytes as a key event in the development of hepatic fibrosis.<sup>43</sup>

The failure of bile salt excretion in cholestasis here certainly leads to retention of hydrophobic bile salts within the hepatocytes and causes apoptosis and/or severe fibrosis. This was evidenced by marked increase in collagen content (Hp levels) and its deposition around the portal triad and CV (Masson's trichrome stain). In addition, extended necrotic areas and edema were frequently observed with marked ductular proliferation. These findings are in agreement with previous studies.<sup>1,44</sup>

This study evaluates the effects the LT receptor blocker (montelukast) on factors involved in necro-inflammatory lesions and liver fibrogenic events in BDL rats. The current results demonstrated that montelukast effectively reversed fibrosis and liver damage induced by biliary obstruction in rats. It reduced the degree of hepatocellular injury as observed through decreased ALT, ALP activities, liver MDA and morphological aspects of the fibrotic liver. Moreover, the beneficial effect of montelukast on postoperative hepatic cholestasis was shown in this study, it reduced the liver expression of TGF- $\beta$  and NF- $\kappa$ B by inflammatory cells and increased the expression of MMP-9 by sinusoidal cells. These effects coincided with a significant increase in MMP-9/TIMP-1 ratio suggesting that such treatment favored a collagenolytic activity. These findings are consistent with previous studies showing the potential of 5-LO-derived products to modulate the expression and synthesis of proinflammatory cytokine in monocytes and macrophages<sup>45</sup>. Blocking the CysLTs receptors are responsible for increased permeability and recruitment of



**Figure 2.** Effect of montelukast treatment on collagenolytic activity (MMP-9/TIMP-1 ratio) in BDL rats.

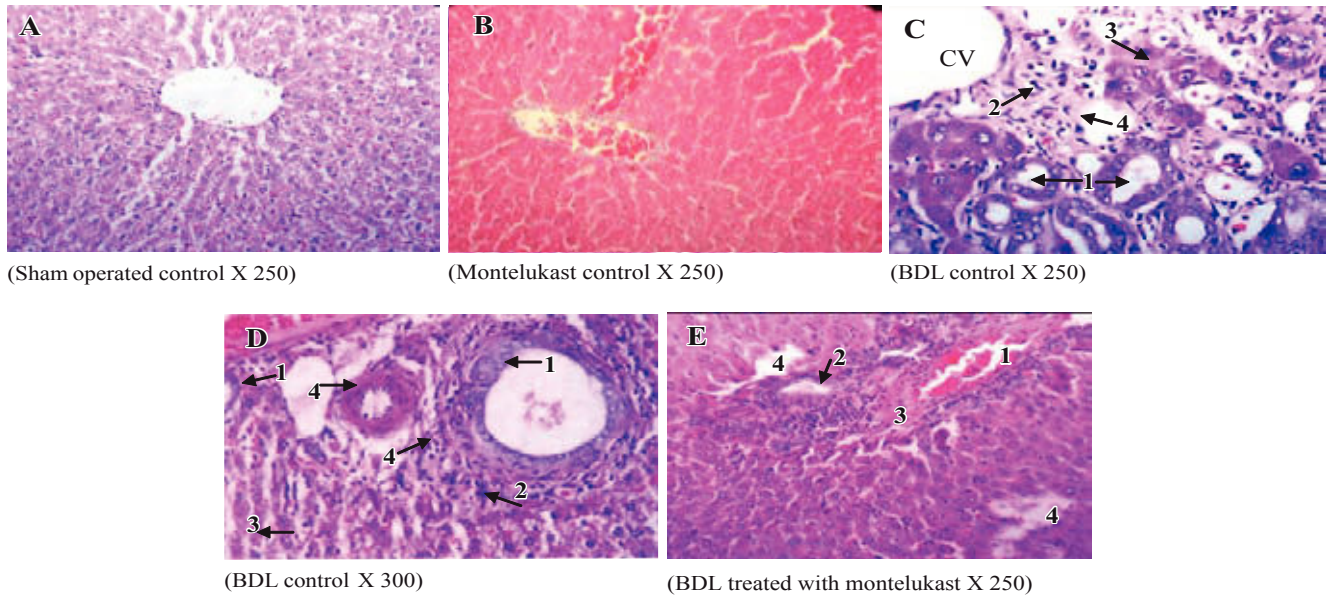
Values are mean  $\pm$  SD of six observations, \* $p$  < 0.001 vs sham-operated control and montelukast control, # $p$  < 0.01 vs BDL group.



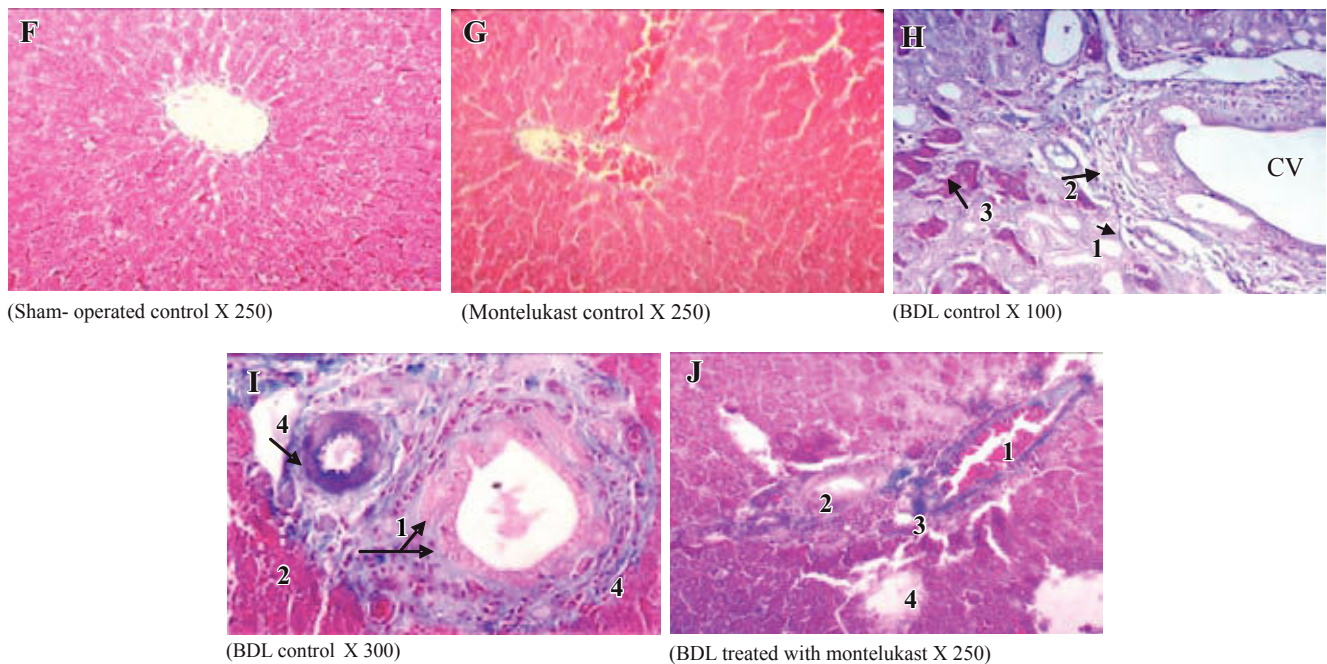
neutrophils and macrophages may be of benefit here. Montelukast may also act as an antioxidant not only by blocking the recruitment of neutrophils and macrophages, but also through an interaction with the receptors expressed on the neutrophils and macrophages.<sup>46</sup>

Furthermore, the LT receptor blocker significantly decreased VEGF expression in agreement with reported studies.<sup>47,48</sup> However, the exact explanations for the pathophysiological interactions between VEGF expression and LT production were obscure, we speculated that

### H & E



### Massion's trichrome



**Figure 3.** Histological sections of liver tissue stained with H&E (upper panels, A-E) or Masson's trichrome (lower panels, F-J). Representative photomicrographs of sham-operated control (A,F) showing normal liver parenchyma with hepatocytes and sinusoids and normal hepatic architecture. sham-operated control treated with montelukast (B,G) showed normal hepatic architecture with mild congestion<sup>1</sup> and edema<sup>2</sup>. BDL rats (C,D,H,I) showed severe bile duct proliferation,<sup>1</sup> leukocytes around the portal traid and the CV,<sup>2</sup> necrosis of hepatocytes<sup>3</sup> and fibrous tissue proliferation.<sup>4</sup> BDL rats treated with montelukast (E, J) showed mild congestion,<sup>1</sup> few bile duct proliferations with degeneration,<sup>2</sup> mild degree of periportal fibrosis<sup>3</sup> and moderate focal necrosis.<sup>4</sup>

**Table IV.** Histopathological changes associated with bile duct ligation and montelukast treatment in rats.

Histopathological appearance	Sham-operated control	Montelukast control	BDL	BDL treated with montelukast
Portal inflammation	-	+	++++	++
Bile duct proliferation	-	-	++++	++
Interlobular bile duct degeneration	-	-	++++	++
Necrosis	-	-	++++	+++
Fibrosis	-	-	++++	++
Edema	-	+	+++	++

Scoring was done as follow: (-) abscent; (+) mild; (++) moderate; (+++) severe, (+++++) extremely severe.

VEGF expression may be augmented due to endothelial cell damage induced by BDL. In concert with TGF- $\beta$  enhanced expression of VEGF resulting in mononuclear cell recruitment into damaged liver tissue, the main source of enhanced LT production.<sup>49</sup> The current study demonstrated that LT receptor blocker montelukast was able to down-regulate the expression of VEGF and TGF- $\beta$ .

Other mechanisms independent of direct 5-LO inhibition to exert hepatoprotective actions was through activation of peroxisome proliferator-activated receptor- $\gamma$ , a transcription factor that mediates anti-inflammatory and antifibrogenic effects in the liver.<sup>49</sup>

In summary, The current data support the concept that 5-LO pathways have converging functions, not only in the progression of liver inflammation, but also in cell proliferation, angiogenesis and fibrosis in BDL animal model. Our findings suggest that cysteinyl leukotriens antagonist may favor collagenolytic activity by modulating hepatic expression of TGF- $\beta$ , NF- $\kappa$ B, TIMP-1 and MMPs. These effects may account for the beneficial strategy for prevention of necroinflammatory liver injury and fibrogenesis. This may encourage further experimental and clinical studies to evaluate the efficacy of montelukast in the management of hepatic fibrosis and its comorbid complications.

## References

- Lee TY, Chang HH, Chen JH, Huseh ML, Kuo JJ. Herb medicine Yin-Chen-Hao-Tang ameliorates hepatic fibrosis in bile duct ligation rats. *Journal of Ethnopharmacology* 2007; 109: 318-24.
- Pauli-Magnus C, Meier PJ. Hepatobiliary transporters and drug induced. *Hepatology* 2006; 44(4): 778-87.
- Schuppan D, Afdhal NH. Liver cirrhosis. *Lancet* 2008; 371(9615): 838-51.
- Steib CJ, Gerbes AL, Bystron M, OP den Winkel M, Hartl J, Roggell F, Prufer T, Goke B, Bilzer M. Kupffer cell activation in normal and fibrotic livers increases portal pressure via thromboxane A (2). *J Hepatol* 2007; 47(2): 228-38.
- Cho MK, Lee GH, Park EY, Kim SG. Hyaluronic acid inhibits adhesion of hepatic stellate cells in spite of its stimulation of DNA synthesis. *Tissue Cell* 2004; 36(5): 293-305.
- Yin SS, Li XM, Wang BE, Wang TL, Jia JD, Qian LX. The relationship of serum metalloproteinase with the severity of liver fibrosis and inflammation. *Zhonghua Gan Zang Bing Za Zhi* 2004; 12(11): 666-68.
- Guo J, Friedman SL. Hepatic fibrogenesis. *Semin Liver Dis* 2007; 27(4): 413-26.
- Guido M, De Franceschi L, Olivari N, Leandro G, Feldr M, Corrocher R, Rugge M, Pasino M, Lanza C, Capelli P, Fattovich G. Effects of interferon plus ribavirin treatment of NF- $\kappa$ B, TGF- $\beta$  1, and metalloproteinase activity in chronic hepatitis C. *Mod Pathol* 2006; 19(8): 1047-54.
- Kim KR, Moon HE, Kim KW. Hypoxia induced angiogenesis in human hepatocellular carcinoma. *J Mol Med* 2002; 80(11): 703-14.
- Skora J, Biegus J, Pupka A, Barc P, Sikora J, Szyber P. Molecular basics of angiogenesis. *Postepy Hig Med Dosw* 2006; 60: 410-15.
- Medina J, Sanz-Cameno P, Garcia-Buey L, Martin-Vilchez S, Lopez Cabrera M, Moreno Otero R. Evidence of angiogenesis in primary biliary cirrhosis: an immunohistochemical descriptive study. *J Hepatol* 2005; 42(1): 124-31.
- Titos E, Claria J, Bataller R, Bosch- Marce M, Gines P, Jimenez W, Arroyo V, Rivera F, Rodes J. Hepatocyte derived cysteinyl leukotrienes modulate vascular tone in experimental cirrhosis. *Gastroenterology* 2000; 119(3): 794-805.
- Sala A, Folco G. Nutrophils, Endothelial cells, and cysteinyl leukotrienes: a new approach to neutrophil dependent inflammation? *Biochem Biophys Res Commun* 2001; 25, 283(5): 1003-6.
- Titos E, Claria J, Planaguma A, Lopez Parra M, Villamor N, Parrizas M, Carrio A, Miquel R, Jimenez W, Arroyo V, Rivera F, Rodes J. Inhibition of 5-lipoxygenase induces cell growth arrest and apoptosis in rat kupffer cells: implications for liver fibrosis. *FASEB* 2003; 17(12): 1745-47.
- Titos E, Claria J, Planaguma A, Lopez Parra M, Gonzalez Periz A, Gaya J, Miquel R, Arroyo V, Rodes J. Inhibition of 5-lipoxygenase activating protein abrogates experimental liver injury: role of kupffer cells. *J Leukoc Biol* 2005; 78(4): 871-8.
- Yang YY, Lin HC, Huang YT, Lee TY, Lee WC, Hou MC, Lee FY, Chang FY, Lee SD. Adaptive vasodilatory response after octreotide treatment. *American Journal of Physiology* 2001; 281: G117-G123.
- Sener G, Sakarcan A, Sehirli O, Demiralp EE, Sener E, Ercan F, Gedik N, Yegen BC. Chronic renal failure induced multiple organ injury in rats is alleviated by the selective CysLT-1 receptor antagonist montelukast. *Prostaglandins & Other Lipid-Mediators* 2007; 83: 257-67.
- Yang Q, Xie RJ, Luo XH, Han B, Yang T, Fang L. Expression of PKC in rat hepatic fibrosis and the effect of Dan-shao-hua-xian Capsule on its expression pattern. *Zhonghua Gan Zang Bing Za Zhi* 2005; 13: 707-8.
- Reitman S, Frankel SA. Colorimetric methods for determination of serum oxaloacetic and glutamic pyruvic transaminases. *Am J Clin Pathol* 1957; 28: 56-63.
- Bergmeyer HU, Grabl M, Walter HE, Enzymes. In: Bergmeyer J, Grabl M, Editors. *Methods of enzymatic analysis*. Weinheim: Verlag Chemic 1983; p. 269- 70.
- Winsten S, Cehelyk BA, rapid micro diazo technique for measuring total bilirubin. *Clin Chim Acta* 1969; 25: 441-6.
- Buge JA, Aust SD. Microsomal lipid peroxidation. *Methods Enzymol* 1978; 52: 302-10.



23. Javelaud D, Mauviel A. Mammalian transforming growth factor betas: S-mad signaling and physio-pathological roles. *Int J Biochem Cell Biol* 2004; 36: 1161-65.
24. Fujita M, Shannan JM, Morikawa O, Gauldie J, Hara N, Masan RJ. Over expression of tumor necrosis factor  $\alpha$  diminishes pulmonary fibrosis induced by bleomycin or transforming growth factor  $\beta$ . *American Journal of Respiratory Cell and Molecular Biology* 2003; 29: 1-7.
25. Chomkczynski P, Sacchi N. Single step method for RNA isolation by the acid guanidinium thiocyanate phenol chloroform methods. *Analytical Biochemistry* 1987; 162: 156-160.
26. He-lin D, Ying G, Ming-ton XU, Hai-yan LI, Zu-zhi FU. Effect of angiotensin II receptor blocker on glucose induced mRNA expressions of matrix metalloproteinase-9 and tissue inhibitor of metalloproteinase-1 in rat mesangial cells. *Chinese Medical Journal* 2007; 21: 18886-89.
27. Drury RA, Wallington EA. *Histological techniques*. 5th edn, Oxford University press, Oxford 1980: 27-29.
28. Bancroft GD, Stevens A, Turner DR. *Theory and practice of technique*. 4th edition, Churchill Livingstone, New York 1996.
29. Senedcor GW, Cochran WG. *Statistical methods 7th ed Iowa Uni. Press*. Ames. Iowa USA 1981; 175-191.
30. Park PH, Nan J, Park EJ, Kang HC, Kim JY, Ko G, Sohn DH. Effect of tetrandrine on experimental hepatic fibrosis induced by bile duct ligation and scission in rats. *Pharmacology & Toxicology* 2000; 87: 261-68.
31. Nishimura D, Imoto M, Satake T et al. Mechanism of liver mitochondrial dysfunction associated with bile duct obstruction. *Arzeim Forsch Drug Res* 1985; 35: 1427-30.
32. Zhong Z, Froth M, Lehnert M, Schoonhoven R, Yang L, Ling H, Lemasters JJ, Thurman LG. Polyphenols from camellia sinensis attenuate experimental cholestasis induced liver fibrosis in rats. *Am J Physiol Gastrointest Liver Physiol* 2003; 285: G1004-13.
33. Myoshi H, Rust C, Roberts PJ, Burgart LJ, Gores GJ. Hepatocyte apoptosis after bile duct ligation in the mouse involves fas. *Gastroenterology* 1999; 117: 669-77.
34. Sokol RJ, Devereaux MW, Khandwata R. Effect of oxypurinol a xanthine oxidase inhibitor, on hepatic injury in the bile duct ligated rat. *Pediatr Res* 1998; 44: 397-401.
35. Hisamori S, Tabata C, Kadokawa Y, Okoshi K, Tabata R, Mori A, Nagayama S, Watanabe G, Kubo H, Sakai Y. All-trans retinoic acid ameliorates carbon tetrachloride induced liver fibrosis in mice through modulating cytokine production. *Liver Int* 2008 (Epub ahead of print).
36. Brasier AR. The NF-kappa  $\beta$  regulatory network. *Cardiovasc toxicol* 2006; 6: 111-30.
37. Anan A, Baskin BE, Bronk SF, Werneburg NW, Shah VH, Gores GJ. Proteasome inhibition induces hepatic stellate cell apoptosis. *Hepatology* 2006; 43: 335-344.
38. De Minicis S, Seki E, Uchinami H, Kluwe J, Zhang Y, Brenner DA, Schwabe RF. Gene expression profiles during hepatic stellate cell activation in culture and *in vivo*. *Gastroenterology* 2007; 132(5): 1937-46.
39. Morlion BJ, Torwesten E, Kuhn KS, Puchstein CP. First Cysteinyl leukotriene generation as a biomarker for survival in the critically ill. *Crit Care Med* 2000; 28: 3655-58.
40. Zhao ZJ, Liu XM, Zhou GP. Changes of matrix metalloproteinase 2, 9 and tissue inhibitor of metalloproteinase 1, 2, 3 expression level in aged rat lung. *Beijing Da Xue Xue Bao* 2008; 40(1): 101-4.
41. Ueno T, Nakamura T, Torimura T, Sata M. Angiogenic cell therapy for hepatic fibrosis. *Med Mol Morphol* 2006; 39(1): 16-21.
42. Medina J, Sanz-Cameno P, García-Buey L, Martín-Vílchez S, López-Cabrera M, Moreno-Otero R. Evidence of angiogenesis in primary biliary cirrhosis: an immunohistochemical descriptive study. *J Hepatol* 2005; 42: 124-31.
43. Takeshita A, Shibayama Y. Role of mast cells in hepatic remodeling during cholestasis and its resolution: relevance to regulation of apoptosis. *Experimental Toxicological and Pathology* 2005; 56: b273-80.
44. Rossi A, Acquaviva AM, Iuliano F, Di Paola R, Cuzzocrea S, Sautebin L. Up-regulation of prostaglandin biosynthesis by leukotriene C4 in elicited mice peritoneal macrophages activated with lipopolysaccharide/interferon (gamma). *J Leukoc Biol* 2005; 78(4): 985-91.
45. Sener S, Kabasakal L, Cetinel S, Contuk G, Gedik N, Yegen BC. Leukotriene receptor blocker montelukast protects against burn induced oxidative injury of the skin and remote organs. *Burns* 2005; 31: 587-96.
46. Kanazawa H, Nomura S, Asai K. Roles of angiotensin-1 and angiotensin-2 on airway microvascular permeability in asthmatic patients. *Chest* 2007; 131(4): 1035-41.
47. Atakan A, Arikian H, Macunluoglu B, Tuglular S, Ulfer G, Cakalagaoglu F, Ozener C, Akoglu E. Renal protective effects of leukotriene receptor blockers in an experimental model of cyclosporine nephrotoxicity. *Transplant Proc* 2008; 40(1): 279-84.
48. Hus YC, Chiu YT, Lee CY, Wu CF, Huang YT. Anti fibrotic effects of tetrandrine on bile duct ligated rats. *Can J Physiol Pharmacol* 2006; 84(10): 967-76.
49. Wang HY, Cheng ML. Effects of Dan Shao-Hua-xian on expression of PPAR-  $\gamma$  and NF-Kappa B in rat liver fibrosis. *Hepatobiliary Pancreat Dis Int* 2008; 7(2): 179-84.