

Methimazole-induced hypothyroidism causes alteration of the REDOX environment, oxidative stress, and hepatic damage; events not caused by hypothyroidism itself

Edgar Cano-Europa,* Vanessa Blas-Valdivia,* Gabriel Eduardo Lopez-Galindo,* Margarita Franco-Colin,** Marisol Pineda-Reynoso,* Adelaida Hernandez-Garcia,* Rocio Ortiz-Butron*

* Laboratorio de Neurobiología y ** Laboratorio de Metabolismo I del Departamento de Fisiología "Mauricio Russek Berman", Escuela Nacional de Ciencias Biológicas, I.P.N. México, D.F.

ABSTRACT

Our objective was to compare, over a time-course, markers of oxidative stress, the REDOX environment, and the antioxidant enzymatic system in the liver of rats with methimazole- or thyroidectomy-caused hypothyroidism. **Methods.** We used 60 male Wistar rats divided into four groups: 1) the euthyroid, which received only tap water, 2) false thyroidectomy, which received the surgery and postoperative treatment, 3) thyroidectomy-caused hypothyroidism, which had the thyroid gland removed and a parathyroid reimplant, and 4) methimazole-caused hypothyroidism in rats that received 60 mg/kg/d of the antithyroid drug in drinking water. Five rats of the euthyroid and methimazole-caused hypothyroidism groups were killed at the end of the first, second, third, and fourth week after treatment, and five rats of false thyroidectomy and thyroidectomy-caused hypothyroidism groups were killed at the end of the second and eighth week after the surgical procedure. Each liver was removed and stored at -70 °C until oxidative stress, REDOX environment, and antioxidant enzymatic system markers were tested. We also made a histological study at the end of the treatment. **Results.** The histological study revealed that only the methimazole-caused hypothyroidism caused cell damage. This damage is associated with an increase of oxidative stress markers that were not compensated for by the antioxidant system. The catalase activity is reduced and this allows H₂O₂-caused damage. In conclusion methimazole causes cell damage in the liver, whereas hypothyroidism per se does not cause hepatic-cell damage.

Key words. Antioxidant systems. Antithyroid drug. Liver. Reactive oxygen species. Thyroidectomy. Thyroid gland.

INTRODUCTION

Methimazole is an antithyroid drug used in the treatment of hyperthyroidism in United States, Europe, and Asia. Methimazole is actively concentrated by the thyroid gland against a concentration gradient. The primary effect is to inhibit thyroid-hormone synthesis by interfering with thyroid-peroxidase-mediated thyroglobulin organification.¹ However, there are methimazole extrathyroidal effects reported; agranulocytosis, cholestasis, urtica-

ria, loss of taste and smell, nephrotoxicity, and liver damage.²⁻⁴ The thyroid hormone 3, 5, 3'-triiodo-thyronine (T₃) has a fundamental role in the development, differentiation, and physiology of all cells in the organism.⁵ One of the most studied effects of thyroid hormone is the control of the basal metabolic rate. The hypermetabolic state caused by a hyperthyroidism uncoupled-respiratory mitochondrial chain generates free radicals causing oxidative stress and cellular damage.⁶ However, the hypothyroidism-caused hypometabolic state protects against oxidative damage caused by toxicants.⁷ Some reports have noted that antithyroid-caused hypothyroidism can cause cellular damage.^{8,9} Thus, other extrathyroidal effects of antithyroid drugs as methimazole could contribute to the oxidative stress and cellular damage in liver. In general, the cellular damage occurs when the balance between oxidants and antioxidants is disturbed and the antioxidant

Correspondence and reprint request: Rocio Ortiz-Butron, PhD.
Escuela Nacional de Ciencias Biológicas. Carpio y Plan de Ayala. México D.F., 11340, México. Tel. :: (525) 729-6300/62481 and 52342. FAX: (525) 729-62-06
E-mail: rocipn@yahoo.com.mx

Manuscript received: October 17, 2009.
Manuscript accepted: February 02, 2010.

system does not neutralize the oxidants. An enhancement of the oxidant system helps cause lipid peroxidation, enhancement of reactive oxygen species, and nitration, carbonylation or glutathionylation of proteins, and fragmentation of DNA.^{10,11} Our objective was to determine if methimazole or hypothyroidism causes an alteration of the REDOX environment, oxidative stress, and cellular damage in the liver.

METHODS

Animals and housing

Sixty male Wistar rats from our animal care facilities were used. Animals were singly housed (metallic cages, 20 x 30 x 18 cm, with food and water *ad libitum*). The cages were located together in racks (so that auditory and olfactory contact was maintained) in a light (0800 to 2000 lights on) and temperature (21 ± 1 °C) controlled room. Food and water were always available. The rats were allowed to acclimatize to the colony-room conditions for at least 1 week before the start of the experiments. All experimental procedures described in this study are in accordance with the guidelines of the Laws and Codes of Mexico in The Seventh Title of the Regulations of the General Law of Health Regarding Health Research and Mexican Official Standard NOM-082-ZOO-1999 detailing the technical specifications for production, care, and use of laboratory animals. We used the minimum number of animals required to attain the goals of this study.

Experimental design

The rats were randomly divided into four groups: 1) the euthyroid ($n = 20$), which received only tap water, 2) false thyroidectomy ($n = 10$), which received the surgery and postoperative treatment, 3) thyroidectomy-caused hypothyroidism ($n = 10$), which had the thyroid gland removed, the parathyroid reimplanted, and postoperative treatment, 4) methimazole-caused hypothyroidism ($n = 20$), in which the rats received 60 mg/kg/day of the anti-thyroid drug (Sigma Chemical Co.) in drinking water daily during treatment. The dose was adjusted according to water intake and body weight every three days throughout the experiment, as described.¹²

The thyroidectomy was done in rats anesthetized with ketamine (Pisa-Mexico) (10 mg/kg, im) and xylazine (Pisa-Mexico) (5 mg/kg, im) as described.⁹

Briefly, using a stereomicroscope (Zeiss, Germany) for better observation, the stenothyroid muscle was cut and the trachea was exposed. The parathyroid gland was found, dissected from the thyroid gland, and reimplanted into the surrounding neck muscle. The thyroid gland was carefully dissected to avoid injury to the laryngeal nerve and completely excised. After surgery, we injected ketorolac (Syntex-Mexico) (50 mg/kg IM) and gentamicin (Schering Plough-Mexico) (10 mg/kg IM) over 5 days to alleviate pain and prevent infection.

During treatment the body weight and rectal temperature were evaluated to indirectly determine the thyroid state.

Five rats of the euthyroid and methimazole-caused hypothyroidism groups were killed by decapitation at the end of first, second, third, and fourth week after treatment. Also, five rats of the false thyroidectomy and thyroidectomy-caused hypothyroidism groups were killed by decapitation at the end of the second and eighth week after the surgical procedure. The liver of each rat was removed and stored at -70 °C until biochemical assay tests were made.

We evaluated the serum concentration of thyroid hormones (T_3 and T_4) in all groups when the rats were killed. In the surgical groups we measured the serum concentration of calcium and phosphorus.

We also made a histological study at the end of the treatment to demonstrate hepatic damage.

Biochemical assays

All livers were individually homogenized in 7 mL of 10 mM phosphate buffer, pH 7.4, and the homogenate used to determine oxidative stress, the REDOX environment, and the antioxidant enzymatic markers.

The oxidative stress markers evaluated were lipid peroxidation (LP) and the quantification of reactive oxygen species (ROS) as described.¹³

The REDOX environmental markers evaluated were reduced glutathione (GSH), oxidized glutathione (GSSG), and the $GSH^2/GSSG$ ratio, as described.¹³

The activity of catalase, glutathione peroxidase (GPX), and the isoforms of superoxide dismutase (SOD) were determined as the antioxidant enzymatic-system markers, as described.¹³

Histological study

Parts of the livers, not homogenized, were fixed with Buoin fixer for 16 h and then were embedded in

paraffin. Coronal cuts of 7 μm were obtained with a standard microtome. Each section was stained with hematoxylin-eosin, dehydrated, and mounted with resin. The microscopic description of the section was made by a person blind to the experiment by checking about 10 sections for each animal.

RESULTS

Physical measures and hormone determination related to the hypothyroid state

Figure 1 shows the physical variables evaluated; rectal temperature (panels A and C) and body weight (panels B and D) during treatment. We noted that both hypothyroidism models had reduced rectal temperatures and a decreased body weight during the antithyroid treatment.

Methimazole-caused hypothyroidism reduced the rectal temperature from week 2 to the end of the treatment (between group: $F_{1,40} = 7.98$, $P < 0.009$; between week: $F_{4,40} = 43.97$, $P < 0.001$; interaction

group x week: $F_{4,40} = 33.97$, $P < 0.001$). The treatment decreased the body weight at week 4 (between group: $F_{1,40} = 2.98$, $P > 0.05$; between week: $F_{4,40} = 4.50$, $P < 0.05$; interaction group x week: $F_{4,40} = 0.33$, $P = 0.88$).

Thyroidectomy-caused hypothyroidism decreased the rectal temperature from week 4 to the end of the treatment (between group: $F_{1,20} = 47.98$, $P < 0.001$; between week: $F_{8,20} = 53.97$, $P < 0.001$; interaction group x week: $F_{8,20} = 49.80$, $P < 0.001$). The body weight decreased in the treated group from the second week to the end of the treatment (between group: $F_{1,20} = 17.98$, $P < 0.01$; between week: $F_{8,20} = 33.17$, $P < 0.001$; interaction group x week: $F_{8,20} = 19.80$, $P < 0.01$).

The thyroid state was determined by means of a free thyroid-hormone determination. In table 1, it shows that the methimazole-caused hypothyroidism reduced free-serum T_4 (between group: $F_{1,40} = 10.12$, $P < 0.001$; between week: $F_{3,40} = 30.00$, $P < 0.001$; interaction group x week: $F_{3,40} = 27.97$, $P < 0.001$) and T_3 (between group: $F_{1,40} = 11.10$, $P < 0.001$;

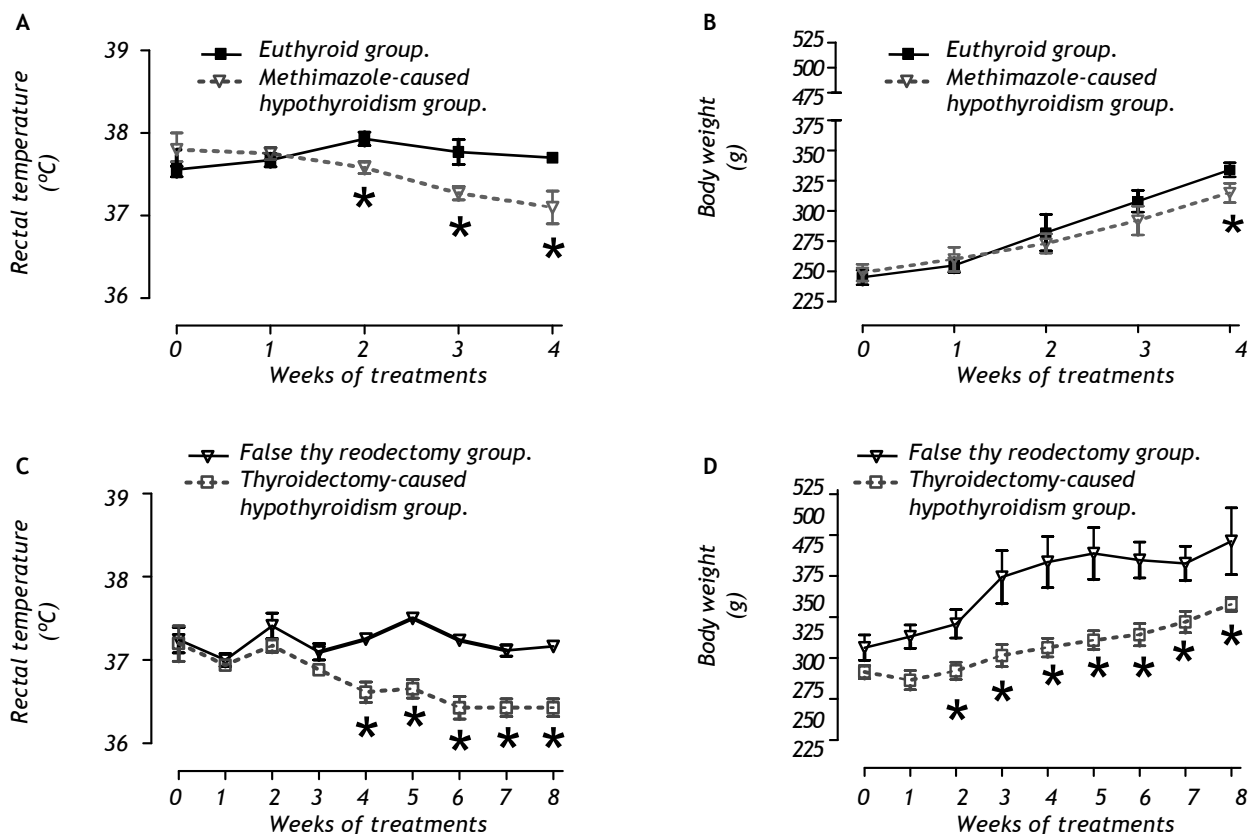


Figure 1. Evaluation of rectal temperature (A and C) and body weight (B and D) of methimazole-caused hypothyroidism group (A and B) or thyroidectomy-caused hypothyroidism group (C and D). * $P < 0.05$ vs. respective control in the same week.

Table 1. Determination of free serum T₃ and T₄ in methimazole-caused hypothyroidism group.

Week of treatment	Free serum T ₄ (nmol/L)		Free serum T ₃ (nmol/L)	
	Euthyroid group (n = 5)	Methimazole-caused hypothyroidism (n = 5)	Euthyroid group (n = 5)	Methimazole-caused hypothyroidism (n = 5)
1	1.50 ± 0.07	1.61 ± 0.23	73.2 ± 30.5	52.0 ± 25.5
2	1.17 ± 0.13	0.71 ± 0.05 *	127.1 ± 20.8	39.6 ± 19.9 *
3	1.06 ± 0.14	0.59 ± 0.14 *	79.6 ± 15.5	11.8 ± 3.4 *
4	1.16 ± 0.18	0.71 ± 0.14 *	100.4 ± 10.5	5.6 ± 2.2 *

* $P < 0.05$ vs. euthyroid group. Data values are mean ± SE.**Table 2.** Determination of free serum T₃ and T₄ in thyroidectomy-caused hypothyroidism group.

Week of treatment	Free serum T ₃ (nmol/L)		Free serum T ₄ (nmol/L)	
	False thyroidectomy group (n = 5)	Thyroidectomy-caused hypothyroidism group (n = 5)	False thyroidectomy group (n = 5)	Thyroidectomy-caused hypothyroidism group (n = 5)
2	1.55 ± 0.27	1.94 ± 0.14	115.7 ± 18.0	3.4 ± 1.2 *
8	1.73 ± 0.12	1.21 ± 0.13 *	101.2 ± 11.6	3.8 ± 0.4 *

* $P < 0.05$ vs. false thyroidectomy group. Data values are mean ± SE.**Table 3.** Determination of serum Ca²⁺ and P⁵⁺ in thyroidectomy-caused hypothyroidism group.

Week of treatment	Serum Ca ²⁺ (mg/dL)		Serum P ⁵⁺ (mg/dL)	
	False thyroidectomy group (n = 5)	Thyroidectomy-caused hypothyroidism group (n = 5)	False thyroidectomy group (n = 5)	Thyroidectomy-caused hypothyroidism group (n = 5)
2	7.37 ± 0.55	8.10 ± 0.50	3.52 ± 0.24	3.71 ± 0.31
8	8.00 ± 0.54	7.88 ± 0.61	2.91 ± 0.33	3.26 ± 0.33

Data values are mean ± SE.

between week: $F_{3,40} = 29.85$, $P < 0.001$; interaction group x week: $F_{3,40} = 22.15$, $P < 0.001$) from week 2 to the end of the treatment. Thyroidectomy-caused hypothyroidism caused a reduction of free T₄ in both weeks evaluated (between group: $F_{1,19} = 78.98$, $P < 0.001$ (Table 2); between week: $F_{2,31} = 60.01$, $P < 0.001$; interaction group x week: $F_{2,31} = 59.82$, $P < 0.001$). The free T₃ was decreased at the end of the treatment (between group: $F_{1,19} = 43.12$, $P < 0.001$; between week: $F_{2,31} = 50.00$, $P < 0.001$; interaction group x week: $F_{2,31} = 48.23$, $P < 0.001$).

The thyroidectomy-caused hypothyroidism did not modify the serum Ca²⁺ and P⁵⁺ (Table 3).

Oxidative stress markers

Panel A of figure 2 shows that the methimazole-caused hypothyroidism causes an increase of lipid peroxidation at the fourth week (between group $F_{1,32} = 7.98$, $P < 0.009$; between week $F_{3,32} = 1.597$,

$P = 0.215$; and interaction groups x week $F_{1,32} = 2.68$, $P < 0.059$) because it enhances the ROS concentration on the third week of treatment (panel B, between group $F_{1,32} = 14.68$, $P < 0.001$; between week $F_{1,32} = 0.66$, $P = 0.618$; and interaction groups x week $F_{3,32} = 1.09$, $P = 0.370$). Panel C shows thyroidectomy-caused hypothyroidism does not cause lipid peroxidation, but it enhances the ROS concentration in the second week postsurgery (between group $F_{1,16} = 1.43$, $P = 0.250$; between week $F_{1,16} = 0.994$, $P = 0.334$; and interaction groups x week $F_{1,16} = 5.17$, $P < 0.05$).

REDOX environment markers

Panel A of figure 3 shows that the methimazole-caused hypothyroidism causes an increase of GSH during the first week of treatment (between group: $F_{1,32} = 6.55$, $P < 0.05$; between week: $F_{3,32} = 0.45$, $P = 0.719$; and interaction groups x week:

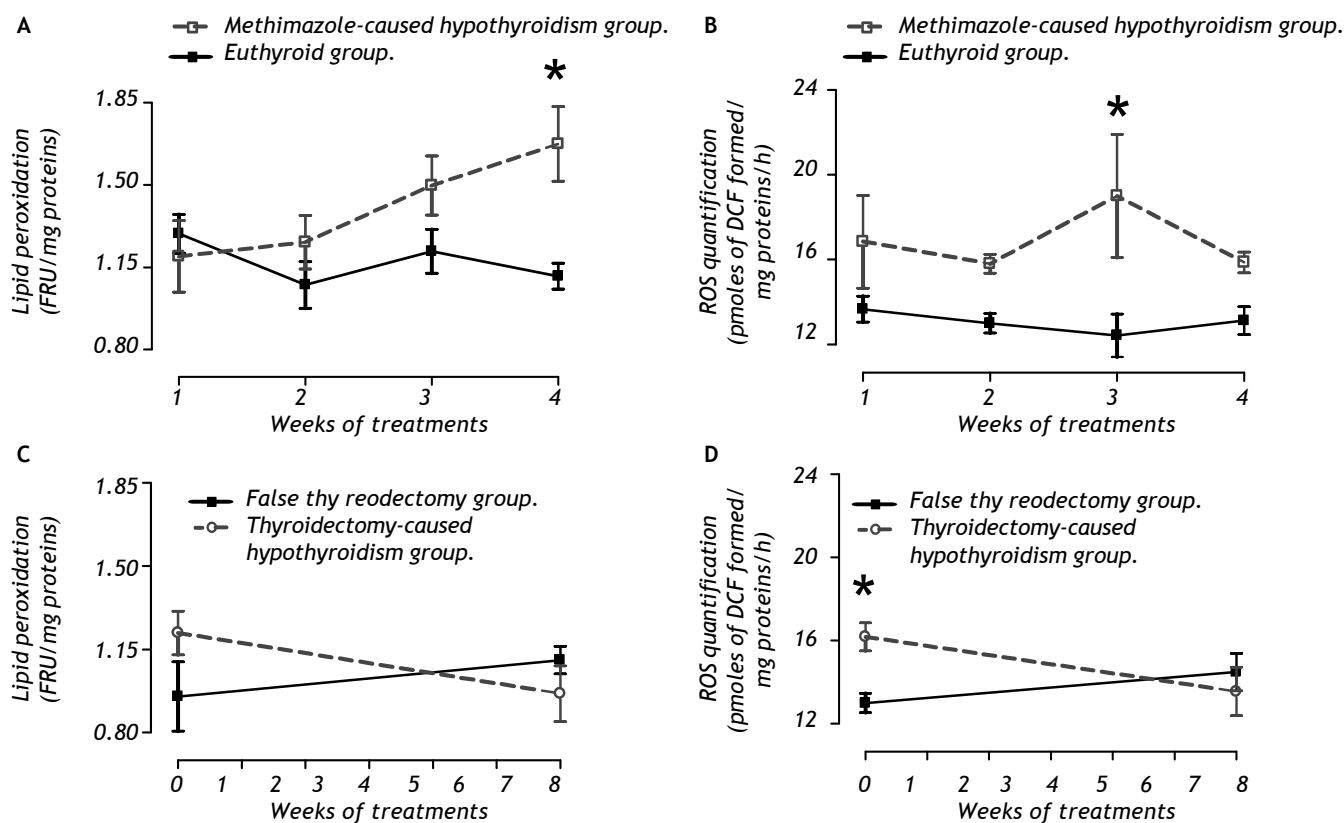


Figure 2. Evaluation of lipid peroxidation (A and B) and quantification of reactive oxygen species (B and D) as oxidative markers in the liver of methimazole-caused hypothyroidism group (A and B) or thyroidectomy-caused hypothyroidism group (C and D). * P < 0.05 vs. respective control.

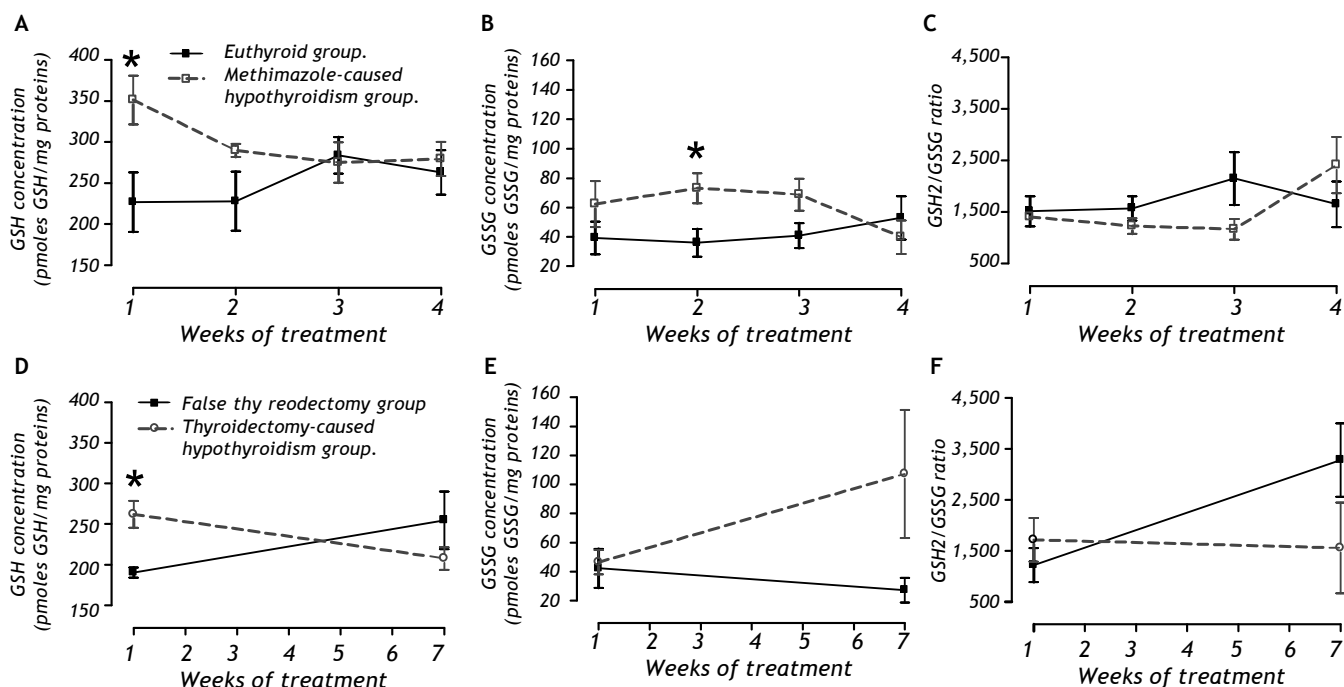


Figure 3. Quantification of reduced glutathione (GSH; panels A and D), oxidized glutathione (GSSG; panels B and E), and the GSH²/GSSG ratio (C and F) as REDOX environmental markers in the liver of methimazole-caused hypothyroidism group (A-C) or thyroidectomy-caused hypothyroidism group (D-F). * P < 0.05 vs. respective control.

Table 4. Activity of SOD isoforms in the liver of methimazole-caused hypothyroidism group.

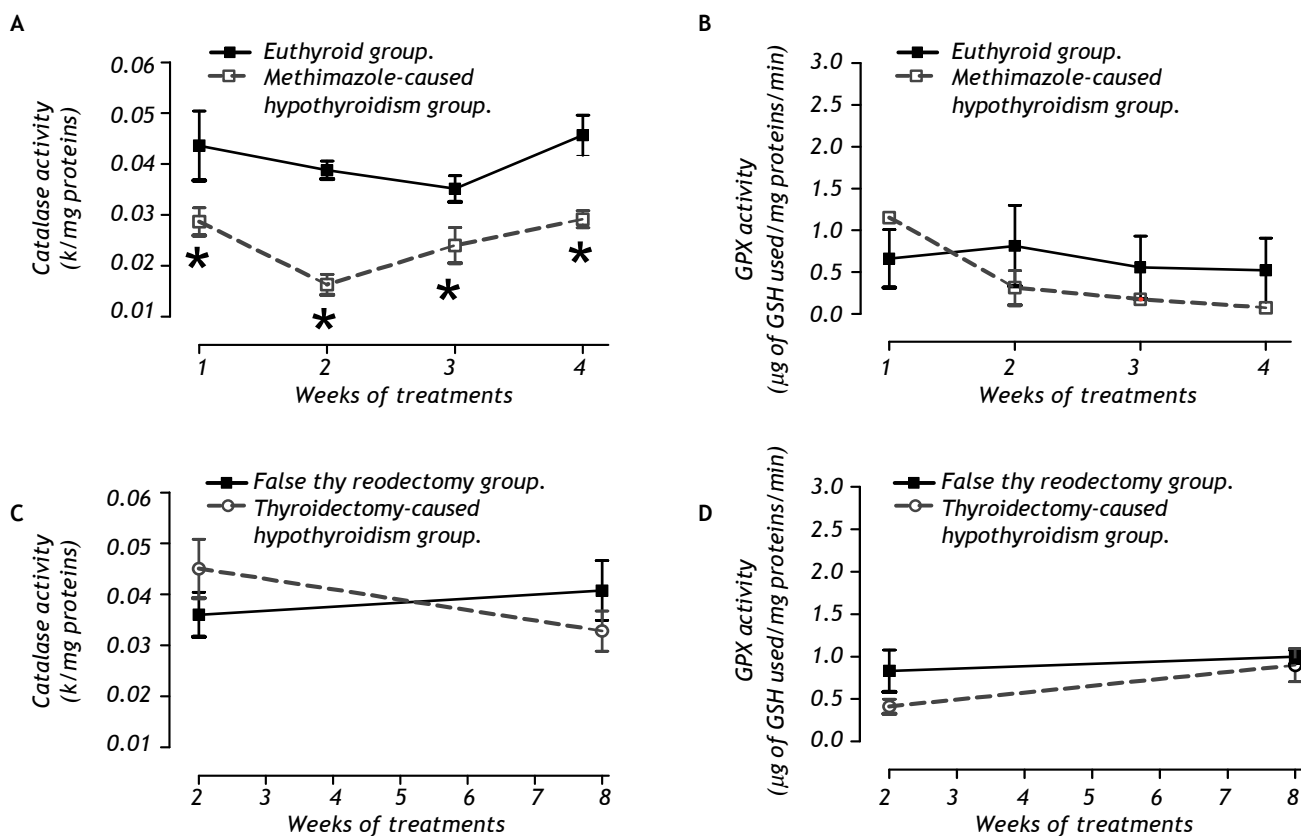
Week of treatment	Mn-SOD activity (U/mg proteins)		Cu-Zn-SOD activity (U/mg proteins)		Total SOD activity (U/mg proteins)	
	Euthyroid group (n = 5)	Methimazole-caused hypothyroidism (n = 5)	Euthyroid group (n = 5)	Methimazole-caused hypothyroidism (n = 5)	Euthyroid group (n = 5)	Methimazole-caused hypothyroidism (n = 5)
1	0.286 ± 0.041	0.212 ± 0.070	0.025 ± 0.065	0.158 ± 0.074	0.491 ± 0.090	0.370 ± 0.035
2	0.092 ± 0.026	0.178 ± 0.075	0.300 ± 0.054	0.260 ± 0.028	0.392 ± 0.030	0.437 ± 0.036
3	0.181 ± 0.059	0.216 ± 0.037	0.243 ± 0.097	0.215 ± 0.119	0.424 ± 0.075	0.426 ± 0.102
4	0.176 ± 0.036	0.262 ± 0.054	0.177 ± 0.036	0.188 ± 0.040	0.353 ± 0.026	0.450 ± 0.058

Data values are mean ± SE.

Table 5. Activity of SOD isoforms in the liver of thyroidectomy-caused hypothyroidism group.

Week of treatment	Mn-SOD activity (U/mg proteins)		Cu-Zn-SOD activity (U/mg proteins)		Total SOD activity (U/mg proteins)	
	False thyroidectomy group (n = 5)	Thyroidectomy-caused hypothyroidism group (n = 5)	False thyroidectomy group (n = 5)	Thyroidectomy-caused hypothyroidism group (n = 5)	False thyroidectomy group (n = 5)	Thyroidectomy-caused hypothyroidism group (n = 5)
2	0.092 ± 0.026	0.206 ± 0.060	0.300 ± 0.054	0.284 ± 0.077	0.392 ± 0.031	0.491 ± 0.053
8	0.207 ± 0.074	0.228 ± 0.047	0.224 ± 0.044	0.095 ± 0.019	0.432 ± 0.038	0.323 ± 0.053

Data values are mean ± SE.

**Figure 4.** Activity of catalase (A and C) and glutathione peroxidase (GPX, panels B and D) in the liver of methimazole-caused hypothyroidism group (A-B) or thyroidectomy-caused hypothyroidism group (C-D). * P < 0.05 vs. respective control.

$F_{1,32} = 2.13$, $P = 0.12$). This treatment causes an enhancement of GSSG during the second week (panel B; between group: $F_{1,32} = 4.41$, $P < 0.05$; between week: $F_{3,32} = 0.20$, $P = 0.90$; and interaction groups x week: $F_{1,32} = 1.81$, $P = 0.17$). Panel C shows that there are no changes in the GSH²/GSSG ratio.

The thyroidectomy-caused hypothyroidism group did have an increase in GSH after the second week postsurgery (panel D). The GSSG concentration was not affected (panel E) and there was no change in the GSH²/GSSG ratio (panel F).

Antioxidant enzymatic system

For peroxidases, panel A of figure 4 shows that only the methimazole treatment produces a decrease

of the catalase activity (between group: $F_{1,32} = 44.93$, $P < 0.001$; between week: $F_{3,32} = 3.98$, $P < 0.05$; and interaction groups x week: $F_{1,32} = 2.99$, $P < 0.05$), without any effect on the glutathione peroxidase. The activities of the SOD isoforms of both hypothyroid groups are indicated in the tables 4 and 5. There were no changes of the SOD in these groups.

Histological analysis

We found in the histological analysis of liver parenchyma (Figure 5) that the microscopic appearance of the euthyroid group (panel A), false thyroidectomy group (panel B), and thyroidectomy group (panel C) had similar characteristics with their hepatocytes in a radial distribution. The me-

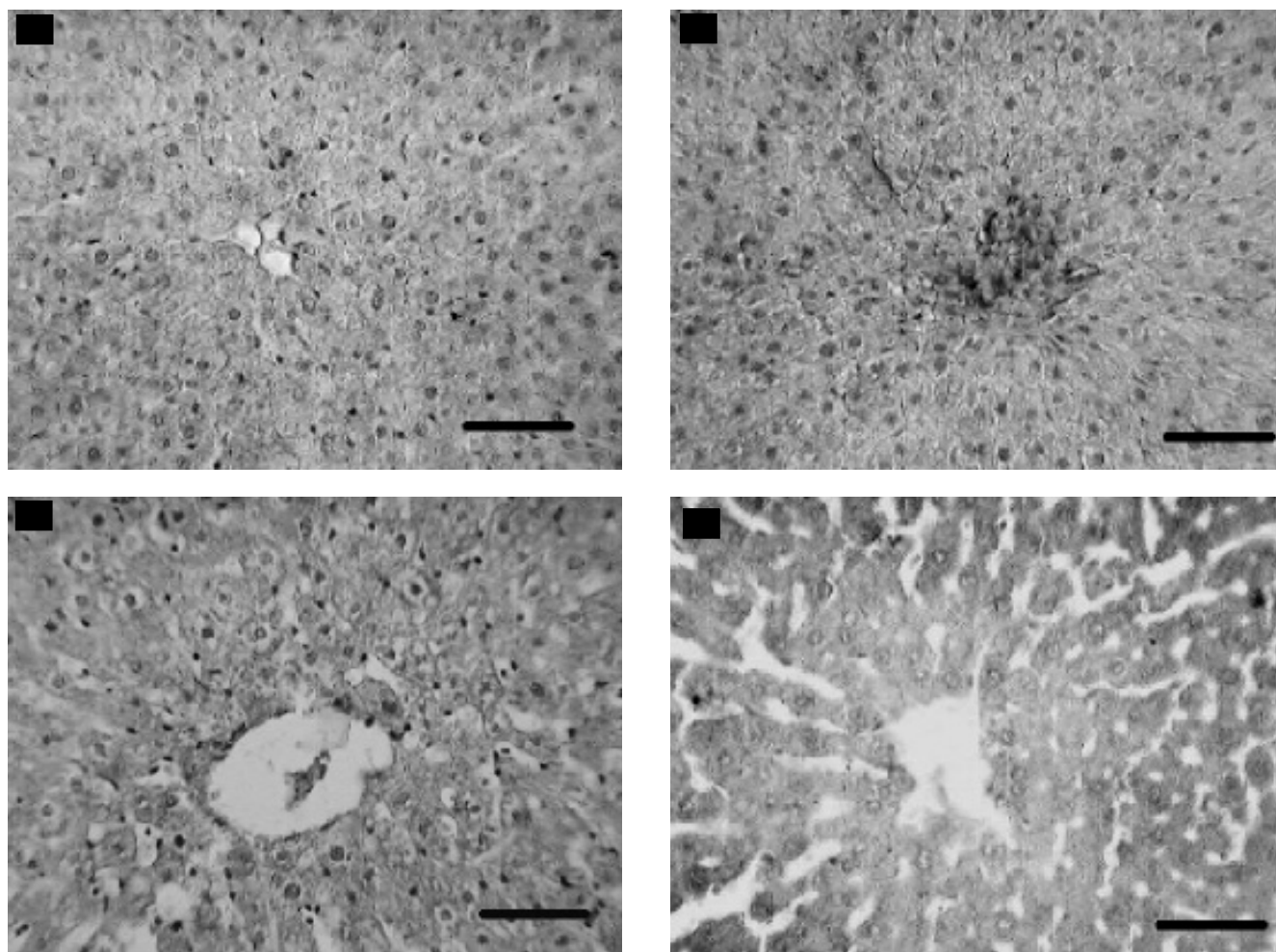


Figure 5. Photomicrography of hepatic tissue. Euthyroid group (A); false thyroidectomy (B); thyroidectomy-caused hypothyroidism (C); methimazole-caused hypothyroidism group (D). Histological alterations were present only in the methimazole-caused hypothyroidism group (panel D). Horizontal line represents 50 μ m.

thimazole-caused hypothyroidism group showed cellular discontinuity, the hepatocyte radial distribution was lost, and there was hyperplasia of the hepatocytes and alteration of the nucleus-cytoplasm ratio (panel D).

DISCUSSION

Methimazole is widely used in the treatment of hyperthyroidism because it inhibits thyroid peroxidase and avoids thyroglobulin organification. However, there are reported extrathyroidal effects related to cellular damage from methimazole. The methimazole-caused hypothyroidism has two effects on cellular damage. One effect is a protective mechanism against toxicant-caused oxidative stress.^{14,15} and the other is the mechanism of methimazole-caused oxidative stress and cellular damage.^{9,16,17} In our research we show that methimazole and not the hypothyroidism is responsible for the hepatic damage. We demonstrated in this study that methimazole-caused hypothyroidism caused oxidative stress, alteration of the GSH-GSSG couple, and reduction of catalase activity, without modifying the SOD activity. All these were related to hepatic damage, as we observed. In addition, thyroidectomy-caused hypothyroidism enhanced both the ROS and GSH during the second week without developing hepatic damage.

The liver is an organ with a high metabolic activity that generates ROS. Under physiological conditions the presence of antioxidant enzymes, in particular peroxidases and dismutases, prevent oxidative stress and tissue damage.^{18,19} However, some drugs, like methimazole, disturb the physiological steady state. Methimazole alters the intracellular REDOX environment and causes cellular damage because of oxidant generation and ROS, and consequently lipid peroxidation is not completely neutralized by the antioxidant system.

The central mechanism of methimazole-caused liver damage is based on the reduction of catalase activity caused by a methimazole-inactivated catalytic center.^{20,21} Catalase is one of the most important peroxidases in the liver that prevents the metabolism-enhanced H_2O_2 .²² Although Glutathione peroxidase (GPX) did not modify its activity, the catalase inactivation causes high levels of H_2O_2 in the cells. This substance can diffuse through the plasma membrane and affect neighboring cells. High H_2O_2 concentration causes the increase of ROS and thus lipid peroxidation (LP).¹⁰

Most studies that relate hypothyroidism with liver damage are unacceptable because they used thio-

namide-caused hypothyroidism,^{23,24} and this drug itself causes liver damage, as described.⁹

Other methimazole-caused damage mechanisms are associated with its chemical structure and its biotransformation. Some investigators using methimazole-caused hepatotoxicity have shown that the drug binds covalently in the hepatocytes, mainly those next to the hepatic triad.^{25,26} For biotransformation, methimazole may be oxidized by P450 enzymes to form the 4,5-epoxide. The enzymatic or nonenzymatic hydrolysis of the epoxide formed would produce an unstable hemiketal-like intermediate, which is expected to undergo spontaneous ring cleavage to form glyoxal and *N*-methylthiourea. The metabolism of *N*-methylthiourea is complex, but it is believed that sulfur oxidation, mediated mainly by flavin-monooxygenase (FMO, EC. EC 1.14.13.8), proceeds primarily to the sulfenic acids and then possibly to the sulfinic acids. This step is necessary in the bioactivation of thioureas resulting in protein binding, enzyme inactivation, and organ toxicity.^{27,28}

The condition of hypothyroidism itself predisposes hepatocyte damage because of an increase in polyunsaturated fatty acid (PUFA) synthesis, which compounds are susceptible to peroxidation,²⁹ and the reduction of liver proliferation.^{30,31} We did not see hepatic alterations in the thyroidectomy group. Besides, there are molecular mechanisms by which hypothyroidism itself may produce a protected state of the liver, such as reducing the enzyme activity associated with the mitochondrial respiratory chain,³² the decrease in adenine nucleotide translocase,³³ reduced activity of cytochrome-c oxidase,³⁴ and the resistance to forming the permeability transition-pore formation of the inner mitochondrial membrane.³⁵

Finally, we can agree that the sole hypothyroidism-caused thyroidectomy does not affect the intracellular REDOX environment. We agree with several groups that hypothyroidism does not cause liver damage per se and this state is protected against toxic agents.

ACKNOWLEDGEMENT

Thanks to Dr. Ellis Glazier for editing this English-language text.

This study was partially supported by SIP-IPN 20070318 and 20080113. M.F.C. is fellow of EDI, COFAA and SNI. R.O-B is fellow of EDI and COFAA. V.B-V is fellow of CONACyT and PIFI-COFFA.

REFERENCES

- Cooper DS. Antithyroid drugs. *The New England Journal of Medicine* 2005; 352(9): 905-17.
- Bandyopadhyay U, Biswas K, Banerjee RK. Extrathyroidal actions of antithyroid thionamides. *Toxicol Lett* 2002; 128(1-3): 117-27.
- Casallo BS, Valero MA, Sanchez FM, de Matias SL, Blanco GJJ, Martin BMJ. [Methimazole and propylthiouracil induced acute toxic hepatitis]. *Gastroenterol Hepatol* 2007; 30(5): 268-70.
- Woeber KA. Methimazole-induced hepatotoxicity. *Endocr Pract* 2002; 8(3): 222-4.
- Hulbert AJ. Thyroid hormones and their effects: a new perspective. *Biol Rev Camb Philos Soc* 2000; 75(4): 519-621.
- Venditti P, Di Meo S. Thyroid hormone-induced oxidative stress. *Cell Mol Life Sci* 2006; 63(4): 414-34.
- Oren R, Dotan I, Papa M, Marravi Y, Aeed H, Barg J, et al. Inhibition of experimentally induced cirrhosis in rats by hypothyroidism. *Hepatology* 1996; 24(2): 419-23.
- Bergman U, Brittebo EB. Methimazole toxicity in rodents: covalent binding in the olfactory mucosa and detection of glial fibrillary acidic protein in the olfactory bulb. *Toxicol Appl Pharmacol* 1999; 155(2): 190-200.
- Cano-Europa E, Blas-Valdivia V, Franco-Colín M, Gallardo-Casas CA, Ortiz-Butron R. Methimazole-induced hypothyroidism caused cellular damage in spleen, heart, liver, lung and kidney. *Acta Histochemica* 2009; In press.
- Halliwell B, Gutteridge JMC. Free radicals in biology and medicine. 3th Ed. UK: Oxford University Press; 2007.
- Valko M, Leibfritz D, Moncol J, Cronin MT, Mazur M, Telser J. Free radicals and antioxidants in normal physiological functions and human disease. *Int J Biochem Cell Biol* 2007; 39(1): 44-84.
- Ortiz-Butron R, Pacheco-Rosado J, Hernandez-Garcia A, Briones-Velasco M, Rocha L. Mild thyroid hormones deficiency modifies benzodiazepine and mu-opioid receptor binding in rats. *Neuropharmacology* 2003; 44(1): 111-16.
- Cano-Europa E, Lopez-Galindo GE, Hernandez-Garcia A, Blas-Valdivia V, Gallardo-Casas CA, Vargas-Lascari M, et al. Lidocaine affects the redox environment and the antioxidant enzymatic system causing oxidative stress in the hippocampus and amygdala of adult rats. *Life Sci* 2008; 83(19-20): 681-5.
- Elfarra AA, Duescher RJ, Sausen PJ, O'Hara TM, Cooley AJ. Methimazole protection of rats against gentamicin-induced nephrotoxicity. *Can J Physiol Pharmacol* 1994; 72(10): 1238-44.
- Oren R, Dotan I, Papa M, Marravi Y, Aeed H, Barg J, et al. Inhibition of experimentally induced cirrhosis in rats by hypothyroidism. *Hepatology* 1996; 24(2): 419-23.
- Liu WK, Ng TB. Effect of methimazole-induced hypothyroidism on alveolar macrophages. *Virchows Arch B Cell Pathol Incl Mol Pathol* 1991; 60(1): 21-6.
- Bergman U, Brittebo EB. Methimazole toxicity in rodents: covalent binding in the olfactory mucosa and detection of glial fibrillary acidic protein in the olfactory bulb. *Toxicol Appl Pharmacol* 1999; 155(2): 190-200.
- Konigsberg-Fainstein M. Radicales libres y estrés oxidativo. Aplicaciones médicas. México, D. F.: Manual Moderno; 2008.
- Angermuller S, Islinger M, Volkl A. Peroxisomes and reactive oxygen species, a lasting challenge. *Histochem Cell Biol* 2009; 131(4): 459-63.
- Bandyopadhyay U, Bhattacharyya DK, Chatterjee R, Banerjee RK. Irreversible inactivation of lactoperoxidase by mercaptomethylimidazole through generation of a thiyl radical: its use as a probe to study the active site. *Biochem J* 1995; 306(Pt 3): 751-7.
- Bandyopadhyay U, Biswas K, Banerjee RK. Extrathyroidal actions of antithyroid thionamides. *Toxicol Lett* 2002; 128(1-3): 117-27.
- Cesaratto L, Vascotto C, Calligaris S, Tell G. The importance of redox state in liver damage. *Ann Hepatol* 2004; 3(3): 86-92.
- Das K, Chainy GBN. Modulation of rat liver mitochondrial antioxidant defence system by thyroid hormone. *Biochim Biophys Acta* 2001; 1537(1): 1-13.
- Yilmaz S, Ozan S, Benzer F, Canatan H. Oxidative damage and antioxidant enzyme activities in experimental hypothyroidism. *Cell Biochem Funct* 2003; 21(4): 325-30.
- Decker CJ, Doerge DR. Covalent binding of 14C- and 35S-labeled thiocarbamides in rat hepatic microsomes. *Biochem Pharmacol* 1992; 43(4): 881-8.
- Lee PW, Neal RA. Metabolism of methimazole by rat liver cytochrome P-450-containing monooxygenases. *Drug Metab Dispos* 1978; 6(5): 591-600.
- Neal RA, Halpert J. Toxicology of thiono-sulfur compounds. *Annu Rev Pharmacol Toxicol* 1982; 22: 321-39.
- Mizutani T, Yoshida K, Kawazoe S. Formation of toxic metabolites from thiabendazole and other thiazoles in mice. Identification of thioamides as ring cleavage products. *Drug Metab Dispos* 1994; 22(5): 750-5.
- Hoch FL. Lipids and thyroid hormones. *Prog Lipid Res* 1988; 27(3): 199-270.
- Beyer HS. Lack of effect of hypothyroidism on rat liver regeneration. *Biochem Int* 1992; 27(3): 497-500.
- Cervinkova Z, Simek J. Effect of propylthiouracil on liver regeneration in rats after partial hepatectomy. *Physiol Res* 1992; 41(2): 141-6.
- Paradies G, Ruggiero FM, Petrosillo G, Quagliarriello E. Enhanced cytochrome oxidase activity and modification of lipids in heart mitochondria from hyperthyroid rats. *Biochim Biophys Acta* 1994; 1225(2): 165-70.
- Schonfeld P, Wieckowski MR, Wojtczak L. Thyroid hormone-induced expression of the ADP/ATP carrier and its effect on fatty acid-induced uncoupling of oxidative phosphorylation. *FEBS Lett* 1997; 416(1): 19-22.
- Paradies G, Petrosillo G, Ruggiero FM. Cardiolipin-dependent decrease of cytochrome c oxidase activity in heart mitochondria from hypothyroid rats. *Biochim Biophys Acta* 1997; 1319(1): 5-8.
- Chávez E, Franco M, Reyes-Vivas H, Zazueta C, Ramirez J, Carrillo R. Hypothyroidism renders liver mitochondria resistant to the opening of membrane permeability transition pore. *Biochim Biophys Acta* 1998; 1407(3): 243-8.