

Uncommon localization of amyloidosis in gallbladder: Description of a case and brief literature review

Daniela Tirota,* Vittorio Durante*

* Medicina Interna, Ospedale Cervesi di Cattolica, ASL Rimini (Italy).

ABSTRACT

Amyloidosis is a rare disease that is caused by extracellular deposits of amorphous, insoluble fibrillar protein, which often occur in the kidneys, the heart, the nervous system, the digestive tract, especially the hepatosplenic and intestinal tract, and can be present in bone marrow, though unusual in the gallbladder. The interest of this case lies in the rarity of amyloidosis localisation and in the uncommon clinical presentation as acute cholecystitis.

We have reviewed cases of amyloidosis with gallbladder involvement in literature and briefly discussed the predictive value of the main histological diagnostic methods.

Key-words. Amyloidosis. Cholecystitis. Gallbladder.

INTRODUCTION

Amyloidosis is a rare disease that is caused by extracellular deposits of amorphous, insoluble fibrillar protein. Five different types have been identified: immunoglobulin-associated amyloidosis, secondary amyloidosis; hemodialysis-associated amyloidosis, familial amyloidosis and senile amyloidosis.

We will describe a case of primary amyloidosis with heart, bone marrow and gallbladder involvement, with the uncommon clinical presentation as acute cholecystitis. Amyloid deposition is in fact frequent in the kidneys, the heart, the nervous system, the hepatosplenic and intestinal tract and can be present in bone marrow (40% of cases), but localisation in the gallbladder is uncommon.

We have reviewed cases of amyloidosis with gallbladder involvement in literature and briefly discussed the predictive value of the main histological diagnostic methods.

CASE REPORT

A 74-years-old patient was experiencing abdominal pain in the right hypochondrium and epigastrium.

The patient's medical history includes bronchial asthma at a young age, hypertension, mild dyslipidemia and also recent hospitalisation for pneumonia. Physical examination showed right upper quadrant pain, positive Murphy's sign, jaundice, and a grade 2/6 systolic heart murmur.

Laboratory tests reveal alterations in liver and pancreatic function (AST/ALT 70/73 U/l, gamma GT 231 U/l, ALP 220 U/l, amylase 216 U/l, lipase 281 U/l), and also biological inflammatory syndrome (C reactive protein 16 mg/dL).

An ultrasound to the abdomen detected diffuse gallbladder wall thickening (maximum diameter 6.3 mm), biliary sand and pericholecystic fluid (Figure 1). We also performed abdomen CT scan without contrast medium (serum creatinine is moderately increased), which did not confirm involvement of pancreatic parenchyma. The patient was diagnosed with acute cholecystitis and was placed on antibiotics.

During hospitalisation, however, two clinical problems occurred: electrocardiographic changes (little progression of R waves in precordial leads and T negative in lateral precordial leads) with cardiac enzymes negatives and on another occasion a significant monoclonal component.

Correspondence and reprint request: Dr. Daniela Tirota
Medicina Interna, Ospedale Cervesi di Cattolica, ASL Rimini (Italy).

Manuscript received: September 14, 2010.

Manuscript accepted: November 21, 2010.

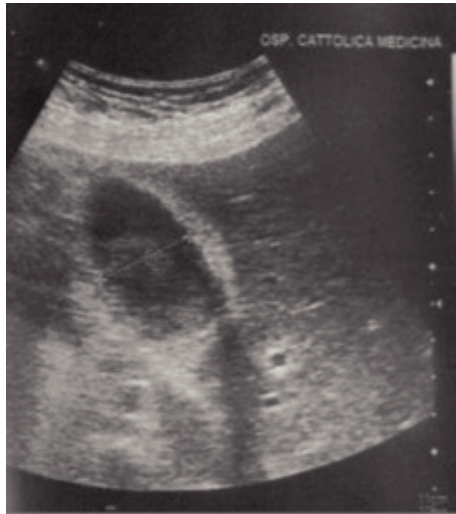

Figure 1. Abdomen US of patient.

Echocardiogram showed cardiomyopathy with severe concentric left ventricular hypertrophy. Moreover serum IgG lambda monoclonal levels were 17.3 g/l and blood tests showed: normocytic anaemia (Hb 10.3 g/dL, MCV 88), mild renal insufficiency (creatinine 1.8 mg/dL), finally, calcium levels, LDH, uric acid, microalbuminuria and urinary Bence Jones protein negatives.

Amyloidosis was suspected for gammopathy and discrepancy between low voltage QRS complex and echocardiography evidence of left ventricular hypertrophy. Furthermore a bone marrow biopsy was performed, which was compatible with multiple myeloma in the first anatomopathologic stage with micro hyaline deposits of amyloid in vessel walls. Finally X-rays of the shoulders, pelvis, spine and cranium were negative for osteolysis.

The patient was discharged, pending a minimally invasive cholecystectomy. Post discharge a periumbilical fat biopsy and a rectal submucosa were performed, both resulting negative for amyloidosis. Finally, a histological examination of the gallbladder, after cholecystectomy, detected ulcerated chronic cholecystitis with amyloid deposits, Congo red-positive in the lamina propria mucosae and vessel walls (Figure 2). We concluded, therefore, with a diagnosis of multiple myeloma, stage II, associated with amyloidosis, with cardiac, bone marrow and gallbladder involvement.

The patient was sent to a Center for amyloidosis, where the periumbilical fat biopsy proved positive for amyloidosis. The patient underwent a course of therapy with high dose dexamethasone, with mild reduction in monoclonal components

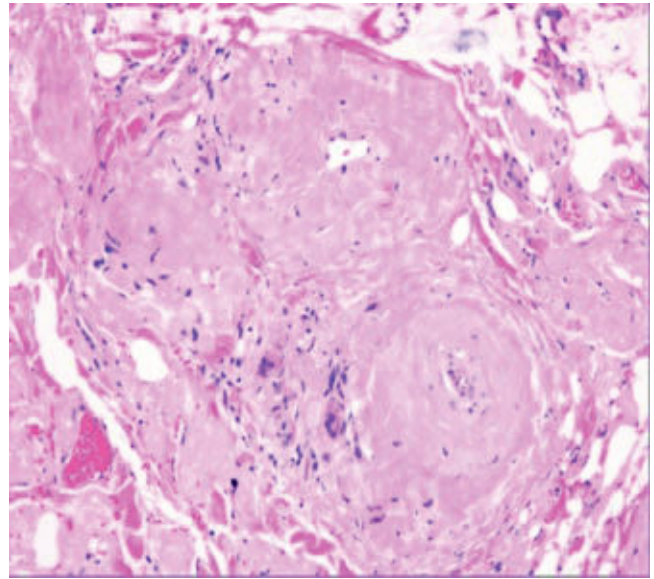


Figure 2. Microscopic finding of gallbladder in patient.

and subsequently Leukeran-Prednisone chemotherapy.

DISCUSSION

In literature reports of outbreaks of multiple myeloma as acute cholecystitis are rare; the trigger, however is a general increased susceptibility to infections.¹⁻³ Moreover, acute cholecystitis is less common than other diseases, such as, for example, pneumonia.

Cholecystitis secondary to gallbladder localisation of amyloidosis is even more unusual: generally amyloidosis affects the epithelium of the intrahepatic bile duct without reaching canaliculi and acini of glandular peribiliaires and the amount of bile deposits correlates with the extent of amyloidosis in liver parenchyma.⁴ In particular gallbladder localisation of amyloidosis has never been observed in experimental models of amyloidosis,⁵ in routine histopathological examinations of gallbladder in patients without liver amyloidosis,⁶ nor in a series of 21 patients with amyloidosis associated with polyneuropathy.⁷

Therefore we performed a systematic research on Pubmed for cases of gallbladder involvement (Mesh term 'cholecystitis' AND 'amyloidosis' and, then, 'gallbladder' AND 'amyloidosis', with detailed control of references). We obtained 10 cases; we excluded three⁸⁻¹⁰ for temporal limits (temporal limits: 1990-2010), with total of seven cases (Table 1).

Table 1. Cases with gallbladder localization of amyloidosis in literature. Abdomen US: abdomen ultrasonography; Abdomen TC: abdomen computed tomography.

Title	Authors, journal, year of publication	Type of article	Patient	Amyloidosis is type/Associated disease	Symptoms/ Liver function tests	Gallstone	Gallbladder in imaging (abdomen US/TC)	Latency Between Diagnosis of amyloidosis elsewhere and diagnosis of gallbladder's amyloidosis	Other localization of amyloidosis	Diagnostic method and finding of amyloidosis of gallbladder	Traditional Diagnostic methods for amyloidosis (periumbilical fat, salivary glands, rectal biopsy)
Amyloidosis of the gallbladder mimicking gallbladder cancer	A-Hon Kwon, Katsushige Tsuji, Hitoshi Yamada, Kazuichi Okazaki, Noriko Sakaïda J Gastroenterol 2007; 42 261-4	Case report and literature review	F, 63 year	Primary (AL), local	Occasional finding on abdominal US Liver tests: only gammaGT increased	-	Abdomen US: focal echogenic lesion in body of gallbladder Abdomen TC: nodular wall thickening in body of gallbladder, enhanced by contrast material	3 years	Gastrointestinal tract (duodenal)	Laparoscopic cholecystectomy for total biopsy of gallbladder Macroscopic examen: nodular lesion. Microscopic examen: amyloid depositions in vessel walls in submucosa and lamina propria of gallbladder	Not performed
Severe acute haemorrhagic cholelithiasis due to amyloidosis of the gallbladder	Denève E, Ramos J, Perrochia H, Nocca D, Schved JF, Fabre JM Gastroenterol Clin Biol. 2008 Apr; 32(4):426-9 Article in French	Case report	M, 42 years	Secondary (AA), systemic Refractory rheumatoid arthritis, ankylosing spondylitis	Right upper quadrant pain, fever, vomit Liver tests: liver stasis	-	Abdomen US: altiasic gallbladder with walls thickened, diffusely infiltrated and intraluminal hematoma, hepatosplenomegaly Abdomen TC: hematoma in the gallbladder lumen, edematous pancreatitis with pancreatic pseudocyst	5 years	Digestive tract with perforation, kidney, heart	Laparoscopic cholecystectomy therapeutic and for total biopsy of gallbladder Macroscopic examination intraluminal hematoma, multiples ulcerations in parietal and subserosa of gallbladder Microscopic examination: capillaries thickened for amyloid deposits	Not performed

Galbladder amyloidosis: an unusual localization	Remy AJ, Perney P, Bourat L, Ramos J, Marty M, Cabaniols H, Durand L, Quenet F, Blanc F Gastroenterol Clin Biol. 1995 Feb;19(2):215-7 Article in French	Case report	M, 60 years	Secondary (AA), systemic Pancreatic cancer	Right upper quadrant pain, fever, icter Liver function: icteric cholestatic	+	Abdomen US: gallbladder with thickened walls, with multiple litiasis	No latency	Liver	Laparoscopic cholecystectomy therapeutic. Macroscopic examination: litiasic cholecystitis chronic. Microscopic examination: amyloidosis in muscularis and serosa of gallbladder.	Rectal biopsy negative
Systemic amyloidosis: localization in the gallbladder	Casassus-Builhe D, Chauveau E, Bechade D, Terrrier F, Oddes B. Presse Med. 2000 Feb 19;29(6):306 Article in French	Letter	F, 76 years	Primary (AL), systemic	Dyspeptic syndrome, systemic disease Liver tests: non-icteric cholestasis and moderate cytolysis	-	Hepatomegaly without signs of portal hypertension, normal gallbladder	No latency	Liver, salivary glands, heart, enteric tract, kidney	Macroscopic examination: gallbladder wall thickening, Microscopic examination: deposit of amyloid in the vessel wall	Rectal and salivary glands biopsy : positives
Abdominal Amyloidosis: Spectrum of Radiological findings	S. H. Kim, J. K. Han, K. H. Lee, H. J. Won, K. W. Kim, J. S. Kim, C. H. Park and B. I. Choi Clinical Radiology 2003 Vol. 58, Issue 8, Pages 610-620 (August)	Retrospective observational study	M, 63 years	Secondary (NS), local (Pulmonary tuberculosis)	Right upper quadrant pain for acalculous cholecistitis Liver function tests: unspecified	-	Abdomen US: mild wall thickening of the gallbladder and 'dirty' pericholecystic infiltration, focal echogenic mass in the body of gallbladder	Unspecified	Kidney	Emergency cholecystectomy Macroscopic examination: acute suppurative cholecystitis. Microscopic examination: amyloid deposition in lamina propria and around small arteriole of submucosa	Not performed

<p>Familial Amyloidotic polynuropathy with a transthyretin Variant (Val 30 > Leu)]</p>	<p>Shimizu H, Ishikawa K, Kobayashi H, Murakami T, Nakazato M, Miura K, Atsumi T. No To Shinkei. 1996 Feb;48(2):175-8. Article in Japanese</p>	<p>Case report</p>	<p>F, 54 years</p>	<p>FAP (familial amyloidotic polynuropathy), systemic</p>	<p>Peripheral nerve and autonomic dysfunction, renal failure. Absent symptoms secondary to gallbladder disease Liver function tests: unspecified</p>	<p>-</p>	<p>Death at 3 years of clinical onset</p>	<p>Peripheral and autonomic nervous system, heart, blood vessels, kidney, bladder, gastrointestinal tract, submandibular glands, tongue, gallbladder, spleen, pancreas, thyroid, lung, liver, adrenal glands</p>	<p>Autopsy finding of involvement of gallbladder</p>	<p>Not performed</p>
<p>Diffuse small lymphoplasmacytic lymphoma of the GI tract associated with massive intestinal amyloidosis</p>	<p>Julian Arista Nasr, Carmen Lome-Maldonado Rev Inv Clin 1993;45:71-5</p>	<p>Case report</p>	<p>M, 80 years</p>	<p>Primary (AL), lymphoplasmacytic lymphoma of the GI tract associated</p>	<p>Symptoms related to interest of gastrointestinal tract: asthenia, fever, weight reduction, melena, diarrhea Liver function tests: unspecified</p>	<p>-</p>	<p>Autopsy finding (unspecified latency)</p>	<p>Intestinal tract</p>	<p>Autopsy finding: amyloid material as performed nodules or irregular masses that displace the lymphoid infiltrate in some fields and intermixed with neoplastic lymphocytes in others</p>	<p>Not performed</p>
<p>Present case</p>	<p>Case report</p>	<p>Case report</p>	<p>M, 74 years</p>	<p>Primary (AL) Multiple Myeloma</p>	<p>Asthenia, pain right hypochondrium Liver tests non-icteric cholestasis and moderate cytolysis</p>	<p>Biliary sand</p>	<p>Abdomen US: lithiasic gallbladder with walls thickened</p>	<p>Heart, Bone marrow</p>	<p>Diagnostic cholecystectomy Macroscopic examination: gallbladder wall thickening, Microscopic examination: deposit of amyloid in the vessel usual</p>	<p>Rectal and periumbilical fat biopsy: negative Second sample of periumbilical fat: positive</p>

Although the number of cases is small, gallbladder involvement appears to be present equally in primary and secondary forms, while there is a single case of familial amyloidosis.

Clinical spectrum is very wide: no symptoms,⁴ dyspeptic symptoms¹¹ or, finally, systemic disease or disease related to other organs involvement.¹²⁻¹⁴ Laboratory tests and imaging also are very varied: only unspecific gammaGT increase,⁴ anicteric cholestasis,¹⁵ jaundice,¹⁶ moderate cytolysis,¹⁴ in addition nodular or diffuse wall thickening of gallbladder,^{4,11,15} intraluminal hematoma;¹⁵ sometimes generic hepatomegaly only.¹⁴ Finally acute cholecystitis, as in our patient, is reported in three cases;^{11,15,16} only once gallstones also are described.¹⁶ Thus we believe that cholelithiasis represents a misleading element for the etiology of cholecystitis, more likely secondary to unusual localisation of amyloidosis.

In literature surgery does not improve digestive symptoms and, conversely, is complicated in one case by bilioperitoneo,¹⁶ due to the fragility of bile channels. In our case, however, the non-specificity of clinical picture made it difficult to form a preoperative diagnosis, as often occurs.

The final consideration is related to diagnosis of amyloidosis, sometimes obtained through the biopsy of parenchymal organs, associated with high diagnostic value (sensitivity of trans-dermal core kidney biopsy, for example, is close to 100%),¹⁷ but there is a high risk of bleeding.¹⁷ Therefore the biopsy of subcutaneous fatty tissue is most practised (sensitivity 73%-78%, specificity 90%-93%, positive predictive value 84%, negative predictive value 90%),¹⁷ less frequently labial salivary glands biopsy (80-85% sensitivity), rectal biopsy (73% sensitivity), gingival mucosa biopsy (40-46 % sensitivity).¹⁷ However a negative result of a traditional diagnostic method (in our patient the first biopsy of subcutaneous fatty tissue and the rectal biopsy) may be due to multiple causes: different practice setting, level of experience, absence of abdominal soft tissue involvement.

In conclusion even if gallbladder localisation of amyloidosis is very unusual, however it is appropriate to think about this, especially in cases of outbreak of multiple myeloma as acute cholecystitis. Since clinical picture is not specific, laparoscopic cholecystectomy with gallbladder biopsy is often necessary to exclude additional pathologies, although associated with high risk of bleeding. Finally a negative result of traditional diagnostic methods in presence of highly suggestive clinical images still require further investigation.

ACKNOWLEDGEMENTS

To Dott Anna Rita Lombardi, Anatomical Pathology Institute, Infermi Hospital, Rimini (Italy).

REFERENCES

1. Sherlock D, Jones B. Cholecystitis associated with myelomatosis. *Postgraduate Medical Journal* 1984; 60: 485-6.
2. Bernardeschi P, Bonechi I. Mieloma anaplastico non secernente. Descrizione di un caso primitivo. *Recenti Progressi in Medicina* 1986; 79(1).
3. Isobe T, Osserman EF. Pathologic conditions associated with plasma cell dyscrasias: a study of 806 cases. *Ann N Y Acad Sci* 1971; 190: 507-18.
4. Kwon AH, Tsuji K, Yamada H, Okazaki K, Sakaida N. Amyloidosis of the gallbladder mimicking gallbladder cancer. *J Gastroenterol* 2007; 42: 261-4.
5. Birt DF, Patil K, Pour PM. Comparative studies on the effects of semipurified and commercial diet on longevity and spontaneous and induced lesions. *Nutr Cancer* 1985; 7(3): 167-77.
6. Levy M, Polliack A, Lender M, Eliakim M. The liver in amyloidosis. *Digestion* 1974; 10: 40-51.
7. Steen LE, Oberg L. Familial amyloidosis with polyneuropathy: roentgenological and gastroscopic appearance of gastrointestinal involvement. *Am J Gastroenterol* 1983; 78: 417-20.
8. Chiba M, Inoue Y, Arakawa H, Masamune O, Ohkubo M. Bechet's disease associated with amyloidosis. *Gastroenterol Jpn* 1987; 22: 487-95.
9. Rodriguez JA, Maté G, Badal JM. Colecistitis aguda alitiásica en amiloidosis. *Med Clin (Barc)* 1988; 91: 78-9.
10. Bukharovich AM, et al. Skin amyloidosis in a patient with chronic pancreatitis and diabetes mellitus. *Vestn Dermatol Venerol* 1988; 3: 41-3.
11. Kim SH, Han JK, Lee KH, Won HJ, Kim KW, Kim JS, Park CH, Choi BI. Abdominal amyloidosis: spectrum of radiological findings. *Clin Radiol* 2003; 58: 610-20.
12. Shimizu H, Ishikawa K, Kobayashi H, Murakami T, Nakazato M, Miura K, Atsumi T. Familial amyloidotic polyneuropathy with a transthyretin variant (Val30 > Leu). *No To Shinkei* 1996; 48(2): 175-8.
13. Arista NJ, Lome-Maldonado C. Diffuse small lymphoplasmacytic lymphoma of the GI tract associated with massive intestinal amyloidosis. *Rev Inv Clin* 1993; 45: 71-5.
14. Casassus-Builhe D, Chauveau E, Bechade D, Terrier F, Odde B. Systemic amyloidosis: localization in the gallbladder. *Presse Med* 2000; 29: 306.
15. Denève E, Ramos J, Perrochia H, Nocca D, Schved JF, Fabre JM. Severe acute haemorrhagic cholecystitis due to amyloidosis of the gallbladder. *Gastroenterol Clin Biol* 2008; 4: 426-9.
16. Remy AJ, Perney P, Bourat L, Ramos J, Marty M, Cabaniols H, Durand L, et al. Amyloidosis of the gallbladder. An unusual localization. *Gastroenterol Clin Biol* 1995; 19: 215-7.
17. Bogov B, Lubomirova M, Kiperova B. Biopsy of subcutaneous fatty tissue for diagnosis of systemic amyloidosis. *Hippokratia* 2008; 12(4): 236-9.
18. Sedaghat D, Zakir RM, Choe J, Klapholz M, Saric M. Cardiac Amyloidosis in a patient with multiple myeloma: a case report and review of literature. *Journal of Clinical Ultrasound* 2009; 37(3).
19. Hassan W, Al-Sergani H, Mourad W, Tabbaa R. Amyloid heart disease. *Text Heart Inst J* 2005; 32: 178-84.
20. Kuroda T, Tanabe N, Sakatsume M, Nozawa S, Mitsuka T, Ishikawa H, Tohyama CT, et al. Comparison of gastroduodenal, renal and abdominal fat biopsies for diagnosing amyloidosis in rheumatoid arthritis. *Clin Rheumatol* 2002; 21(2): 123-8.