

## Aminoguanidine potentiates the hepatoprotective effect of silymarin in CCL<sub>4</sub> treated rats

Ahmed Fahmy Ahmed,\* Mona Fouad Mahmoud,\* Marwa Arafat Ouf,\* Eman Abd El-Fathaah\*\*

\*Department of Pharmacology, Faculty of Pharmacy, Zagazig University Egypt.

\*\*Department of Histology, Faculty of Medicine, Zagazig University Egypt.

### ABSTRACT

This study examined the possible hepatoprotective effect of aminoguanidine in comparison with silymarin and investigated the possible beneficial effects of the combination of aminoguanidine and silymarin on CCL<sub>4</sub>-induced liver fibrosis. Male Wister albino rats were randomly divided into five groups (10 rats/group). Group I included control rats injected only with liquid paraffin and saline; group II represents CCL<sub>4</sub> control (injected with CCL<sub>4</sub> 3 times a week for 6 weeks in a dose of 25µl/100gm.b.w i.p, diluted 1:6 with liquid paraffin); group III treated with aminoguanidine (100 mg/kg); group IV was given silymarin (100 mg/kg); group V was given aminoguanidine (100 mg/kg) and silymarin (100 mg/kg). Fibrosis was depicted histologically and biochemically.

CCL<sub>4</sub> increased serum liver enzymes (ALT, AST, and ALP), lactate dehydrogenase (LDH), level of nitric oxide (NO), tumor necrosis factor alpha (TNFα) and liver malondialdehyde content (MDA), collagen fiber percent and decreased liver reduced glutathione (GSH) content as endogenous antioxidant. Histopathological changes induced by CCL<sub>4</sub> include regenerative nodules, deteriorated parenchyma; the lobules were infiltrated with fat and structurally altered. Aminoguanidine, silymarin and their combination reduced these changes and attenuated the pathological effects of CCL<sub>4</sub> induced liver injury. The combination of both drugs was better than each drug alone. It is concluded that aminoguanidine has protective effect against CCL<sub>4</sub> induced hepatotoxicity via its iNOS inhibition and antioxidant effects. In addition, the combination of AG with silymarin has more potent hepatoprotective effect than each drug alone.

**Key words.** CCL<sub>4</sub>. Fibrosis. Aminoguanidine. Silymarin. iNOS. TNFα. collagen fiber.

### INTRODUCTION

Hepatic fibrosis is a common pathological process resulted from various chronic hepatic injuries, which is characterized by an increase of extracellular matrix (ECM) deposition in the Disse's space and the imbalance between synthesis and degradation of ECM.<sup>1</sup> The primary cause of liver fibrosis includes viral hepatitis, alcohol consumption, autoimmune disorders, drug-induced, helminthic infection, iron or copper overload and biliary obstruction.<sup>2</sup>

Nitric oxide (NO) is an important mediator of hepatotoxicity.<sup>3,4</sup> It is derived from two sources in li-

ver. Hepatocytes and Kupffer cells contain inducible NO synthase (iNOS), the activity of which is markedly increased in inflammation. Endothelial cells contain constitutive NO synthase (eNOS). Nitric oxide is known to react with superoxide radical, forming peroxynitrite, an even more potent oxidizing agent.<sup>5</sup> Peroxynitrite can react directly with sulfhydryl residues in the cell membranes leading to lipid peroxidation as well as with DNA resulting in cytotoxicity.<sup>6,7</sup> The enzyme iNOS is expressed during the development of cirrhosis. Therefore, the prevention of iNOS expression may have an important role in both cirrhosis and endotoxaemia.<sup>8</sup>

Aminoguanidine (AG) is a selective iNOS inhibitor,<sup>9-11</sup> although the mechanism underlying this is unclear. Previous studies showed that AG protection could be through decreasing the metabolic activation of CCl<sub>4</sub> by directly inhibiting P4502E1, the isoenzyme most effective in the activation of CCl<sub>4</sub>.<sup>12</sup>

Correspondence and reprint request: Mona F Mahmoud, PhD.  
Department of Pharmacology, Faculty of Pharmacy, Zagazig University Egypt.  
E-mail: mona\_pharmacology@yahoo.com

Manuscript received: October 23, 2010.

Manuscript accepted: January 25, 2011.

Silymarin is the most known hepatoprotective drug used as a reference standard also exhibited significant protective effect against CCL4 induced liver damage.<sup>13-17</sup>

Present study aimed to examine firstly the possible hepatoprotective effect of aminoguanidine in comparison with Silymarin. Secondly study the possible beneficial effects of the combination of aminoguanidine with silymarin on hepatic fibrosis induced experimentally by CCL4 injection in rats.

## MATERIAL AND METHODS

### Experimental animals

Adult male albino rats (220-250 g) were supplied by Egyptian Organization for Biological Products and Vaccine (Helwan, Egypt). Rats were housed in stainless steel cages at constant temperature of  $25 \pm 2$  °C, relative humidity of approximately 50%, illumination (12 h light/dark) and had free access to standard pellet chow and water ad Libitum. All experiments were carried out in accordance with protocols approved by the local experimental ethics committee.

### Experimental design

One week after acclimatization, rats were randomly divided into five groups (10 rats/each). Group I includes control rats injected only with liquid paraffin and saline; group II injected with CCL<sub>4</sub> 3 times a week for 6 weeks in a dose of 25  $\mu$ L/100 gm.b.w i.p, diluted 1:6 with paraffin oil to induce fibrosis; group III was given aminoguanidine (100 mg/kg); group IV was given silymarin (100 mg/kg); group V was given aminoguanidine and silymarin in the same previously mentioned doses. Groups (III, IV and V) received single oral daily dose of drugs for 2 weeks followed by concurrent administration of CCL<sub>4</sub> for 6 weeks. At the end of the experiment, all animals from each group were anaesthetized with urethane (1.3 g/kg) and blood samples were collected from retroorbital sinus,<sup>18,19</sup> subjected to serum separation and divided into aliquots. Fresh sera were tested for liver enzymes and other aliquots were stored at -20 °C for later biochemical analysis. Rats were then killed by decapitation; Livers were perfused with phosphate buffer solution (PBS) [PH = 7.4] containing 0.16 mg/mL heparin. Then livers were isolated and dissected into 3 parts. The first part was cut into longitudinal sections 2-4mm, in thickness and kept in 10%

formalin in saline for histopathological examination. The second part was immersed immediately in liquid nitrogen and kept at -80 °C for determination of glutathione and malondialdehyde contents. The third part was fixed in glutaraldehyde for electron microscopical examination.

### Biochemical analysis

- **Liver function tests.** Serum ALT and AST activities were determined by a colorimetric method according to Reitman and Frankel.<sup>20</sup> Serum alkaline phosphatase activity was determined by enzymatic colorimetric method according to Young, *et al.*<sup>21</sup>
- **Liver GSH and membrane oxidation.** The reduced form of glutathione was determined in the liver homogenate by colorimetric method according to Beutler, *et al.*<sup>22</sup> Malondialdehyde (MDA) content as indicator of lipid peroxidation was determined in the liver homogenate, by a colorimetric method according to Satoh, *et al.*<sup>23</sup>
- **Liver cell death.** Serum lactate dehydrogenase activity as indicator of cell death was determined using a kinetic method according to Vassault, *et al.*<sup>24</sup>
- **TNF- $\alpha$  measurement.** Serum TNF- $\alpha$  was determined using an enzyme-linked immunosorbent assay according to.<sup>25</sup>
- **Collagen content.** Quantitative determination of collagen fibers in liver was performed according to the method of Crookham and Dapson.<sup>26</sup>
- **NO level:** Serum nitric oxide levels were measured by a colorimetric method as described by Montgomery and Dymock.<sup>27</sup>

### Histopathological analysis

For light microscopic investigations, specimens from liver were fixed in 10% phosphate buffer formalin, dehydrated in alcohols and embedded in paraffin. Five micron tissue sections were stained with hematoxylin and eosin stain (H&E) for general histopathological examination. Another part of liver was fixed in glutaraldehyde and processed for electron microscopical examination.

### Statistical analysis

Results were expressed as mean  $\pm$  SE. Statistical evaluation was done using one-way analysis of variance (ANOVA), and Tukey's multiple comparison test using SPSS software version 12, SPSS Science,

Chicago, Illinois, USA. Values of  $p < 0.05$  were considered significant.

## RESULTS

### Number of deaths of animals

We started the study with 18 rat/CCL<sub>4</sub> group and 10 rats/normal control, other groups treated with drugs was 15 rats /each group. In CCL<sub>4</sub> group, 8 rats died. In the treatment groups 2 rats died and the extreme values are omitted giving 10 rats used for statistical analysis.

### Liver function and cell death

Table 1 shows that CCL<sub>4</sub> significantly increased serum activities of ALT, AST, ALP and LDH as compared to control ( $p < 0.05$ ).

Aminoguanidine and silymarin each alone caused significant ( $p < 0.05$ ) decrease in the elevated activities of ALT, AST, ALP and LDH when compared to CCL<sub>4</sub>-treated rats. Their combination also showed

significant ( $p < 0.05$ ) decreases in the serum activities of ALT, AST, ALP and LDH when compared to CCL<sub>4</sub>-treated group (Table 2).

- **Oxidative stress markers:** Table 1 also shows that CCL<sub>4</sub> caused almost (71.47%,  $p < 0.05$ ) depletion of liver GSH content as compared to control rats. While GSH content was significantly increased in silymarin pretreated rats ( $p < 0.05$ ), AG ( $p < 0.05$ ) and combination group was more potent than each drug alone ( $p < 0.05$ ). Liver MDA content was increased significantly in CCL<sub>4</sub> treated rats ( $p < 0.05$ ) compared to control. Reduction of MDA content in liver was observed in silymarin pretreated rats ( $p < 0.05$ ), AG ( $p < 0.05$ ) and the combination ( $p < 0.05$ ) compared to CCL<sub>4</sub> treated group (Table 2).
- **Serum nitric oxide:** CCL<sub>4</sub> increased NO production ( $p < 0.05$ ) compared to control group. Both silymarin, AG and their combination inhibited CCL<sub>4</sub>-induced NO production (Tables 1 and 2).

**Table 1.** Effects of CCL<sub>4</sub> injection on serum activity of AST, ALT, ALP, LDH, levels of NO & TNF $\alpha$  and hepatic MDA, GSH and collagen fiber % in normal rats.

Parameter	Control	CCl <sub>4</sub>
ALT(U/L)	23.9 $\pm$ 0.26	80.76* $\pm$ 2.56
AST(U/L)	30.29 $\pm$ 0.8	170.24* $\pm$ 5.18
ALP (U/L)	25.57 $\pm$ 0.96	172.98* $\pm$ 8.6
LDH (U/L)	103.98 $\pm$ 8.76	250.41* $\pm$ 11.32
NO ( $\mu$ mol/L)	19.26 $\pm$ 1.02	70.5* $\pm$ 4.06
Collagen fiber (%)	79.75 $\pm$ 3.9	700.99* $\pm$ 44.64
TNF $\alpha$ (pg/mL)	28.51 $\pm$ 1.51	187.8* $\pm$ 3.93
Liver MDA (nmol/g.tissue)	17.25 $\pm$ 0.86	60*.55 $\pm$ 2.46
Liver GSH (nmol/g.tissue)	75.72 $\pm$ 2.88	21.6* $\pm$ 1.35

Results are expressed as mean  $\pm$  SD and (\*) significant difference compared to control group at  $p < 0.05$ . n = 10.

**Table 2.** Effects of Aminoguanidine, Silymarin and their combination on serum activity of AST, ALT, ALP, LDH, levels of NO & TNF $\alpha$  and hepatic MDA, GSH and collagen fiber % in CCL<sub>4</sub> treated rats.

Parameter	CCl <sub>4</sub>	CCl <sub>4</sub> + AG	CCl <sub>4</sub> + Silymarin	CCl <sub>4</sub> +AG+Silymarin
ALT(U/L)	80.76 $\pm$ 2.56	43.92# $\pm$ 0.92	46.04# $\pm$ 0.83	44.75# $\pm$ 1.87
AST(U/L)	170.24 $\pm$ 5.18	104.32# $\pm$ 5.38	94.28# $\pm$ 2.67	113.35a# $\pm$ 4.93
ALP (U/L)	172.98 $\pm$ 8.6	76.97# $\pm$ 4.61	85.58# $\pm$ 7.1	117.29ab# $\pm$ 4.82
LDH (U/L)	250.41 $\pm$ 11.32	137.76# $\pm$ 8.91	150.55# $\pm$ 10.72	205.18ab# $\pm$ 9.27
NO ( $\mu$ mol/L)	70.5 $\pm$ 4.06	46.87# $\pm$ 2.23	53.18# $\pm$ 2.83	31.5ab# $\pm$ 0.51
Collagen fiber (%)	700.99 $\pm$ 44.64	486.05# $\pm$ 15.8	596.62# $\pm$ 57.2	289.42ab# $\pm$ 16.43
TNF $\alpha$ (pg/ml)	187.8 $\pm$ 3.93	117# $\pm$ 3.83	106.02# $\pm$ 6.03	69.23ab# $\pm$ 6.46
Liver MDA (nmol/g.tissue)	60.55 $\pm$ 2.46	34.34# $\pm$ 1.58	27.25b# $\pm$ 1.48	24.77b# $\pm$ 1.02
Liver GSH (nmol/g.tissue)	21.6 $\pm$ 1.35	37.58# $\pm$ 2.34	37.08# $\pm$ 3.04	42.96# $\pm$ 2.62

Results are expressed as mean  $\pm$  SD (#) significant difference compared to CCL<sub>4</sub> treated group and (a, b) significant difference from Silymarin and Aminoguanidine respectively at  $p < 0.05$ . n = 10.

The inhibitory effect of silymarin ( $p < 0.05$ ) was less than that of AG ( $p < 0.05$ ). While, the combination of both drugs ( $p < 0.05$ ) was more potent than each drug alone.

### Serum TNF $\alpha$

CCL<sub>4</sub> caused a significant increase in serum TNF $\alpha$  ( $p < 0.05$ ) compared to control group (Table 1). This increase was inhibited by prophylactic administration of silymarin ( $p < 0.05$ ), AG ( $p < 0.05$ ) and their combination ( $p < 0.05$ ) which was more potent than each drug alone (Table 2).

### Liver collagen fiber percent

Liver collagen fiber content was increased significantly in CCL<sub>4</sub> treated rats ( $p < 0.05$ ) compared to control rats (Table 1). Pretreatment of CCL<sub>4</sub> treated rats with AG or silymarin caused a significant reduction of collagen fiber % ( $p < 0.05$ ). The administration of AG together with silymarin resulted in greater decrease in collagen fiber % ( $p < 0.05$ ) compared to silymarin alone (Table 2).

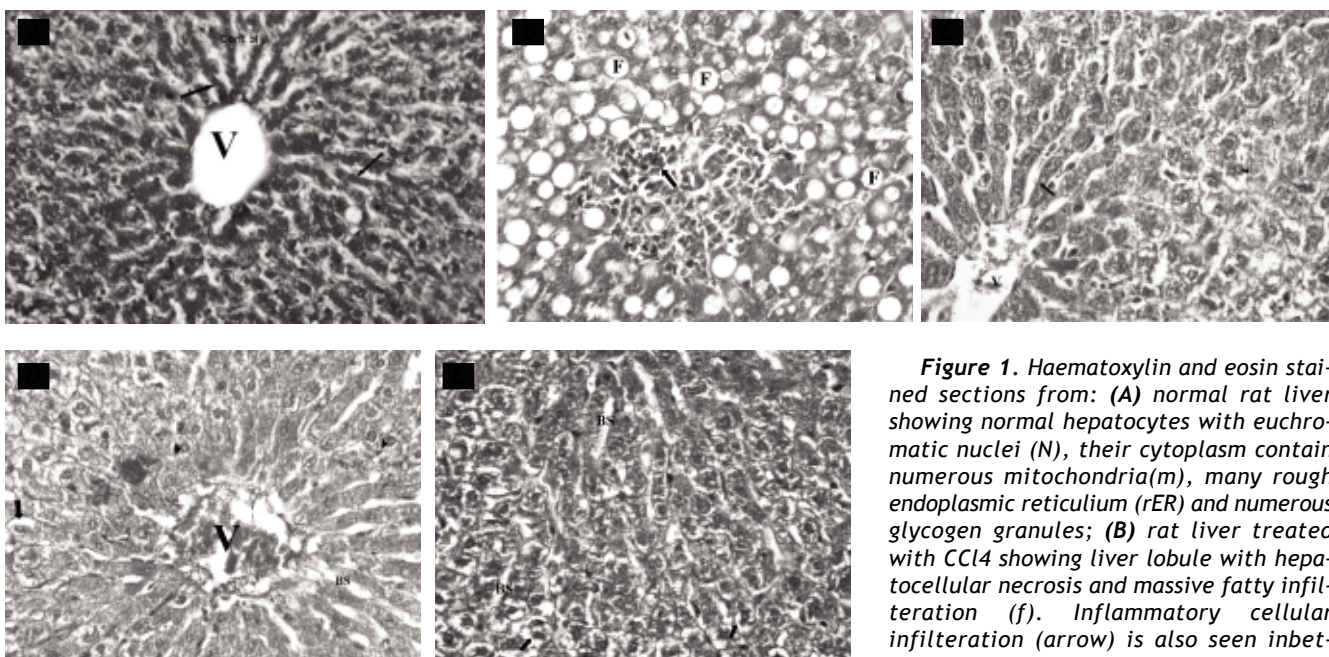
### Liver histopathological examination

Liver sections from the control group rats showed normal hepatocytes, sinusoids and no fibrosis. While liver sections from CCL<sub>4</sub> injected rats showed hepatocellular necrosis, massive fatty and inflammatory cellular infiltration in between degenerated hepatocytes.

Examination of hepatocytes of CCL<sub>4</sub> injected rats under electron microscope showed dark heterochromatic nuclei; cytoplasm contained fragmented rER, dispersed glycogen granules and many electron lucent areas of the cytoplasm. Blood sinusoids were congested and filled with RBC<sub>s</sub> (Figures 1A, 2A, 1B and 2B).

Aminoguanidine treated rats revealed marked reduction in the hepatic lesions. Most of the hepatocytes were more or less similar to those of control group except mild dilatation of the sinusoids and few hepatocytes were vacuolated at the periphery of the lobules (Figures 1C and 2C).

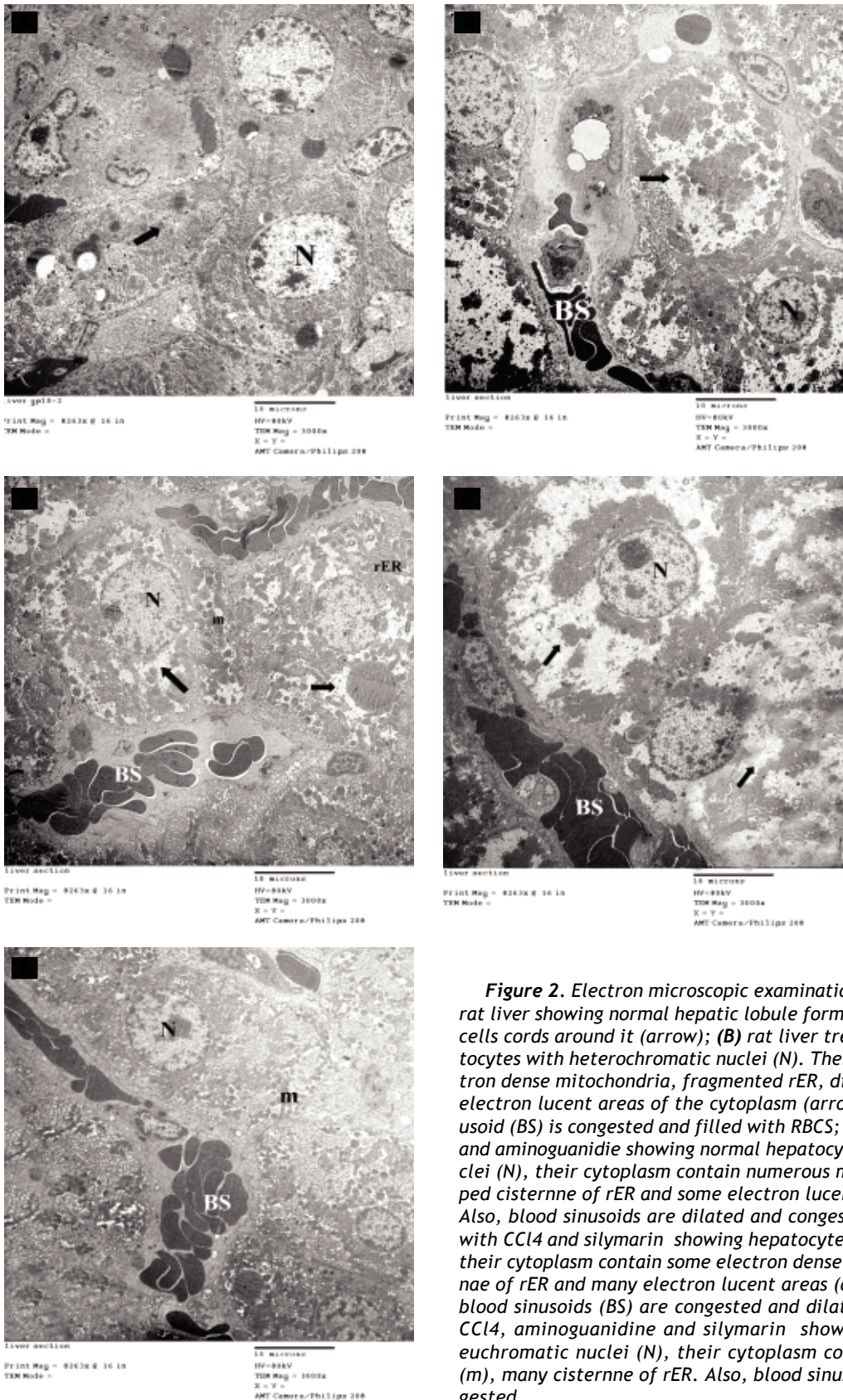
Silymarin treated rats showed liver lobule formed of congested central vein surrounded by normal hepatic cells at the center and some hepatic cells with vacuolated cytoplasm at the periphery of the lobule.



**Figure 1.** Haematoxylin and eosin stained sections from: (A) normal rat liver showing normal hepatocytes with euchromatic nuclei (N), their cytoplasm contain numerous mitochondria(m), many rough endoplasmic reticulum (rER) and numerous glycogen granules; (B) rat liver treated with CCL<sub>4</sub> showing liver lobule with hepatocellular necrosis and massive fatty infiltration (f). Inflammatory cellular infiltration (arrow) is also seen in between degenerated hepatocytes; (C) rat liver treated with CCL<sub>4</sub> and aminoguanidine showing liver lobule formed of central vein (v) and surrounded with normal liver cells cords (arrow). Each liver cell contains pale central rounded nuclei and acidophilic cytoplasm (arrow head); (D) rat liver treated with CCL<sub>4</sub> and silymarin showing liver lobule formed of dilated congested central vein (v) surrounded by normal hepatic cells at the center. Some hepatic cells with vacuolated cytoplasm (arrow) and pyknotic nuclei (arrow head) were observed at the periphery of the lobule. Some blood sinusoids (BS) were dilated; (E) rat liver treated with CCL<sub>4</sub> aminoguanidine and silymarin showing normal liver cell cords (arrow head). They contain central rounded nuclei.

ver treated with CCL<sub>4</sub> and aminoguanidine showing liver lobule formed of central vein (v) and surrounded with normal liver cells cords (arrow). Each liver cell contains pale central rounded nuclei and acidophilic cytoplasm (arrow head); (D) rat liver treated with CCL<sub>4</sub> and silymarin showing liver lobule formed of dilated congested central vein (v) surrounded by normal hepatic cells at the center. Some hepatic cells with vacuolated cytoplasm (arrow) and pyknotic nuclei (arrow head) were observed at the periphery of the lobule. Some blood sinusoids (BS) were dilated; (E) rat liver treated with CCL<sub>4</sub> aminoguanidine and silymarin showing normal liver cell cords (arrow head). They contain central rounded nuclei.





**Figure 2.** Electron microscopic examination of sections from: (A) normal rat liver showing normal hepatic lobule formed of central vein (v) and liver cells cords around it (arrow); (B) rat liver treated with CCl<sub>4</sub> showing hepatocytes with heterochromatic nuclei (N). Their cytoplasm contains few electron dense mitochondria, fragmented rER, dispersed glycogen granules and electron lucent areas of the cytoplasm (arrow). Notice that the blood sinusoid (BS) is congested and filled with RBCs; (C) rat liver treated with CCl<sub>4</sub> and aminoguanidine showing normal hepatocytes formed of euchromatic nuclei (N), their cytoplasm contains numerous mitochondria (m), well developed cisternae of rER and some electron lucent areas of cytoplasm (arrow). Also, blood sinusoids are dilated and congested (BS); (D) rat liver treated with CCl<sub>4</sub> and silymarin showing hepatocytes with euchromatic nuclei (N), their cytoplasm contains some electron dense mitochondria (m), few cisternae of rER and many electron lucent areas (arrow) of the cytoplasm. Also, blood sinusoids (BS) are congested and dilated; (E) rat liver treated with CCl<sub>4</sub>, aminoguanidine and silymarin showing normal hepatocytes with euchromatic nuclei (N), their cytoplasm contains numerous mitochondria (m), many cisternae of rER. Also, blood sinusoids (BS) are dilated and congested.

Hepatocytes had euchromatic nuclei, their cytoplasm contain some mitochondria, few cisternne of rER and electron lucent areas of cytoplasm (Figures 1D and 2D).

Silymarin and AG combination treated rats showed most of liver cells preserved normal structure. However, some liver cells appear vacuolated. Normal hepatocytes with euchromatic nuclei, their cytoplasm contain numerous mitochondria, many cisternne of rER and few cisternne of sER were shown (Figures 1E and 2E).

## DISCUSSION

Fibrosis is both a sign of liver damage and a potential contributor to liver failure via progressive cirrhosis of the liver.<sup>28</sup>

In this study, CCL<sub>4</sub> caused a significant elevation of serum AST, ALT, ALP and LDH activities. The altered activities of these enzymes in CCL<sub>4</sub> treated rats corresponded to the extensive liver damage. The increased activities of ALT, LDH and AST may be attributed to the damaged structural integrity of the liver, because these are cytoplasmic in location and are released into circulation after cellular damage.<sup>32</sup> This damage was further confirmed by light microscopical examination which showed enlargement of the liver, hepatocellular necrosis and massive fatty infiltration. In addition, the electron microscopic examination showed that hepatocytes with dark heterochromatic (inactive) nuclei; their cytoplasm showed fragmentation of rER, dispersed glycogen granules and appearance of many electron lucent areas of the cytoplasm. These alterations may be due to toxic influence of CCL<sub>4</sub> metabolites which injured multiple protein systems including those present in rER and mitochondria. Moreover, reactive oxygen species caused oxidation of cellular proteins and extensive mitochondrial DNA damage thus impaired mitochondrial synthesis by the liver cells.<sup>33</sup> Blood sinusoids were congested and filled with RBC<sub>s</sub>. The observed electron-lucent areas of the cytoplasm may be lipid droplets.

Previous studies demonstrated visible accumulation of lipid and increased percentage of sER which were accompanied by elevated serum ALT and glutathione peroxidase. Glutathione peroxidase is responsible for reduction of lipid hydroperoxides to their corresponding alcohols and to reduce hydrogen peroxide to water in the cells.<sup>34-36</sup>

Hepatotoxicity of CCL<sub>4</sub> is thought to involve two phases.<sup>37</sup> In the first phase, CCL<sub>4</sub> is metabolized by cytochrome P450 in hepatocytes, giving rise to highly

reactive trichloromethyl radicals in the endoplasmic reticulum of kupffer cells and hepatocytes. This radical forms trichloromethyl peroxy radical in the presence of oxygen. These free radicals are unstable and immediately react with the membrane components initiating a chain reaction that leads to lipid peroxidation (LPO).<sup>32</sup>

Results of the current study demonstrated that in CCL<sub>4</sub> treated rats there was a significant elevation in MDA content of the liver tissue. This enhanced lipid peroxidation leads to tissue damage and failure of antioxidant defense mechanisms.<sup>38</sup> A significant reduction in liver GSH in CCL<sub>4</sub> treated rats was also observed in the present study. It may be due to enhanced substrate utilization by glutathione peroxidase, as there is a direct correlation between GSH depletion and enhanced lipid peroxidation.<sup>39</sup>

The second phase of CCL<sub>4</sub> hepatotoxicity involved the inflammatory responses which play an important role. Some hepatic cells including Kupffer cells, hepatic stellate cells (HSCs) and sinusoidal endothelial cells are activated to secrete cytokines which mediate liver fibrogenesis.<sup>40</sup>

Tumor-necrosis factor TNF- $\alpha$  and interleukin (IL)-6 are considered the major hepatotoxicity mediators in liver injury.<sup>41</sup> When an inflammatory reaction occurs, TNF- $\alpha$  is expressed by both infiltrating inflammatory cells such as macrophages in blood and hepatocytes in case of liver injury.

The present study showed that serum TNF- $\alpha$  level in CCL<sub>4</sub> treated rats was significantly elevated. TNF- $\alpha$  caused overproduction of nitric oxide in liver.<sup>42</sup> Nitric oxide is known to react with superoxide radical, forming peroxynitrite, an even more potent oxidizing agent.<sup>5</sup> Peroxynitrite can react directly with sulfhydryl residues in cell membrane as well as with DNA leading to lipid peroxidation and cytotoxicity.<sup>6,7</sup>

This study illustrated that there is an elevation in serum nitric oxide level in CCL<sub>4</sub> treated rats. This may be due to depletion of glutathione that may weaken cellular antioxidant defense to such a point that NO produced by iNOS may cause tissue injury.<sup>43</sup>

The present study demonstrated that there is a significant increase in collagen fiber percent of liver tissue after IP injection of CCL<sub>4</sub>. It has been shown that hepatic fibrosis largely resulted from the disorder in the homeostasis of synthesis, deposition, degeneration and absorption of collagens. In hepatic fibrosis, myofibroblasts characteristically assume the ability to remodel extracellular matrix (ECM) via their production of ECM proteins in liver.<sup>44</sup> In liver cirrhosis, the proliferation of myofi-



broblasts is associated with inappropriate remodeling of ECM that generates scar tissue which leads to structural and functional disorders in normal tissue.<sup>45</sup>

Results of the current study demonstrated that aminoguanidine; a nucleophilic hydrazine compound structurally similar to L-arginine and acts as specific iNOS inhibitor<sup>10</sup> caused a significant reduction in liver enzymes and LDH activities in CCL<sub>4</sub> treated rats. Moreover, histopathological examination revealed marked reduction in the hepatic lesions.

This study demonstrated that aminoguanidine caused a significant reduction in serum NO level. It was found that plasma concentration of nitrates/nitrites, measured as an index of NO production, were significantly increased in the Fibrotic animals in the basal period and decreased with AG to normal control levels. INOS enzyme is expressed in hepatocytes and inflammatory cells during the development of cirrhosis. Therefore, inhibition of iNOS expression may have an important role in both cirrhosis and endotoxaemia.<sup>8</sup>

In the present study, there was a significant reduction in liver MDA content and a significant elevation in liver GSH content in rats pretreated with aminoguanidine. This suggested an alternative mechanism of AG protection via decreasing the metabolic activation of CC14 by direct inhibition of P450E1, the isoenzyme most effective in the activation of CC14.<sup>12</sup> Thus decreasing the free radicals release that causes lipid peroxidation.<sup>46</sup>

It should also be noted that aminoguanidine not only act as inhibitor of nitric oxide synthase but also a peroxynitrite scavenger.<sup>47</sup> These observations also indicate that the protective effect of AG against the enzyme leakage seems to be through the liver cell membrane permeability restoration and is independent of any effects on liver GSH contents.<sup>48</sup>

Results of the present study demonstrated that silymarin caused a significant reduction in AST, ALT, ALP and LDH activities in CCL<sub>4</sub> treated rats.

In addition, histopathological examination of the liver of CCL<sub>4</sub> treated rats pretreated with silymarin showed an improvement in hepatic cell ultrastructure.

The cytoprotective effects of silymarin are mainly attributable to its antioxidant and free radical scavenging properties. Silymarin can enter inside the nucleus and act on RNA polymerase enzymes resulting in increased ribosomal formation. This in turn hastens protein and DNA synthesis.<sup>49,50</sup> This action has important therapeutic implications in the repair

of damaged hepatocytes and restoration of normal functions of liver. Silymarin can also interact directly with cell membrane components to prevent any abnormalities in the content of lipid fraction responsible for maintaining normal fluidity.<sup>51</sup>

The present study showed that silymarin caused a significant decrease in liver MDA content and a significant increase in liver GSH content in Fibrotic rats. This may be attributed to direct free radical scavenging properties of silymarin.

Furthermore, silymarin caused a significant reduction in serum nitrite level in Fibrotic rats. It was found that silymarin inhibited the production of O<sub>2</sub><sup>-</sup> and NO in a dose-dependent manner.<sup>52</sup>

This study demonstrated that silymarin caused a significant reduction in serum TNF $\alpha$  level. This anti-inflammatory effect of silymarin on hepatic tissue is based on multiple activities including mast cell stabilization, inhibition of neutrophil migration, inhibition of kupffer cell activation and inhibition of the production of leukotrienes, cytokines and prostaglandin.<sup>53,54</sup> In addition, it inhibits hepatic stellate cell proliferation and transformation.<sup>55</sup>

In the present study, there was a significant decrease in the content of collagen fibers only by 15% in liver tissue of Fibrotic rats treated with silymarin. This protection can be attributed to antioxidant and membrane-stabilizing actions.<sup>52</sup>

The results obtained in the present investigation demonstrated for the first time to our knowledge that silymarin and AG combination caused a significant reduction in collagen fiber content in liver by 58% in Fibrotic rats, these reduction is better than the administration of each drug alone. As this combination may suppress the activation of HSC<sub>s</sub> due to the potent antifibrotic effect of both AG and silymarin when used together.

This is may be mediated by the reduction of liver MDA content, serum nitric oxide level and the increase in GSH content which were also better than silymarin alone. The antioxidant effects of both drugs can inhibit HSC activation, protect hepatocytes from undergoing apoptosis and attenuate liver fibrosis.<sup>56</sup>

In addition, the combination caused a significant reduction in serum TNF $\alpha$  level, which is better than each drug alone. As both AG and silymarin has anti-inflammatory properties that potentiate the effect of each other.

In the present investigation, silymarin and AG combination caused a significant reduction in serum AST and LDH activities, which were lesser than each drug alone. Moreover, the combination of the

two drugs produced a significant reduction in serum ALT activity, which is similar to the effect of silymarin. These biochemical findings are confirmed by histopathological examination.

In summary, the current data showed that aminoguanidine has protective effect against CCL4 induced hepatotoxicity via its iNOS inhibition and antioxidant effect. In addition, the combination of AG with silymarin has more potent hepatoprotective effect than each drug alone suggesting beneficial effect against liver fibrosis.

## REFERENCES

- Guyton AC, Hall JE. The liver as an organ. In: Guyton AC, Hall JE (eds.). *Textbook of Medical Physiology*. 11th Ed. Philadelphia: Saunders Elsevier; 2006, p. 859-64.
- Friedman SL. Hepatic fibrosis. In: Schiff ER, Sorrell MF, Maddrey WC (eds.). *Schiff's Diseases of the Liver*. 9th Ed. Philadelphia. Lippincott Williams & Wilkins; 2003. p: 409-27.
- McCafferty D M, Mudgett J S, Swain M G, Kubes P. Inducible nitric oxide synthase plays a critical role in resolving intestinal inflammation. *Gastroenterology* 1997; 112: 1022-7.
- Hortelano S, López-Collazo E, Bosc L. Protective effect of cyclosporin A and FK506 from nitric oxide-dependent apoptosis in activated macrophages. *Br J Pharmacol* 1999; 126: 1139-46.
- Ischiropoulos H, Zhu L, Beckman J S. Peroxynitrite formation from macrophage-derived nitric oxide. *Arch Biochem Biophys* 1992; 298: 446-51.
- Radi R, Beckman JS, Bush KM, Freeman B. Peroxynitrite Oxidation of Sulfhydryls: the cytotoxic potential of superoxide and nitric oxide. *J Biol Chem* 1991; 266(7): 4244-50.
- Ischiropoulos H, Zhu L, Chen J, Tsai M, Martin JC, Smith CD, Beckman J S. Peroxynitrite-mediated tyrosine nitration catalyzed by superoxide dismutase. *Arch Biochem Biophys* 1992; 298: 431-7.
- Heller J, Sogni P, Barriere E, et al. Effects of lipopolysaccharide on TNF- $\alpha$  production, hepatic NOS<sub>2</sub> activity, and hepatic toxicity in rats with cirrhosis. *J Hepatol* 2000; 33: 376-81.
- Liu S H, Tzeng H P, Kuo ML, Lin-Shiau SY. Inhibition of inducible nitric oxide synthase by  $\beta$ -lapachone in rat alveolar macrophages and aorta. *Br J Pharmacol* 1999; 126: 746-50.
- Kang DG, Kim JW, Lee J. Effects of nitric oxide synthesis inhibition on the Na, K-ATPase activity in the kidney. *Pharmacol Res* 2000; 41: 123-7.
- Giri SN, Biring I, Nguyen T. Abrogation of bleomycin-induced lung fibrosis by nitric oxide synthase inhibitor, aminoguanidine in mice. *Nitric Oxide* 2002; 7: 109-18.
- Doglu-Abbasoglu S, Balkan J, Cevikbas U, Aykac-Toker G, Uysal M. Aminoguanidine, an inducible nitric oxide synthase inhibitor, plus N- acetylcysteine treatment reduce the lipopolysaccharide-augmented hepatotoxicity in rats with cirrhosis. *Human & Experimental Toxicology* 2002; 21: 359-64.
- Valenzuela A, Garrido A. Biochemical bases of the pharmacological action of the flavonoid silymarin and of its structural isomer silibinin. *Biol Res* 1994; 27: 105-12.
- Morazzoni P, Bombardelli E. Silybum marianum (Carduus marianus). *Fitoterapia* 1995; 10: 3-42.
- Halim AB, El-Ahmady O, Hassab-Allah S, Abdel-Galil F, Hafez Y, Darwish A. Biochemical effect of antioxidants on lipids and liver function in experimentally induced liver damage. *Ann Clin Biochem* 1997; 34: 656-63.
- Farghali H, Kamenikova L, Hynie S, Kmonickova E. Silymarin effects on intracellular calcium and cytotoxicity: a study in perfused rat hepatocytes after oxidative stress injury. *Pharmacol Res* 2002; 41: 231-7.
- Lieber CS, Leo MA, Cao Q, Ren C, DeCarli LM. Silymarin retards the progression of alcohol-induced hepatic fibrosis in baboons. *J Clin Gastroenterol* 2003; 37: 336-9.
- Riely V. Adaptation of orbital bleeding technique to rapid serial blood studies. *Proc Exp Biol Med* 1960; 104: 751-4. In: Grad SC, Chenglis CP (eds.). *Animal models in toxicology*. New York; Marcel Dekker; 1992; pp. 21-164..
- Sorg DA, Buckner B. A simple method of obtaining venous blood from small laboratory animals. *Proc Soc Exp Biol Med* 1964; 115: 1131-1132. In: *Animal models in toxicology* New York (Grad SC and Chenglis CP eds.). Marcel Dekker; 1992, pp. 21-164.
- Reitman S, Frankel S. A colorimetric method for the determination of serum glutamic oxalacetic and glutamic pyruvic transaminases. *Am J Clin Pathol* 1957; 28: 56-63.
- Young DS, Pestaner LC, Gibberman V. Effect of drug on clinical laboratory tests. *Clin Chem* 1975; 21: D431-D432.
- Beutler E, Durgun O, Kelly B M. Improved method for the determination of blood glutathione. *J Lab Clin Med* 1963; 51: 882-8.
- Satoh K. Serum lipid peroxide in cerebrovascular disorders determined by a new colorimetric method. *Clinica. Chimica Acta* 1978; 90: 37-43.
- Vassault A. Lactate dehydrogenase. UV-method with pyruvate and NADH. 1982. In: Bergmeyer J, Grabl M, (eds.). *Methods of Enzymatic Analysis*. Deerfield Beach Florida: Verlag-Chemie; 1983, p. 119-26.
- Gogos, et al. 1982.
- Crookham JN, Dapson RW. Hazardous chemicals in the histopathology laboratory. In. *Regulations, Risks, Handling & Disposal*. 1st Ed. An-atech, Battle Creek, MI. 1991; 94:
- Montgomery HAC, Dymock JF. The determination of nitrate in water. *Analyst* 1961; 86: 414-16.
- Yang L, et al. Clinical pathological study on effect of qian-ggan capsule in treating patients of chronic hepatitis B and liver cirrhosis. *Chinese Journal of Integrated Traditional and Western Medicine* 2002; 8: 90-4.
- Ferencikova R, Cervinkove Z, Drahota Z. Hepatotoxic effect of D-galactosamine and protective role of lipid emulsion. *Physiol Res* 2003; 52: 73-8.
- Chang ML, Yeh CT, Chang PY, Jeng-Chang C. Comparison of murine cirrhosis models induced by hepatotoxin administration and common bile duct ligation. *World J. Gastroenterol* 2005; 11: 4167-72.
- Johnson DE, Kroening C. Mechanism of early Carbon tetrachloride toxicity in cultured rat hepatocytes. *Pharmacol Toxicol* 2006; 83: 231-9.
- Recknagel RO, Glende EA, Dolak JA, Waller RL. Mechanisms of carbon tetrachloride toxicity. *Pharmacol Therapeutics* 1989; 43: 139-54.
- Nevin KG, Vijayammal PL. Effect of Aerva Lanata against hepatotoxicity of carbon tetrachloride in rats. *Environmental toxicology and pharmacology* 2005; 20: 471-7.



34. Prasada RSK, Hariharu MK. Biochemical methods of studying hepatotoxicity. In hepatotoxicology. Boca Raton; CRC Press; 1991, p. 241-326.
35. Sengottuvelu S, Duraisami S, Nandhakumar J, Duraisami R, Vasudevan M. Hepatoprotective activity of *Camellia sinensis* and its Possible Mechanism of Action. *IJPT* 2008; 7: 9-14.
36. Chen L, Pan D, Zhou J, Jiang YZ. Protective effect of selenium-enriched lactobacillus on CCl<sub>4</sub>-induced liver injury in mice and its possible mechanisms. *World J Gastroenterology* 2005; 11: 5795-800.
37. Shi J, Aisaki K, Ikawa Y, Wake K. Evidence of hepatocyte apoptosis in rat liver after the administration of carbon tetrachloride. *Am J Pathol* 2007; 153: 515-25.
38. Ashok SHK, Somayaji SV, Baiyya KL. Hepatoprotective effects of Ginkgo biloba against carbon tetrachloride induced hepatic injury in rats. *Ind J Pharmacol* 2001; 33: 260-6.
39. Al-Shabanah OA, Alam K, Nagi MN, Al-Rikabi AC, Al-Bekairi AM. Protective effect of aminoguanidine, a nitric oxide synthase inhibitor, against carbon tetrachloride induced hepatotoxicity in mice. *Life Sci* 2000; 66: 265-70.
40. Friedman SL. Cytokines and fibrogenesis. *Semin Liver Dis* 1999; 19: 129-40.
41. Kovalovich K, DeAngelis RA, Li W, Furth E, Ciliberto G, Taub R. Increased toxin-induced liver injury and fibrosis in interleukin-6-deficient mice. *Hepatology* 2000; 31: 149-59.
42. Chamulitrat W, Blazka ME, Jordan SJ, Luster MI, Mason PR. Tumor necrosis factor- $\alpha$  and nitric oxide production in endotoxin-primed rats administered carbon tetrachloride. *Life Sci* 1995; 24: 2273-80.
43. Korda M, Yaroshenko TY. The effect of iNOS inhibitor N-(3-(Aminomethyl) benzyl) acetamidine on the hepatotoxicity of allyl alcohol. *Med Chem* 2004; 6: 114-19.
44. Powell DW. Myofibroblasts: Paracrine cells important in health and disease. *Trans Am Clin Climatol Assoc* 2000; 111: 271-92.
45. Friedman S L. Molecular regulation of hepatic fibrosis, an integrated cellular response to tissue injury. *J Biol Chem* 2000; 275: 2247-50.
46. Mustafa A, Gado AM, Al-Shabanah OA, Al-Bekairi AM. Protective effect of aminoguanidine against paraquat-induced oxidative stress in the lung of mice. *Comp Biochem Physiol Part C* 2002; 132: 391-7.
47. Szabo C, Ferrer-Sueta G, Zingarelli B, Southan GJ, Takashi H, Miho G, Hiroyuki S, et al. Yellow tea is more potent than other types of tea in suppressing liver toxicity induced by carbon tetrachloride in rats. *Phytother Res* 2007; 21: 668-70.
48. Raza M, Ahmad M, Gado A, Al-Shabanah O A. A comparison of hepatoprotective activities of aminoguanidine and N-acetylcysteine in rat against the toxic damage induced by azathioprine. *Comp Biochim Physiol Part C* 2003; 134: 451-6.
49. Sonnenbichler J, Goldberg M, Hane L, et al. Stimulatory effect of silibinin on the DNA synthesis in partially hepatectomized rat livers: non-response in hepatoma and other malignant cell lines. *Biochem Pharmacol* 1986; 35: 538-41.
50. Song Z, Deaciuc I, Song M, Lee D Y-W, Liu Y, Ji X, McClain C. Silymarin Protects Against Acute Ethanol-Induced Hepatotoxicity in Mice. *Alcohol Clin Exp Res* 2006; 30: 407-13.
51. Muriel P, Mourelle M. Prevention by silymarin of membrane Alterations in acute CCl<sub>4</sub> liver damage. *J Appl Toxicol* 1990; 10: 275-84.
52. Dehmow C, Erhard J, De Groot H. Inhibition of Kupffer cell functions as an explanation for the hepatoprotective properties of silibinin. *Hepatology* 1996; 23: 749-54.
53. Malih F, Hosseini-Tabatabaei A, Esmaily H, Khorasani R, Baeeri M, Abdollahi M. Improvement of inflammatory and toxic stress biomarkers by silymarin in a murine model of type one diabetes mellitus. *Central European Journal of Biology* 2009; 4: 369-80.
54. Jeong DH, Lee GP, Jeong WI, Do SH, Yang HI, Yuan DW, Park HY, Kim KJ, Jeong KS. Alterations of mast cells and TGF- $\beta$ 1 on the silymarin treatment for CCL<sub>4</sub>-induced hepatic fibrosis. *World Journal of Gastroenterology* 2005; 28: 1141-8.
55. Fuchs E C, Weyhenmeyer R, Weiner O H. (1997): Effects of silibinin and of a synthetic analogue on isolated rat hepatic stellate cells and myofibroblasts. *Arzneimittelforschung* 1997; 47: 1383-7.
56. Bataller R, Brenner DA. Liver fibrosis. *J Clin Invest* 2005; 115: 209-18.