

Cholestasis as the initial presentation of relapsing polychondritis

Maria da Graça Ferronato,* Leonardo Jönck Staub,*
Renata Cristina Teixeira Pinto Viana,* Lígia da Rosa,* Maria Beatriz Cacesse Shiozawa,**
Janaína L. Narciso-Schiavon,* Esther Buzaglo Dantas-Correa,* Leonardo de Lucca Schiavon*

* Division of Gastroenterology, Federal University of Santa Catarina, Florianópolis, Brazil.

**Department of Pathology, Federal University of Santa Catarina, Florianópolis, Brazil.

ABSTRACT

Relapsing polychondritis is an immune-mediated disease associated with inflammation in cartilaginous structures and other tissues throughout the body, particularly the ears, nose, eyes, joints, and respiratory tract. Although association with other conditions is seen in about one-third of the cases, liver involvement is not usually observed in those patients. We described a case of liver involvement in relapsing polychondritis, presenting with a predominantly cholestatic pattern. Other conditions associated with abnormal liver tests were excluded and the patient showed a prompt response to steroid therapy. We discuss the spectrum of the liver involvement in relapsing and review the literature.

Key words. Relapsing polychondritis. Cholestasis. Liver.

INTRODUCTION

Relapsing polychondritis (RPC) is an immune-mediated condition associated with inflammation in cartilaginous structures and other tissues throughout the body, particularly the ears, nose, eyes, joints, and respiratory tract.¹ Other proteoglycan-rich structures, such as the inner ear, eyes, blood vessels, heart, and kidneys may be involved.¹ Although histological changes and nonspecific laboratory findings may be of value, RPC diagnosis remains largely clinical. Empirically derived diagnostic criteria have been used to define relapsing polychondritis.² Even though around 30% of RPC cases are associated with other diseases especially systemic vasculitis or myelodysplastic syndrome,³ liver involvement is not well documented, especially as the first manifestation of RPC.

CASE REPORT

A 48-year-old woman was admitted with a 20 days history of asthenia, loss of appetite and low grade fever. Five days before the admission, she also developed jaundice, choluria, conjunctival hyperemia, eyelid swelling and arthralgia. She had no complaints of abdominal pain or pruritus as well as no past history of alcohol consumption, exposure to hepatotoxic drugs or other comorbidities. On examination, she was jaundiced and had bilateral wrist and ankle arthritis, as well as bilateral conjunctivitis. The liver was palpable 2 cm below the right costal margin, but the spleen was not enlarged. Laboratory evaluation on admission (Table 1) revealed a hematocrit of 27%, platelets 160,000/mm³, total leukocytes 5,200/mm³, total bilirubin 3.2 mg/dL (direct fraction 2.8 mg/dL), aspartate aminotransferase 217 IU/L, alanine aminotransferase 151 IU/L, alkaline phosphatase 343 IU/L, gamma-glutamyl transpeptidase 566 IU/L, and INR 1.05. The erythrocyte sedimentation rate was 120 mm (in the first hour) and the C-reactive protein was 160 mg/L. HIV, hepatitis B and hepatitis C serologies were negative. Antinuclear, anti-smooth muscle and antimitochondrial antibodies were also negative. Patient underwent extensive evaluation for bacterial infection, including blood and urine cultures, transesophageal

Correspondence and reprint request: Dr. Leonardo de Lucca Schiavon
Rua Durval Pires da Cunha
210, 88.051-150-Florianópolis-SC-Brazil
Tel.: (55 48) 3209-6854
E-mail: leo-jf@uol.com.br

Manuscript received: May 09, 2011.

Manuscript accepted: May 21, 2011.

Table 1. Main laboratory findings at admission.

Test	Results	Normal range
Hemoglobin	8.9 mg/dL	12-16 mg/dL
Hematocrit	27%	36-48%
White blood cell count	5,200/mm ³	4,000-11,000/mm ³
Platelets	160,000/mm ³	140,000-450,000/mm ³
Prothrombin time	12.7 s	12-14 s
International normalized ratio (INR)	1.05	0.9-1.2
Total bilirubin	3.2 mg/dL	0.2-1.0 mg/dL
Direct bilirubin	2.8 mg/dL	0.1-0.4 mg/dL
Aspartate aminotransferase	217 IU/L	15-37 IU/L
Alanine aminotransferase	151 IU/L	22-56 IU/L
Gamma-glutamyl transpeptidase	566 IU/L	5-55 IU/L
Alkaline phosphatase	343 IU/L	50-136 IU/L
Albumin	1.9 g/dL	3.5-5.5 g/dL
C-reactive protein	160 mg/L	< 5 mg/L
Erythrocyte sedimentation rate	120 mm/h	< 20 mm/h

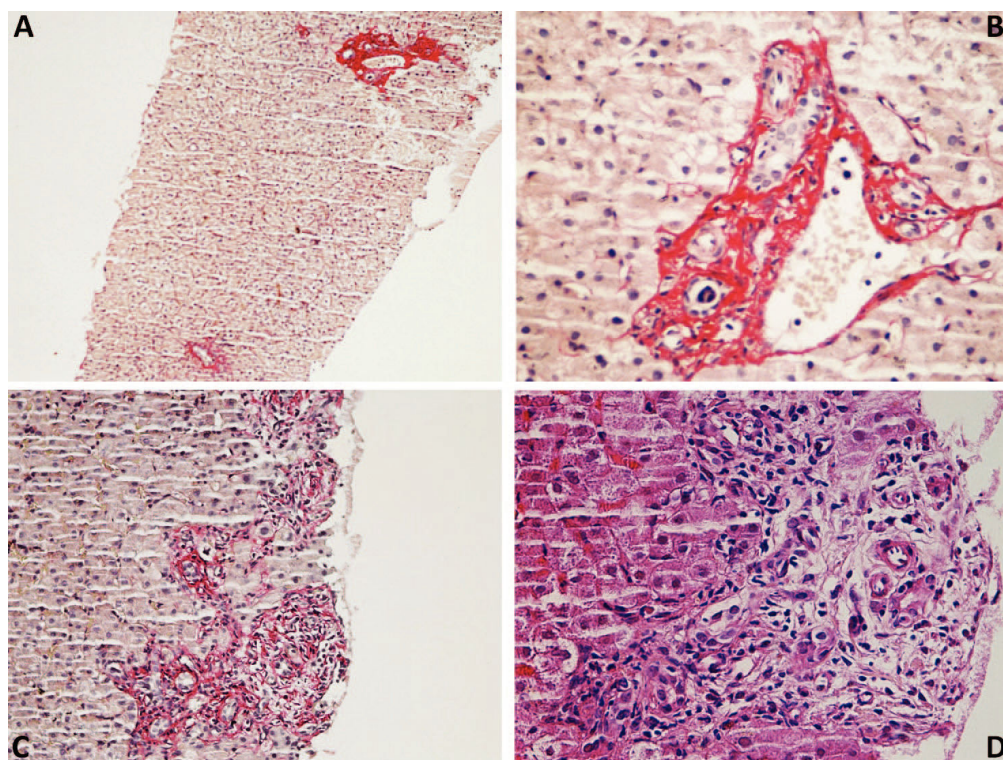


Figure 1. Liver biopsy showing general hepatic architecture well preserved with minimal parenchymal changes (A). Portal tracts showed scarce mononuclear inflammatory cells (B) and changes of biliary pattern with mild fibrosis (C). Figure D exhibit detail of the portal tract showing edema and mild ductular proliferation intermingled with some mononuclear inflammatory cells and scarce neutrophils.

echocardiogram, abdominal and thoracic computerized tomography. No indication of systemic infection was observed and no empiric antibiotics were given. An ultrasonography of the liver and bile ducts was also unremarkable.

Liver biopsy (Figure 1) showed general hepatic architecture well preserved, with minimal parenchymal changes, portal tracts with scarce mononuclear inflammatory cells and changes of biliary pattern with mild fibrosis. These findings were not sufficient

to suggest the diagnosis and there were no histological markers consistent with primary biliary cirrhosis or autoimmune hepatitis.

During the investigation, the patient developed bilateral external ear and nasal cartilage progressive inflammation, hearing impairment, tinnitus and vertigo. Based on the clinical findings, the diagnosis of RPC was made and oral prednisone was started at 1 mg/kg/day. A significant clinical improvement was observed and a complete normalization of amino-

transferase, bilirubin and alkaline phosphatase levels was achieved within 15 days of treatment.

DISCUSSION

A large number of systemic inflammatory disorders can affect the liver, with variable prevalence and intensity.⁴ The recognition of these manifestations is essential in managing these patients, who also have abnormal liver tests commonly as a result of hepatotoxicity by various classes of drugs. In addition, differential diagnosis with other primary liver diseases such as autoimmune hepatitis and primary biliary cirrhosis is important. In this regard, hepatic histological evaluation can provide important information. Nonspecific histological findings have been described in several autoimmune diseases including lupus erythematosus, systemic sclerosis and rheumatoid arthritis.⁴⁻⁵

The liver involvement in RPC is only anecdotally reported. In 1983, Islam, *et al.* described the association between RPC and cryptogenic cirrhosis in a 37-year-old male.⁶ Even though there was histological confirmation of cirrhosis, a more detailed etiologic investigation of the liver disease was lacking. In addition, this report antedated the discovery of hepatitis C virus, recognized over the last few years as a significant cause of liver disease worldwide.⁷ In fact, more recently, the association between RPC, chronic hepatitis C virus infection and mixed cryoglobulemia was reported.⁸ In this case, a 74-year-old woman presented with RPC-related symptoms several months before the diagnosis of hepatitis C and mixed cryoglobulinemia syndrome. Interestingly, suppression of HCV viremia during interferon therapy was associated with remission of RPC, suggesting a role of HCV in RPC pathogenesis in this report.

In the present case, biochemical findings suggested a predominantly cholestatic pattern. A thorough investigation could not identify any alternative explanation for the liver abnormalities found, and a presumptive diagnosis of RPC-related liver injury was made. There was no history of exposure to drugs with recognized association with cholestatic toxic liver injury, and other causes of liver disease have been carefully excluded. An overlap with a pri-

mary cholestatic liver disease has also been considered as an alternative diagnosis, since one case report of the association between RPC, Churg-Strauss vasculitis and PBC has already been described.⁹ However, in the present case, typical features of these disorders such as nonsuppurative destructive cholangitis on liver biopsy and AMA were absent. Similarly, the association with autoimmune hepatitis was considered unlikely in the present case, since no histological or serological evidence of this condition was observed.¹⁰

In summary, RPC is a rare and difficult to diagnose condition, which exhibits a variety of nonspecific manifestations. Although apparently uncommon, liver involvement can be observed in patients with RPC, and may even be the initial manifestation of this disease.

CONFLICTS OF INTEREST

There are no conflicts of interest related to the manuscript. Nothing to report.

REFERENCES

1. Kent PD, Michet CJ Jr, Luthra HS. Relapsing polychondritis. *Curr Opin Rheumatol* 2004; 16: 56-61.
2. McAdam LP, O'Hanlan MA, Bluestone R, Pearson CM. Relapsing polychondritis: prospective study of 23 patients and a review of the literature. *Medicine* 1976; 55: 193-215.
3. Lahmer T, Treiber M, von Werder A, Foerger F, Knopf A, Heemann U, et al. Relapsing polychondritis: An autoimmune disease with many faces. *Autoimmun Rev* 2010; 9: 540-6.
4. Malnick S, Melzer E, Sokolowski N, Basevitz A. The involvement of the liver in systemic diseases. *J Clin Gastroenterol* 2008; 42: 69-80.
5. Youssef WI, Tavill AS. Connective tissue diseases and the liver. *J Clin Gastroenterol* 2002; 35: 345-9.
6. Islam N, Ahmed Z, Alam MN. Cryptogenic cirrhosis in relapsing polychondritis. *Postgrad Med J* 1983; 59: 260-1.
7. Shepard CW, Finelli L, Alter MJ. Global epidemiology of hepatitis C virus infection. *Lancet Infect Dis* 2005; 5: 558-67.
8. Herrera I, Concha R, Molina EG, Schiff ER, Altman RD. Relapsing polychondritis, chronic hepatitis C virus infection, and mixed cryoglobulemia. *Semin Arthritis Rheum* 2004; 33: 388-403.
9. Conn DL, Dickson ER, Carpenter HA. The association of Churg-Strauss vasculitis with temporal artery involvement, primary biliary cirrhosis, and polychondritis in a single patient. *J Rheumatol* 1982; 9: 744-8.
10. Hennes EM, Zeniya M, Czaja AJ, Parés A, Dalekos GN, Krawitt EL, et al. Simplified criteria for the diagnosis of autoimmune hepatitis. *Hepatology* 2008; 48: 169-76.