

Inflammatory myofibroblastic tumor of the liver

Fredy Chablé-Montero,* Arturo Ángeles-Ángeles,* Jorge Albores-Saavedra*

* Department of Pathology, Instituto Nacional de Ciencias Médicas y Nutrición "Salvador Zubirán", Mexico City.

ABSTRACT

Hepatic inflammatory myofibroblastic tumors are uncommon low grade malignant neoplasms. They can be confused clinically and by imaging studies with abscess.

Key words. Inflammatory myofibroblastic tumor, Liver.

CLINICAL CASE

Six days before admission to the hospital this 23 year-old woman developed fever, diaphoresis and right hypochondrium pain. Laboratory studies showed only leukocytosis. An ultrasound and computed tomography revealed an heterogeneous rounded hepatic lesion of 7 cm in greatest dimension (Figure 1A).

The clinical and radiological diagnosis was pyogenic hepatic abscess. The patient received antimicrobial treatment but the high fever persisted. A right hepatic lobectomy was performed. Grossly, a non-encapsulated but well demarcated hepatic tumor with central necrosis of 11 cm in greatest dimension was seen (Figure 1B). Microscopically, the tumor was composed of spindle myofibroblastic cells arranged

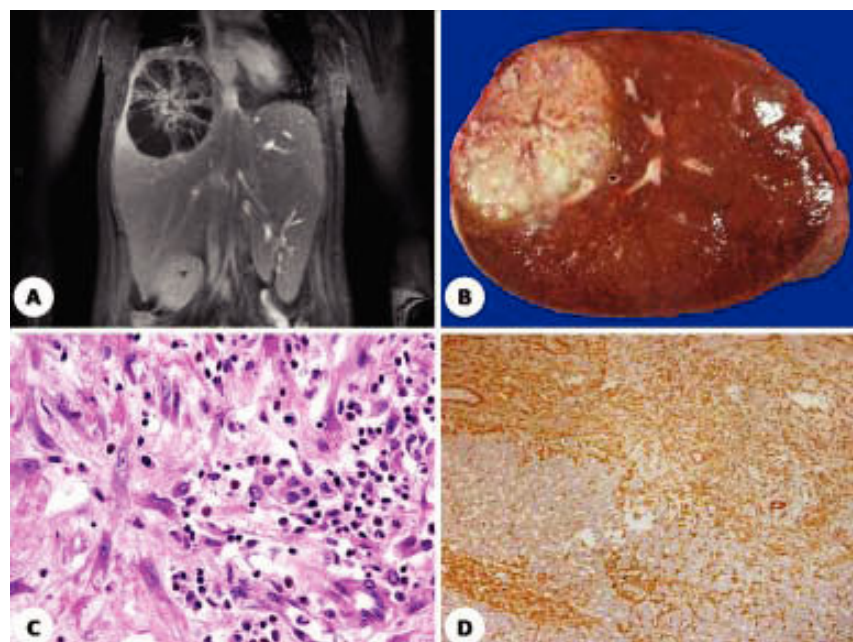


Figure 1. A. A computed tomography of IMT. B. Right hepatic lobectomy of IMT. C. Histologic section of IMT (H&E, x400). D. Diffuse immunoreactivity for smooth muscle actine.

Correspondence and reprint request: Fredy Chablé Montero M.D.
Department of Pathology, Instituto Nacional de Ciencias Médicas y Nutrición "Salvador Zubirán"
Vasco de Quiroga 15, Col. Sección XVI. Tlalpan, México D.F. CP. 14000
E mail: fredy010583@gmail.com

Manuscript received: July 13, 2012.
Manuscript accepted: July 26, 2012.

in fascicles. The neoplastic cells were mixed with numerous leukocytes, lymphocytes and plasma cells (Figure 1C). The myofibroblastic cells were strong and diffusely positive for smooth muscle actine (Figure 1D). Cellular atypia or mitotic figures were not present. The central portions of the tumor showed necrosis and numerous foamy macrophages. The diagnosis of hepatic inflammatory myofibroblastic tumor was made.

DISCUSSION

Inflammatory myofibroblastic tumors (IMT) have been reported in many anatomic sites, including lung, urinary bladder, breast, pancreas, large bowel, prostate, orbit, liver, extrahepatic bile ducts, etc.¹⁻⁴ Hepatic myofibroblastic tumors are exceedingly rare and occur in adult men with a mean age of 56 years.⁴ Its size is variable from 1 to 20 cm. Some of these tumors may simulate abscess because of the abundant inflammatory infiltrate and central necrosis. Inflammatory myofibroblastic tumors recur locally (25%) while others behave as low grade malignant neoplasms that can metastasize (< 5%).³ Some inflammatory myofibroblastic tumors have

been associated with autoimmune pancreatitis and primary sclerosing cholangitis.⁵ In these cases, the IgG4 serum levels are elevated and therefore useful in the diagnosis. Immunohistochemistry for IgG4 usually shows numerous IgG4-positive plasma cells.⁵ In a few reports, inflammatory myofibroblastic tumors have also been associated with Epstein-Barr virus infection.

REFERENCES

1. Albores-Saavedra J, Henson DE, Klimstra DS. Tumors of the gallbladder, extrahepatic bile ducts, and ampulla of Vater. *Atlas of tumor pathology. Armed Forces Institute of Pathology* 2013 [In press].
2. Kawaguchi T, Mochizuki K, Kizu T, et al. Inflammatory pseudotumor of the liver and spleen diagnosed by percutaneous needle biopsy. *World J Gastroenterol* 2012; 18: 90-5.
3. Kovach SJ, Fischer AC, Katzman PJ, Salloum RM, Ettinghausen SE, Madeb R, Koniaris LG. Inflammatory myofibroblastic tumors. *J Surg Oncol* 2006; 94: 385-91.
4. Schnelldorfer T, Chavin KD, Lin A, Lewin DN, Baliga PK. Inflammatory myofibroblastic tumor of the liver. *J Hepatobiliary Pancreat Surg* 2007; 14: 421-3.
5. Zen Y, Fujii T, Sato Y, Masuda S, Nakanuma Y. Pathological classification of hepatic inflammatory pseudotumor with respect to IgG4-related disease. *Mod Pathol* 2007; 20: 884-94.