

### Portal vein aneurysm: is it an incidental finding only?

Sameer Vyas,\* Divyesh Mahajan,\* Manavjeet Singh Sandhu,\* Ajay Duseja,\*\* Niranjan Khandelwal\*

\*Department of Radiodiagnosis, Postgraduate Institute of Medical Education and Research, Chandigarh, India.

\*\*Department of Hepatology, Postgraduate Institute of Medical Education and Research, Chandigarh, India.

#### ABSTRACT

Portal vein aneurysms are uncommon incidental imaging findings. They usually do not require any treatment unless symptomatic. Contrast enhanced CT is the imaging modality of choice for depicting its morphology and extension.

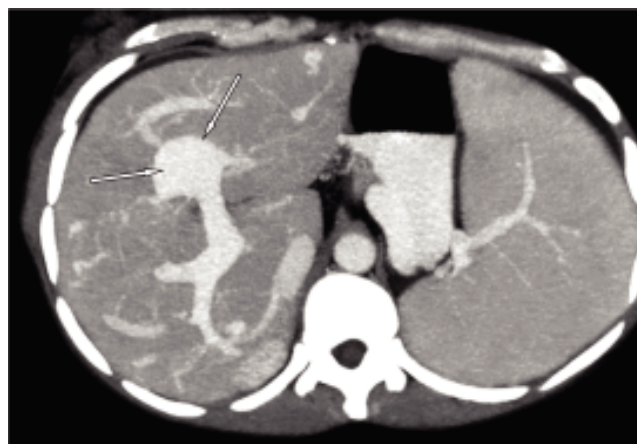**Key words.** Portal vein. Aneurysm. Computed tomography.

#### CASE REPORT

A 35-year-old female presented with right upper quadrant pain. On physical examination, no tenderness or abdominal rigidity was seen. There was splenomegaly; no palpable abdominal mass was felt. Contrast enhanced computed tomography (CECT) showed liver parenchymal disease with portal hypertension (ascites, collateral and splenomegaly). There was aneurysmal dilatation of the left branch of the portal vein at its bifurcation (Figures 1 and 2). The main portal vein was dilated, right portal vein, hepatic arteries and vein were normal. Thus, the patient was diagnosed to have liver parenchymal disease with portal hypertension and portal vein aneurysm.

Portal vein aneurysms (PVA) are rare entities. They are usually extra-hepatic and intrahepatic PVA are rarer.<sup>1</sup> PVA etiology is not well understood but two categories: acquired and congenital have been postulated.<sup>2</sup> Failure of complete regression of the distal right primitive vitelline vein or inherent vessel wall weakness is considered as congenital causes in the normal liver background. Acquired causes include mainly chronic liver disease, portal hypertension, trauma, pancreatitis and surgery. CECT is the usual imaging modality and it accurately

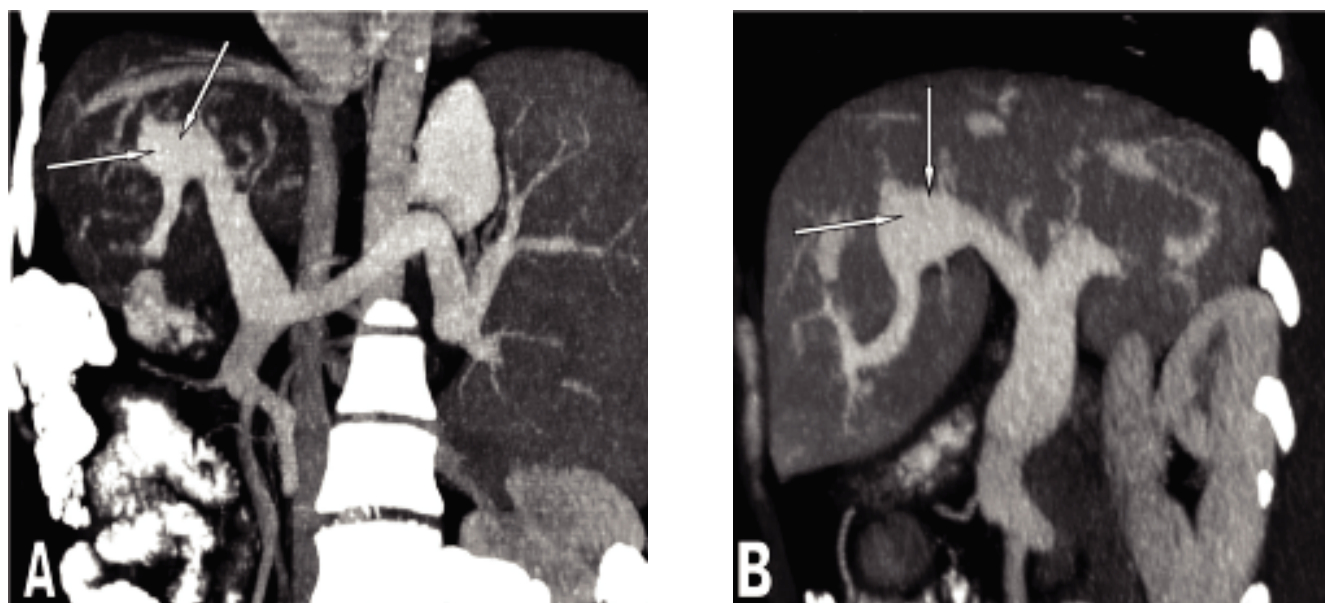
depicts the site, size, relation of the aneurysm with the vessels and its extension.<sup>3</sup> Color Doppler ultrasonography and magnetic resonance imaging can also depict the PVA accurately and can be used for confirming the finding.<sup>4</sup> CECT can also give accurate information regarding thrombosis, rupture or any other complication of the PVA.<sup>5</sup> Usually PVA are incidental findings, are asymptomatic and require no treatment. Serial follow up imaging can be done for assessing the PVA if needed. If the aneurysm is large or is causing symptoms due to its mass effect then it may require treatment. Medical management includes anticoagulation. Surgical management options include aneurysmorrhaphy, portocaval shunt, and mesocaval shunt. Serial imaging may be advised if PVA are stable and no complications are seen instead of going for surgical or medical treatment.



**Figure 1.** Contrast enhanced axial section showing aneurysmal dilatation of left branch of portal vein (arrows).

Correspondence and reprint request: Dr. Sameer Vyas  
Assistant Professor  
Department of Radiodiagnosis and Imaging, PGIMER, Chandigarh, India.  
Ph.: 0946-3836653. Fax: 0172- 2745768  
E mail: sameer574@yahoo.co.in

Manuscript received: July 22, 2011.  
Manuscript accepted: October 15, 2011.



**Figure 2.** Oblique coronal and sagittal reformatted sections demonstrating portal vein aneurysm (arrows).

### DISCLOSURE OR INTEREST

Source(s) of funding or financial interest- Nil.

### REFERENCES

1. Mucenic M. Review. *Gastroenterol Hepatol* 2007; 3: 299-300.
2. Feliciano PD, Cullen JJ, Corson JD. The management of extrahepatic portal vein aneurysms: observe or treat? *HPB Surg* 1996; 10: 113-6.
3. Lopez-Machado E, Mallorquin-Jimenez F, Medina-Benitez A, Ruiz-Carazo E, Cubero-Garcia M. Aneurysms of the portal venous system: ultrasonography and CT findings. *Eur J Radiol* 1998; 26: 210-4.
4. Atasoy KC, Fitoz S, Akyar G, et al. Aneurysms of the portal venous system. Gray-scale and color Doppler ultrasonographic findings with CT and MRI correlation. *Clin Imaging* 1998; 22: 414-7.
5. Okur N, Inal M, Akgül E, Demircan O. Spontaneous rupture and thrombosis of an intrahepatic portal vein aneurysm. *Abdom Imaging* 2003; 28: 675-7.