

# Congenital double intrahepatic portosystemic shunt: Imaging findings and endovascular closure

Guglielmo Paolantonio,\* Andrea Pietrobattista,\*\* Manila Candusso,\*\*  
Lidia Monti,\*\*\* Jean de Ville de Goyet,\*\*\*\* Giuliano Torre,\*\* Massimo Rollo\*

\* Interventional Radiology Unit, Department of Surgery. \*\* Gastroenterology Hepatology and Nutrition Unit, Department of Surgery.

\*\*\* Department of Imaging, \*\*\*\* Department of Surgery. Bambino Gesù Children's Hospital, Rome, Italy.

A 3-month-old boy, first child of unrelated parents, born by emergency Caesarean section at the thirty-first week of pregnancy because of heart failure and fetal hydrops, prenatal screening of mitral valve dysplasia and ostium secundum type atrial septal defect, was admitted to the Gastroenterology Hepatology and Nutrition Unit of the hospital for high blood ammonia levels [159 micrograms/decilitre ( $\mu\text{g/dL}$ ); normal levels: 0-75  $\mu\text{g/dL}$ ]. At admission, the patient was in good clinical condition, without encephalopathy or heart failure signs. Liver function tests were in the normal range as well as blood gas analysis. The patient underwent a wide metabolic screening in order to identify specific diagnosis. All the investigations were negative while his ammonia level was repeatedly high. Therefore, he was started on oral Arginine (250 mg/kg/day in 3 doses) with prompt resolution of hyperammonemia. As part of the diagnostic work-up a liver ultrasound (US) examination was performed and showed a communication channel between the left portal vein and the inferior vena cava suggesting a persistent patent ductus venosus (PDV) (Figure 1A). No focal hepatic lesion was detected. Contrast-enhanced (CE) multi-detector-row computed tomography (MDCT) of the liver confirmed the PDV arising from the hypertrophic umbilical segment of the left portal vein to join the subdiaphragmatic tract of inferior vena cava. The right portal vein appeared very hypoplastic while intrahepatic portal vessels were poorly

detected. Moreover, an additional smaller intrahepatic shunt between the right portal system and the posterior subdiaphragmatic inferior vena cava was also visualized (Figure 1B-1D). A diagnosis of congenital portosystemic shunt was made and the cause of hyperammonemia was finally attributed to portal flow bypassing the liver through the shunt. A 12 months clinical follow up was carried out waiting for a spontaneous regression of the shunt. Clinically the follow up was uneventful with the patient thriving well and developing fine. Ammonia levels remained within the normal range. However the strict correlation between shunt patency and elevated blood ammonia warned off reducing medical treatment because of the risk of brain toxicity and portal systemic encephalopathy.<sup>1,2</sup> Doppler US scan confirmed shunt patency, therefore its closure was considered to prevent complications. Transjugular portography with balloon occlusion test of the PDV was performed (Figure 2). Angiography revealed a higher flow in portal system through the bigger shunt with portal pressure value of 11 mmHg. No intrahepatic portal branches were visualized. The smaller fistula arose from the right hypoplastic portal vein and flowed with Y shape into the subdiaphragmatic inferior vena cava (Figures 2A and 2B). Occlusion test with a 10 mm diameter Swan-Ganz catheter balloon inflated within the ductus allowed visualization of the entire intrahepatic portal vessels without increased portal pressure (17 mmHg) (Figures 2C and 2D). Endovascular closure of the double portocaval shunt was performed in one step (Figures 3A and 3C). Coil embolization was performed first in the smaller shunt while an Amplatzer septal occluder device was released in the PDV. The malformations appeared closed and the portal vascularization increased particularly in the right system. Plasma ammonia levels spontaneously decreased soon after the procedure (21  $\mu\text{g/dL}$ ) so medical therapy with arginine was suspended. After

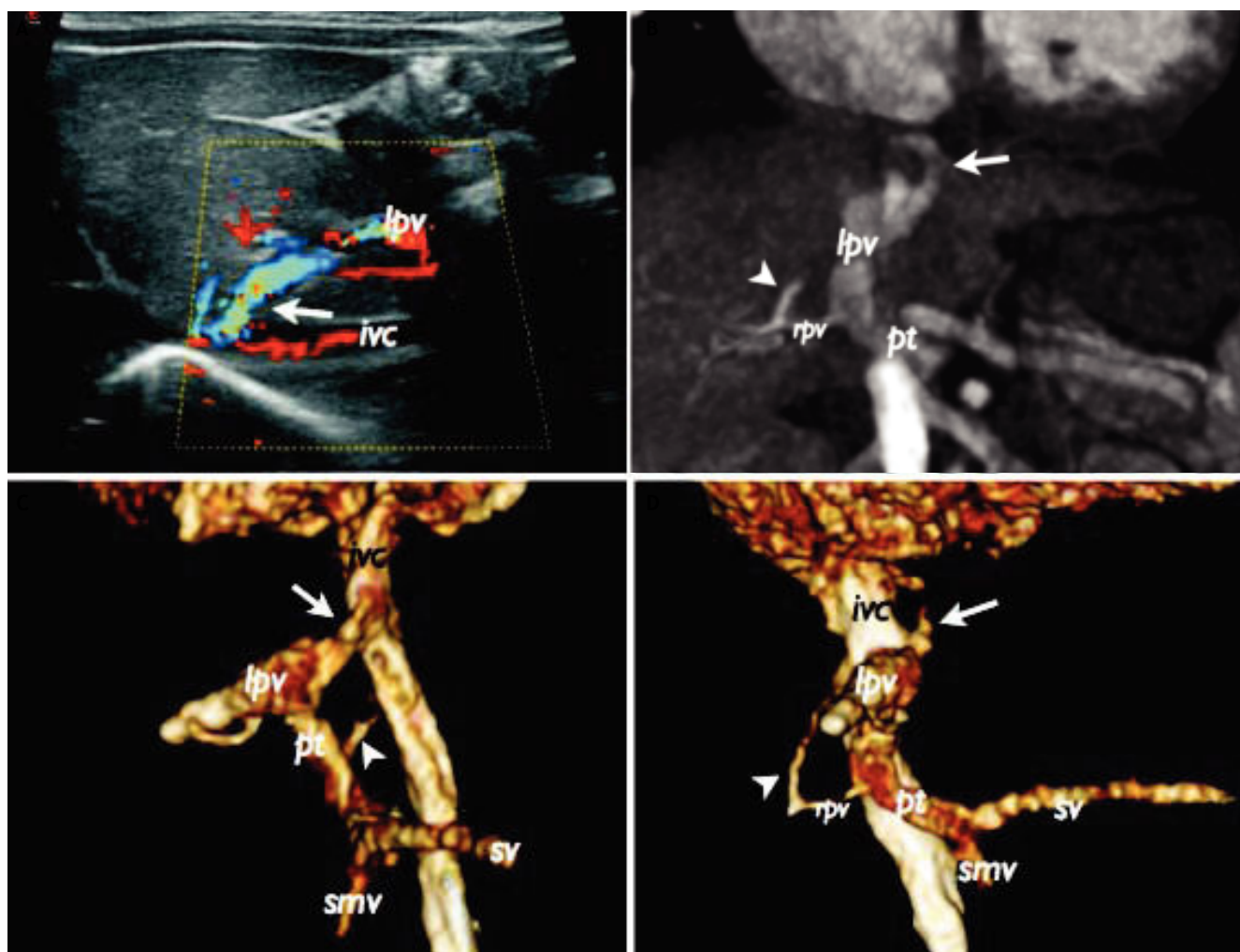
Correspondence and reprint request: Guglielmo Paolantonio, M.D.  
Interventional Radiology Unit, Department of Surgery, Bambino Gesù  
Children's Hospital, Rome, Italy. Piazza Sant'Onofrio, 4 00165 Rome, Italy  
Phone: +39 06 6859 2816 Phone: +39 06 6859 2812 Fax: +39 06 6859 3889  
E-mail: [guglielmo.paolantonio@opbg.net](mailto:guglielmo.paolantonio@opbg.net)  
[guglielmo.paolantonio@gmail.com](mailto:guglielmo.paolantonio@gmail.com)

Manuscript received: November 04, 2014.

Manuscript accepted: February 18, 2014.

DOI: 10.5604/16652681.1171742

© 2019, Fundación Clínica Médica Sur, A.C. Published by Elsevier España S.L.U. This is an open access article under the CC BY-NC-ND license (<http://creativecommons.org/licenses/by-nc-nd/4.0/>).

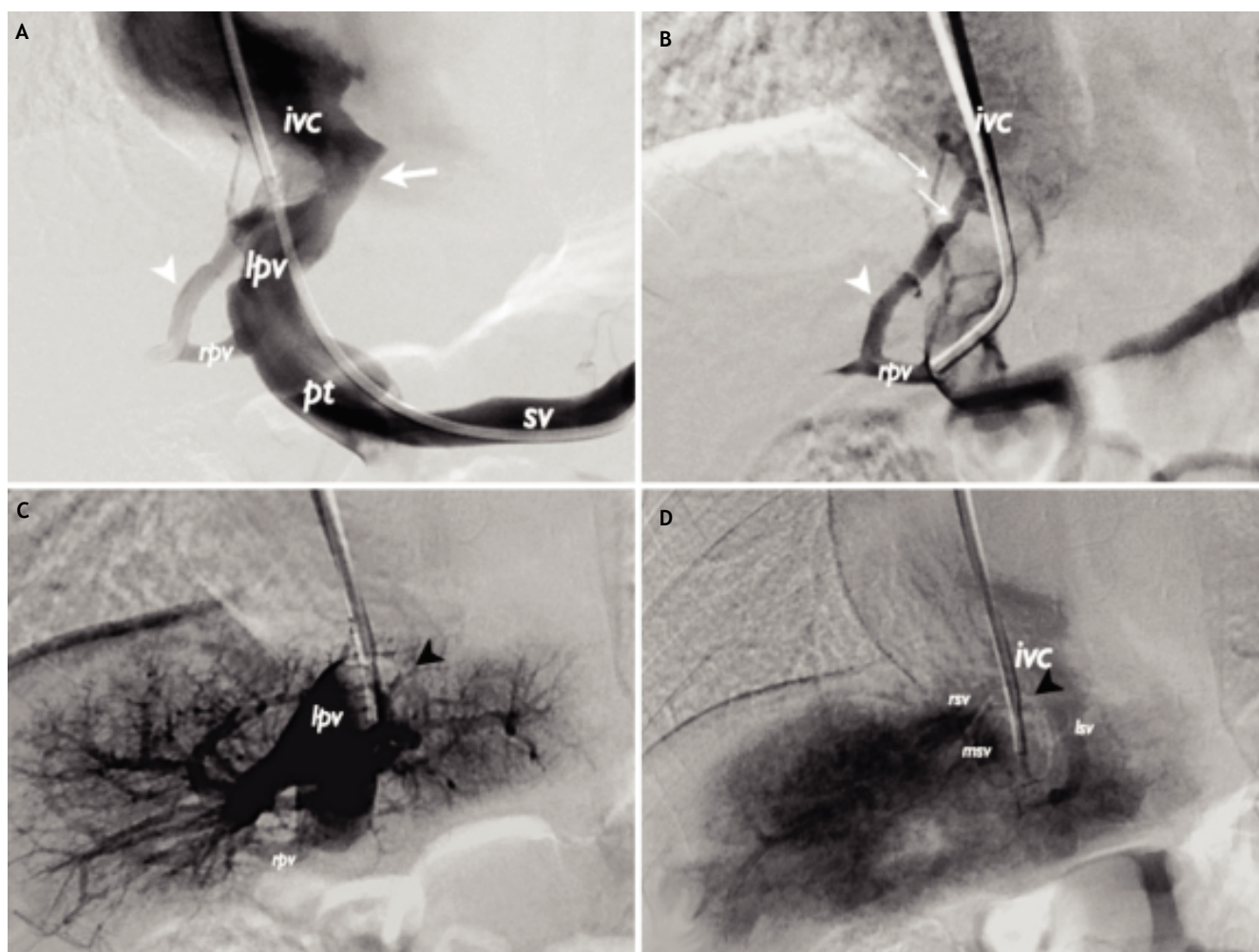


**Figure 1.** A. Sagittal color Doppler ultrasound image of the left hepatic lobe shows a vascular collector (arrow) connecting the left portal vein (lpv) to the subdiaphragmatic inferior vena cava [IVC (ivc) suspected for persistent PDV]. B-D. Multi-intensity projection (B) and 3D volume-rendered (C and D) images of the portal venous system reformatted on coronal oblique (B and C) and sagittal (D) planes from CE-MDCT show the PDV (arrow) and the smaller intrahepatic shunt (arrow head) between the hypoplastic right portal vein (rpv) and the subdiaphragmatic IVC. pt: portal trunk. lpv: left portal vein. sv: splenic vein. smv: superior mesenteric vein.

6 months from the procedure the shunts were closed without signs of revascularization. The plug and coils were in the correct position and the portal venous system appeared entirely patent and remodelled with normal appearance. Particularly, the main portal trunk and left portal vein demonstrated with reduced caliber while the right portal trunk was more developed than previously (Figures 3D-3F).

Congenital portosystemic shunts (CPSs) are rare disorders with overall prevalence of 1:30.000 births.<sup>1,3-5</sup> To our knowledge there are very few studies to date examining the coexistence of two intrahepatic shunts. Particularly in the reported case

the bigger shunt was a persistent PDV, an uncommon cause of intrahepatic CPS. Notably Yoshimoto, *et al.* identified only 16 previously reported cases of persistent PDV in children.<sup>6</sup> Although the children can remain relatively asymptomatic, clinically significant complications of these malformations such as encephalopathy, pulmonary artery hypertension, hepatopulmonary syndrome, liver tumors and heart failure can be observed, even in adulthood.<sup>1</sup> CPSs can be associated with others congenital malformations as cardiac disease. We report the case of a congenital double intrahepatic side-to side portocaval shunt in an infant with mitral valve dysplasia and ostium secundum type atrial septal defect. Heart

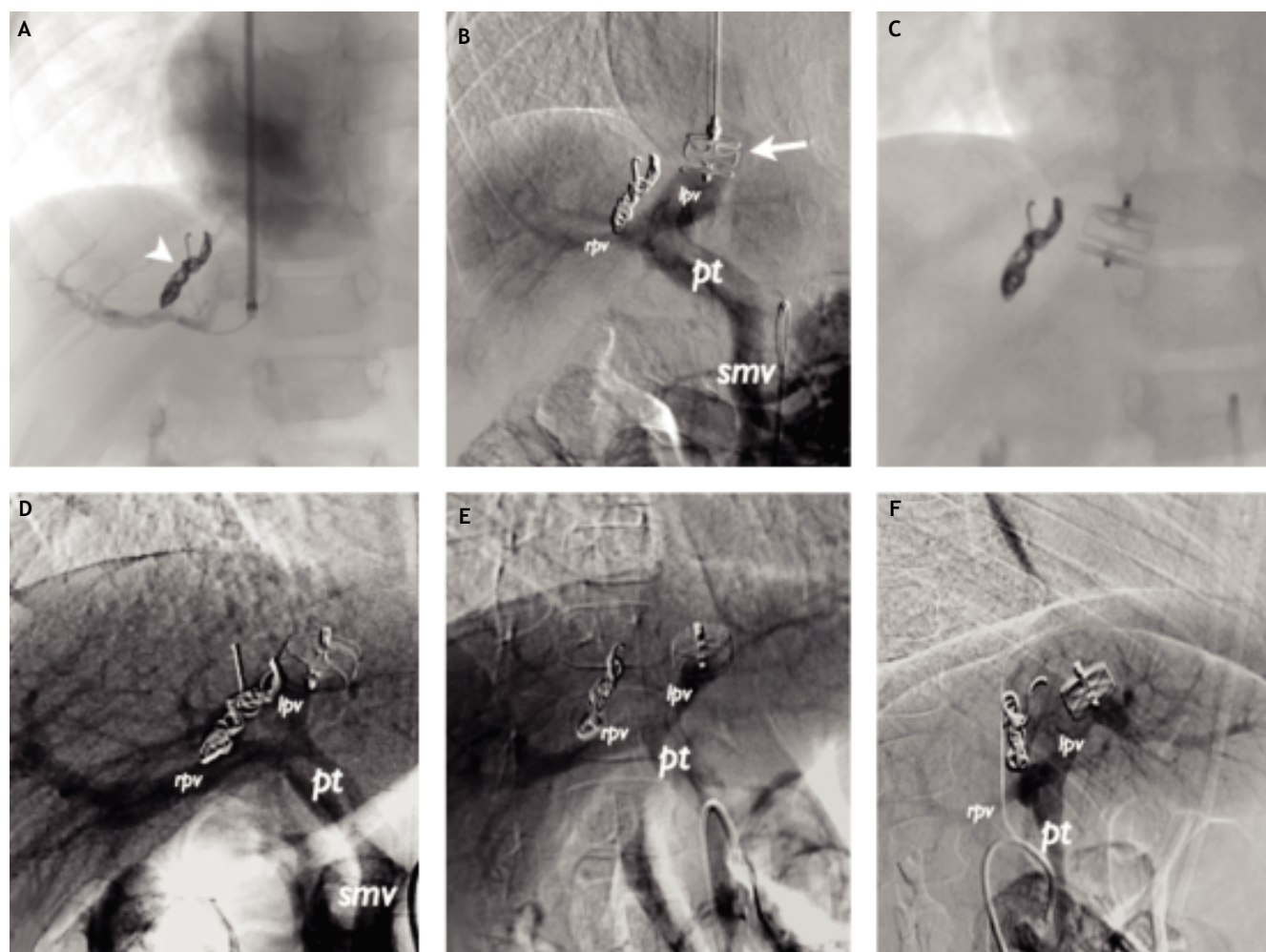


**Figure 2.** Transjugular portography performed after catheterization of the splenic (A) and right portal vein (B) through the PDV and during balloon occlusion test (C and D) [digital subtraction images on coronal projection]. A and B. Portograms show the high-flow in the larger fistula (arrow) and better highlight the smaller shunt with Y shape arising from the hypoplastic right portal vein and directing to the subdiaphragmatic inferior vena cava (white arrow head and thin arrows). No intrahepatic portal venous branch was visualized. C and D. Angiograms during occlusion test with Swan-Ganz catheter balloon inflated within the PDV (black arrow head) show the opacification of the entire intrahepatic portal venous branches and suprahepatic veins too. rsv: right suprahepatic vein. msv: middle suprahepatic vein. lsv: left suprahepatic vein.

failure at birth and hyperammonemia can be considered as complication of the vascular malformation. Moreover, congenital heart disease was reported in 30% of CPS cases.<sup>1,5,7</sup> Stringer refers that in some cases of CPS associated with congenital cardiac disease the abnormal persistence of an embryonic vitelline vein may be secondary to abnormal hemodynamics.<sup>7</sup> Early detection and appropriate management of these malformations are crucial for a good prognosis.<sup>5</sup> Color Doppler US helps to detect the intrahepatic CPSs, especially in the prenatal period. However, CE-MDCT or magnetic resonance imaging examinations allow to assess the anatomy

of both shunts and portal vein system.<sup>5</sup> Morgan and Superina distinguished the CPSs as intrahepatic (CIPs) or extrahepatic,<sup>8</sup> while Park, *et al.* subdivided the CIPs into four categories.<sup>7,9</sup> Bernard, *et al.* suggest a description of the CIPs based on: part of portal system where the shunt arises, the systemic vein of termination of the fistula, the type and the number of communications with the systemic vein (end-to-side *vs.* side-to-side).<sup>3</sup> These classifications refer to the anatomical and embryological distinction of the CIPs and they are very useful to understand the physiology and choose the right diagnostic approach. However they do not consider the absence





**Figure 3.** Endovascular closure of the shunts (A-C) (digital subtraction image in B). A. The coil embolization (arrow head) of the smaller fistula improved the early vascularization of the right portal vein system. B. Check during vascular plug placement (arrow) within the PDV. Portogram obtained after injection of contrast medium through the superior mesenteric artery shows complete closure of shunts with good opacification of intrahepatic portal vein system. C. Plug and coils in the correct position at the end of the procedure. D-F. Angiography via the superior mesenteric artery 6 months following in the portal venous phase (D-F) (digital subtraction images). The shunts appear closed without signs of revascularization and the portal venous system entirely patent and remodelled with normal appearance.

of hypoplasticity of intrahepatic portal vein branches. We reckon that the intrahepatic portal system evaluation has a pivotal role to determine the therapeutic management of patients with CPS. In that regard recently Kanazawa, *et al.* proposed a new interesting classification of CPS based on the grading of hypoplasia of the intrahepatic portal system during shunt occlusion.<sup>10</sup> The management of CIPSS in children is still controversial.<sup>1,5</sup> Spontaneous regression of smaller and asymptomatic shunts may be observed up to 2 years of age, while larger, symptomatic or persistent patent fistulas require their early closure to prevent complications. Multidiscipli-

nary approach is strongly advocate with CPS, considering that the treatment is based on either radiological or a surgical procedure. Grimaldi, *et al.* reports how radiologic interventions are currently the therapeutic standard for managing of CPS, with surgery reserved for patients who are not eligible for radiological procedures and those requiring liver transplantation.<sup>4</sup> In view of the shunt closure, portography with balloon occlusion test of the shunt and subsequence portal pressure measurement is pivotal in deciding whether single *vs.* multi-step intervention is indicated. When the intrahepatic portal branches and the portal pressure value does not ex-

ceed 32 mmHg, as observed in the patient, one-step shunt closure is indicated. However, when there is poor visualization of the intrahepatic portal branches and the portal pressure value is greater than 32 mmHg, two-step shunt closure is indicated to avoid acute portal hypertension.<sup>1,3-5,10</sup> Temporary surgical banding of the shunt help to decrease the portal pressure up to 20 mmHg and may improve vascularization in the hypoplastic portal system. The final shunt closure is then performed 3-10 months later.<sup>1,3-5</sup> Amplatzer vascular plug is usually recommended technique for large high-flow fistulas using a device with a diameter of 30 to 50% larger than the shunt diameter to help reduce device migration.<sup>4</sup> Considering the effectiveness of the 10 mm diameter Swan-Ganz balloon to block the PDV during the occlusion test of this patient, we opted for a 12 mm diameter plug device for embolization of the bigger shunt. Conversely, coils were optimal for the smaller shunt closure. The portal venous system of the child appeared abnormal on preoperative imaging. Particularly, the right portal vein was hypoplastic while both the main and left portal veins were mildly enlarged due to high blood flow in the larger shunt. Endovascular treatment improved the vascularization of the intrahepatic portal venous system and remodelled its anatomy. Six months after the procedure the right portal system appeared hypertrophic while both the left and main portal trunk demonstrated reduced calibre due to shunt closure. Stewart, *et al.* report that this condition may be attributed to the innate plasticity of the pediatric vascular system, which has high capacity to rapidly hypertrophy and form collateral vessels.<sup>11</sup>

In conclusion, intrahepatic vascular shunts must be considered in the differential diagnosis of a child with hyperammonemia especially in the absence of liver cirrhosis. The visualization of intrahepatic portal system under occlusion test is crucial to establish the proper treatment. When feasible, radiological closure should be considered as first line treatment being less invasive than surgical ligation.

## DISCLOSURES

None.

## REFERENCES

1. Franchi-Abella S, Branchereau S, Lambert V, Fabre M, Steimberg C, Losay J, Riou JY, et al. Complications of congenital portosystemic shunts in children: therapeutic options and outcomes. *J Pediatr Gastroenterol Nutr* 2010; 51: 322-30. Doi: 10.1097/MPG.0b013e3181d9cb92.
2. Uchino T, Matsuda I, Endo F. The long-term prognosis of congenital portosystemic venous shunt. *J Pediatr* 1999; 135: 254-6.
3. Bernard O, Franchi-Abella S, Branchereau S, Pariente D, Gauthier F, Jacquemin E. Congenital portosystemic shunts in children: recognition, evaluation, and management. *Semin Liver Dis* 2012;32: 273-87. Doi: 10.1055/s-0032-1329896.
4. Grimaldi C, Monti L, Falappa P, d'Ambrosio G, Manca A, de Ville de Goyet J. Congenital intrahepatic portohepatic shunt managed by interventional radiologic occlusion: a case report and literature review. *J Pediatr Surg* 2012;47: e27-e31. Doi: 10.1016/j.jpedsurg.2011.10.079.
5. Kim MJ, Ko JS, Seo JK, Yang HR, Chang JY, Kim GB, Cheon JE, et al. Clinical features of congenital portosystemic shunt in children. *Eur J Pediatr* 2012; 171: 395-400. Doi: 10.1007/s00431-011-1564-9.
6. Yoshimoto Y, Shimizu R, Saeki T, Harada T, Sugio Y, Nomura S, Tanaka H, et al. Patent ductus venosus in children: a case report and review of the literature. *J Pediatr Surg* 2004;39: E1-E5.
7. Stringer MD. The clinical anatomy of congenital portosystemic venous shunts. *Clin Anat* 2008; 21: 147-57. Doi: 10.1002/ca.20574.
8. Morgan G, Superina R. Congenital absence of the portal vein: two cases and a proposed classification system for portosystemic vascular anomalies. *J Pediatr Surg* 1994; 29: 1239-41.
9. Park JH, Cha SH, Han JK, Han MC. Intrahepatic portosystemic venous shunt. *AJR Am J Roentgenol* 1990; 155: 527-8. Doi: 10.2214/ajr.155.3.2117349.
10. Kanazawa H, Nosaka S, Miyazaki O, Sakamoto S, Fukuda A, Shigeta T, Nakazawa A, et al. The classification based on intrahepatic portal system for congenital portosystemic shunts. *J Pediatr Surg* 2015; 50: 688-95. Doi: 10.1016/j.jpedsurg.2015.01.009.
11. Stewart JK, Kuo WT, Hovsepian DM, Hofmann LV, Bonham CA, Sze DY. Portal venous remodeling after endovascular reduction of pediatric autogenous portosystemic shunts. *J Vasc Interv Radiol* 2011; 22: 1199-205. doi: 10.1016/j.jvir.2011.01.438.