

# Intrahepatic aneurysmal portohepatic venous shunt: what should be done?

Nidhi Prabhakar,\* Sameer Vyas,\* Sunil Taneja,\*\* Niranjan Khandelwal\*

Departments of \* Radiodiagnosis and \*\* Hepatology.  
Postgraduate Institute of Medical Education and Research, Chandigarh, India.

Aneurysmal portohepatic venous shunt is communication between the branches of portal and hepatic veins that shows aneurysmal dilatation. They are rare. However with advances in cross-sectional imaging techniques and increased utilization of imaging modalities, the detection of asymptomatic intrahepatic portosystemic venous shunts has increased. Identification and characterization of the portosystemic shunts is very important for radiologists as well as hepatologists. These lesions may be mistaken for hypervascular lesions on CT or cysts on sonography (if colour doppler is not used). Patients with smaller shunts are regularly followed up whereas those with larger or symptomatic shunts (causing hepatic encephalopathy, galactosemia or hyperammonemia) have to be treated.

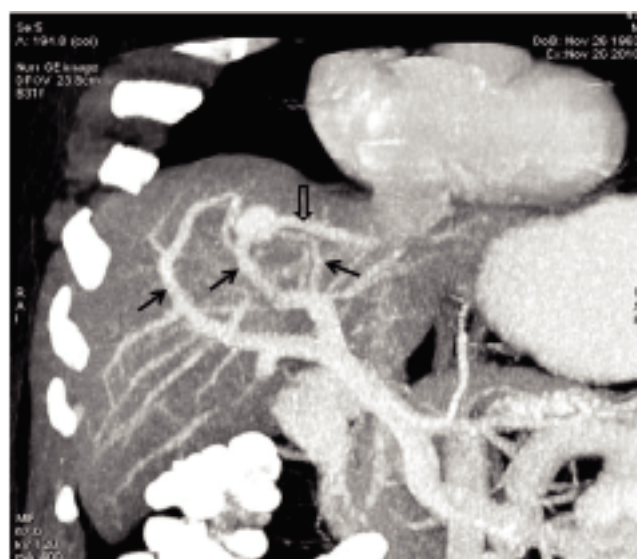
## CASE REPORT

A 47-year old male presented to the emergency, with severe abdominal pain in the epigastrium. Ultrasound of the abdomen was normal. Contrast-enhanced CT of the abdomen (Figures 1 and 2) revealed a communicating vessel between branches of the portal vein and middle hepatic vein suggestive of portohepatic venous shunt, which showed aneurysmal dilatation. This aneurysm measured approximately 18 x 12 x 12 mm in size. No other abnormality was seen on CT. Upper gastrointestinal endoscopy showed features of gastritis, for which he was treated with antihistaminics and antacids. Pain was completely relieved after 2 weeks of treatment. No immediate intervention

was done for the shunt as it was an incidental finding and not causing any symptoms. Laboratory investigations, including complete haemogram and liver function tests, were normal. No evidence of hyperammonemia or galactosemia was seen. Patient is on regular follow up, to look for any increase in the size of the aneurysm or any evidence of hepatic encephalopathy.

## DISCUSSION

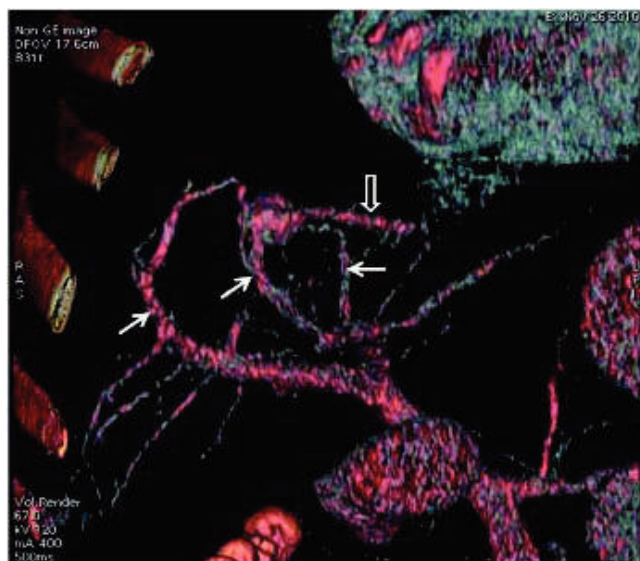
Intrahepatic vascular shunts are broadly divided into three types: portosystemic venous, arterioportal and arteriosystemic. Most of the shunts are seen in cirrhotic patients but can also be congenital or traumatic in origin.<sup>1</sup> Incidentally detected intrahepatic portal venous shunts do not usually show any symp-



**Figure 1.** Maximum intensity projection coronal oblique CT image showing aneurysm measuring 18 x 12 x 12 mm in the liver, which is communicating with two vessels arising from the left portal vein and one vessel arising from the right portal vein (solid arrows), and also with a vessel draining into the middle hepatic vein (hollow arrow).

Correspondence and reprint request: Dr. Sameer Vyas, Assistant Professor  
Department of Radiodiagnosis and Imaging  
PGIMER, Chandigarh, India.  
Ph.: 08872016105. Fax: 0172-2745768  
E-mail: sameer574@yahoo.co.in

Manuscript received: May 14, 2014.  
Manuscript accepted: August 30, 2014.



**Figure 2.** Volumetric rendering technique CT image showing aneurysm, which is communicating with two vessels arising from the left portal vein and one vessel arising from the right portal vein (solid arrows), and also with a vessel draining into the middle hepatic vein (hollow arrow).

toms or manifestations of liver disease. They are most common in left lobe and are solitary.<sup>2-3</sup> Intrahepatic portal venous shunts are classified into four types by Park, *et al.*<sup>4</sup> In type I portal venous shunt, a single large tubular shaped vessel that has a constant diameter is seen, which connects the right portal vein to the inferior vena cava. Type II is a peripheral shunt that is characterized by a single or multiple communications between the peripheral branches of portal and hepatic veins, in one particular hepatic segment. In type III portal venous shunt, an aneurysmal communication is noted between the peripheral portal and hepatic veins. A type IV portal venous shunt is one in which multiple, diffuse communications between peripheral portal and hepatic veins are seen, in both lobes of the liver. Our case represents the type III intrahepatic portal venous shunt. Most common shunts are the type 1 shunts. However, few case series have shown type 3 to be most common.<sup>2,4,5</sup>

Intrahepatic portohepatic venous shunts are mostly congenital. They occur due to failure of regression of connection among subcardinal venous system and vitelline venous system. In the early embryological life, these connections exist. A part of the hepatic segment of the inferior vena cava is formed by right subcardinal vein. Vitelline vein gets broken into hepatic sinusoids, which becomes the hepatic veins and the intrahepatic portal vein

branches. Persistence of vitelline sinusoids and right vitelline vein may lead to development of portosystemic shunt. They are known to resolve spontaneously in infancy.<sup>6</sup> Patients having portohepatic venous shunts are usually asymptomatic. However, these patients may present with hyperammonemia and hepatic encephalopathy. In addition, they may be associated with cardiac defects, hepatoblastoma, abnormal lobulation of the liver and extrahepatic biliary atresia.<sup>7</sup> The physiological effects of shunt can be better predicted on the basis of shunt ratio. Iodine 123-iodoamphetamine per rectal portal scintigraphy can determine the shunt ratio. It can also be calculated by Doppler. Blood flow volume through the shunt divided by the total portal blood flow volume gives the shunt ratio.<sup>8</sup> If the shunt ratio is less than 30%, shunt is likely to remain asymptomatic throughout life. If it is 30-60%, shunt will manifest with symptoms some time. However if it is > 60% (in either type I, II, III or IV shunt), it needs intervention, even if the symptoms of hepatic encephalopathy are absent.<sup>9</sup> Surgical ligation, hepatic resection, splenorenal shunt and shunt embolisation are treatments which are available. Known complication of blocking the shunt is exacerbation of portal hypertension.<sup>8</sup>

Different approaches to embolisation, have been described which include retrograde, transcaval, transileocolic and percutaneous. The embolic agents which can be used are coils, gelfoam particles and polyvinyl particles. Successful use of amplatzer vascular plug for embolisation has also been described by few authors.<sup>10,11</sup>

## FUNDING

Source(s) of funding or financial interest- Nil.

## REFERENCES

1. Lane MJ, Jeffrey RB Jr, Katz DS. Spontaneous intrahepatic vascular shunts. *AJR Am J Roentgenol* 2000; 174: 125-31.
2. Remer E, Motta-Ramirez G, Henderson J. Imaging findings in incidental intrahepatic portal venous shunts. *AJR Am J Roentgenol* 2007; 188: 162-7.
3. Raskin NH, Price JB, Fishman RA. Portal systemic encephalopathy due to congenital intrahepatic shunts. *New Engl J Med* 1964; 270: 225-9.
4. Park JH, Cha SH, Han JK, Han MC. Intrahepatic portosystemic venous shunt. *AJR Am J Roentgenol* 1990; 155: 527-8.
5. Tanoue S, Kiyosue H, Komatsu E, Hori Y, Maeda T, Mori H. Symptomatic intrahepatic portosystemic venous shunt: angiographic findings and transcatheter embolization

- with an alternative approach. *AJR Am J Roentgenol* 2003; 181: 71-8.
6. Mori H, Hayashi K, Fukuda T, Matsunaga N, Futagawa S, Nagasaki M, Mutsukura M. Intrahepatic Portosystemic Venous Shunt-Occurrence in Patients with and Without Liver-Cirrhosis. *AJR Am J Roentgenol* 1987; 149: 711-4.
  7. Saxena AK, Sodhi KS, Arora J, Thapa BR, Suri S. Congenital Intrahepatic portosystemic venous shunt in an infant with Down syndrome. *AJR Am J Roentgenol* 2004; 183: 1783-4.
  8. Oguz B, Akata D, Balkanci F, Akhan O. Intrahepatic portosystemic venous shunt: diagnosis by colour/power Doppler imaging and three-dimensional ultrasound. *Br J Radiol* 2003; 76: 487-90.
  9. Gallego C, Miralles M, Marín C, Muyor P, González G, García E. Congenital Hepatic Shunts. *RadioGraphics* 2004; 24: 755-72.
  10. Grimaldi C, Monti L, Falappa P, d'Ambrosio G, Manca A, de Ville de Goyet J. Congenital intrahepatic shunt managed by interventional radiologic occlusion: a case report and literature review. *J Pediatr Surg* 2012; 47: e27-e31.
  11. Lee YJ, Shin BS, Lee IH, Ohm JY, Lee BS, Ahn M, Kim HJ. Intrahepatic portosystemic venous shunt: successful embolization using the Amplatzer Vascular Plug II. *Korean J Radiol* 2012; 13: 827-31.