

Reversal of advanced fibrosis after long-term ursodeoxycholic acid therapy in a patient with residual expression of MDR3

Bernardo Frider,* Amalia Castillo,** Raquel Gordo-Gilart,***
Andrés Bruno,* Marcelo Amante,* Luis Alvarez,*** Verónica Mathet**

* Servicio de Hepatología Clínica. Hospital Cosme Argerich. Buenos Aires, Argentina.

** Instituto de Investigaciones en Microbiología y Parasitología Médica (IMPAM), Facultad de Medicina, Universidad de Buenos Aires (UBA), Consejo Nacional de Investigaciones Científicas y Técnicas (CONICET). Buenos Aires, Argentina.

*** Instituto de Investigaciones Hospital Universitario La Paz (IdiPAZ). Madrid, España.

ABSTRACT

Introduction. Progressive familial intrahepatic cholestasis type 3 (PFIC-3) is a severe liver disorder associated with inherited dysfunction of multidrug resistance protein 3 (MDR3/*ABCB4*), which functions as a phospholipid floppase, translocating phosphatidylcholine from the inner to the outer hemileaflet of the canalicular membrane of hepatocytes. MDR3 deficiency results in a disbalanced bile which may damage the luminal membrane of cells of the hepatobiliary system. We evaluated clinical, biochemical and histological improvement in a genetically proven PFIC-3 patient after long-term ursodeoxycholic acid (UDCA) administration. **Material and methods.** A PFIC-3 patient and a relative with cholestatic liver disease were studied. Hepatic MDR3 expression was analyzed by immunohistochemistry and *ABCB4* mutations were identified. The effect of the mutations on MDR3 expression and subcellular localization was studied *in vitro*. **Results.** A 23-year-old man presented cholestasis with severe fibrosis and incomplete cirrhosis. Canalicular staining for MDR3 was faint. Sequence analysis of *ABCB4* revealed two missense mutations that reduce drastically protein expression levels. After 9 years of treatment with UDCA disappearance of fibrosis and cirrhosis was achieved. **Conclusion.** These data indicate that fibrosis associated with MDR3 deficiency can be reversed by long-term treatment with UDCA, at least when there is residual expression of the protein.

Key words. PFIC-3. *ABCB4*. Cholestasis.

INTRODUCTION

Progressive familial intrahepatic cholestasis type 3 (PFIC-3) is a severe autosomal recessive liver disorder associated with disruption of *ABCB4* gene, which encodes multidrug resistance protein 3 (MDR3).¹ MDR3 functions as a phospholipid floppase, translocating phosphatidylcholine from the inner to the outer hemileaflet of the canalicular membrane of hepatocytes.² The secretion of this phospholipid is of crucial importance in the protection of the cellular membranes of the biliary tree against the high concentrations of detergent bile salts. MDR3 deficiency is suggested to result in a

disbalanced bile which may damage the luminal membrane of cells of the hepatobiliary system.³ Mutations in this gene are associated with a broad spectrum of hepatobiliary disorders ranging from PFIC-3 to low phospholipid-associated cholelithiasis (LPAC) and intrahepatic cholestasis of pregnancy (ICP).^{4,5} PFIC-3 manifests in infancy or adolescence and may lead to end-stage liver disease. Affected children usually present with jaundice, hepatomegaly, discolored stools or pruritus. Presentation in adolescents is usually with gastrointestinal bleeding and cirrhosis. Biochemical features include markedly elevated serum γ -glutamyl transpeptidase (GGT) activity and normal cholesterol levels. In early stages, liver biopsy shows ductular proliferation, portal inflammatory infiltrate and moderate portal fibrosis. At later stages, broad portal fibrosis and biliary cirrhosis are evidenced.^{1,4} The severity of liver disease varies among PFIC-3 individuals. Approximately one half of patients benefit from oral administration of ursodeoxycholic acid (UDCA). This therapy normalises liver function tests and

Correspondence and reprint request: Bernardo Frider, M.D.
Salguero 2601 (1425). Buenos Aires, Argentina.
Tel.: 54 11 4801 0502. Fax: 54 11 4801 0502.
E-mail: bernardo@frider.com.ar

Manuscript received: October 14, 2014.
Manuscript accepted: December 20, 2014.

seems to prevent progression towards cirrhosis. Non-responders ultimately require liver transplantation during infancy or childhood.⁶ These differences in outcomes have been attributed to the type of mutation in *ABCB4* gene.¹ Patients harboring *ABCB4* mutations which result in a lack of expression of MDR3 at the canalicular membrane of the hepatocyte develop severe liver disease refractory to UDCA treatment,^{7,8} whereas milder forms of the disease and favorable responses to this therapy are hypothesized to be due to missense mutations that reduce but do not abolish MDR3 activity.^{4,9,10} In fact, it was recently demonstrated the correlation between the impact of *ABCB4* mutations on the degree of MDR3 expression and floppase activity and the clinical outcomes of PFIC3.¹¹

In this study we documented clinical, biochemical and histological improvement in two related PFIC-3 patients, with reversal of advanced fibrosis and incomplete cirrhosis in one of the cases, after several years of treatment with UDCA. On the other hand, we report one new mutation in *ABCB4* gene underlying this liver disorder in both patients. To shed light on genotype-phenotype correlations, we have also analyzed the expression of both MDR3 mutants in cultured cells.

MATERIAL AND METHODS

Clinical characterization of the patients

Patient 1 (P1) was a 23-year-old male who was referred to Argerich Hospital (Buenos Aires, Argentina) in 2004 because of generalised pruritus (predominantly nocturnal and intensified in palms and foot soles) and coluria. His brother had died at 16 years old by upper gastrointestinal hemorrhage caused by esophageal varices bleeding due to cholestatic cirrhosis. An initial liver biopsy in P1 showed signs of chronic cholestasis, severe fibrosis and incomplete cirrhosis with presence of remanent portal tracts and ductopenia (Metavir score F4, Figures 1A and 1B show representative fields, thirty portal tracts were analysed).

Blood analyses revealed very high levels of alkaline phosphatase (ALP, 2542 IU/L; NV < 200 IU/L) and γ -glutamyl transpeptidase (GGT, 994 IU/L; NV < 48 IU/L), increased levels of total and direct bilirubin (4.37 and 2.45 mg/dL respectively; NV < 1.9 mg/dL and NV < 0.3 mg/dL, respectively), alanine aminotransferase (ALT, 982 IU/L; NV < 40) and aspartate aminotransferase (AST, 403 IU/L;

NV < 38 IU/L). Platelets, leucocytes and levels of copper in blood and urine were normal. Autoantibodies and viral serology for HAV, HBV and HCV were negative. Ultrasonography and magnetic resonance cholangiography were normal and no esophageal varices were detected by upper gastrointestinal endoscopy. Spleen size was normal.

Patient 2 (P2) is P1's aunt (sister of his mother), a 35-year-old woman who also presented cholestasis with slightly increased levels of ALP (385 IU/L) and GGT (178 IU/L), ALT and AST in the upper normal limit (40 and 38 IU/L respectively), and normal levels of bilirubin and platelets. Autoantibodies and viral serology for HAV, HBV and HCV were negative. Her first liver biopsy revealed ductopenia in less than 20% of tracts and conserved histoarchitecture. She was the only living relative diagnosed with cholestasis in the familiar screening performed to detect the disease.

Both patients have been treated with UDCA since cholestasis was detected (for 9 and 4 years respectively). P1 started treatment with a 15 mg/kg/day dose for two months and then it was increased to 20 mg/kg/day. P2 have been treated with a 12 mg/kg/day dose since the liver biopsy, performed in November 2009.

Informed consent was obtained from both patients included in this study and the protocol was approved by the Ethics Committee of Argerich Hospital and is in accordance with the Helsinki Declaration of 1975.

Histologic analysis and immunohistochemistry

Perls' Prussian blue, PAS, Masson trichrome and Hematoxylin & Eosin stained liver biopsy sections were assessed by a pathologist (MA) unaware of the sequencing analysis results.

Immunohistochemical studies were carried out on needle biopsy specimens fixed in 10% formalin and embedded in paraffin. Detection of MDR3 and MRP2 was performed by the antigen-retrieval method as previously described¹² using a mouse monoclonal anti-MDR3 (clone P3II-26; Merck Millipore, Billerica, MA, USA) and a mouse monoclonal anti-MRP2 (clone M2III-6; Merck Millipore, Billerica, MA, USA) as primary antibodies, at a 1:20 dilution. Liver sections of three patients without *ABCB4* mutations (two patients with PFIC-2 and one patient with PFIC-1) were used for comparison of intensity of MDR3 staining.

Transient elastography

A transient hepatic elastography was performed to P1 (in order to measure liver stiffness) using FibroScan® (Echosens, Paris, France). Ten measures were done (SR 100%).

Genetic analysis

Genomic DNA was obtained from whole blood using columns for DNA extraction (QIAamp DNA Mini kit, QIAGEN). All 27 coding exons of *ABCB4* gene (exons 2 to 28) and flanking intron-exon boundaries for P1 and exon 4 of *ABCB4* gene for P2 were amplified by polymerase chain reaction and sequenced on both strands using the 1.1 Big Dye Terminator RRMix (Applied Biosystems Inc., Foster City, CA, USA) and an ABI PRISM® 3100 sequencer. Primer sequences are available upon request. Each PCR contained 300 ng genomic DNA, with each primer at a concentration of 0.8 μ mol/L, 0.14 mmol/L deoxynucleoside triphosphates (Invitrogen), 1.0 mmol/L

magnesium chloride, and 2.5 U Taq polymerase (Invitrogen).

Site-directed mutagenesis

The substitutions R47Q and T82N were introduced into the plasmid pReceiver-M02-MDR3 (Capital Biosciences, Rockville, MD, USA), which contains the full open reading frame of *ABCB4*, by site-directed mutagenesis using the QuickChange II system (Stratagene, La Jolla, CA, USA). Primers used for mutagenesis were as follows (top strand shown; mutated nucleotides are in lowercase): R47Q, 5'-CATTGTTTCaATACTCCGATTGGC-3'; T82N, 5'-GGAGAGATGAaTGACAAATTG-3'. Successful mutant construction was confirmed by sequencing.

Cell culture, transient transfections and immunofluorescence

MDCKII and HEK293T cells were cultured in Dulbecco's modified Eagle's medium supplemented with

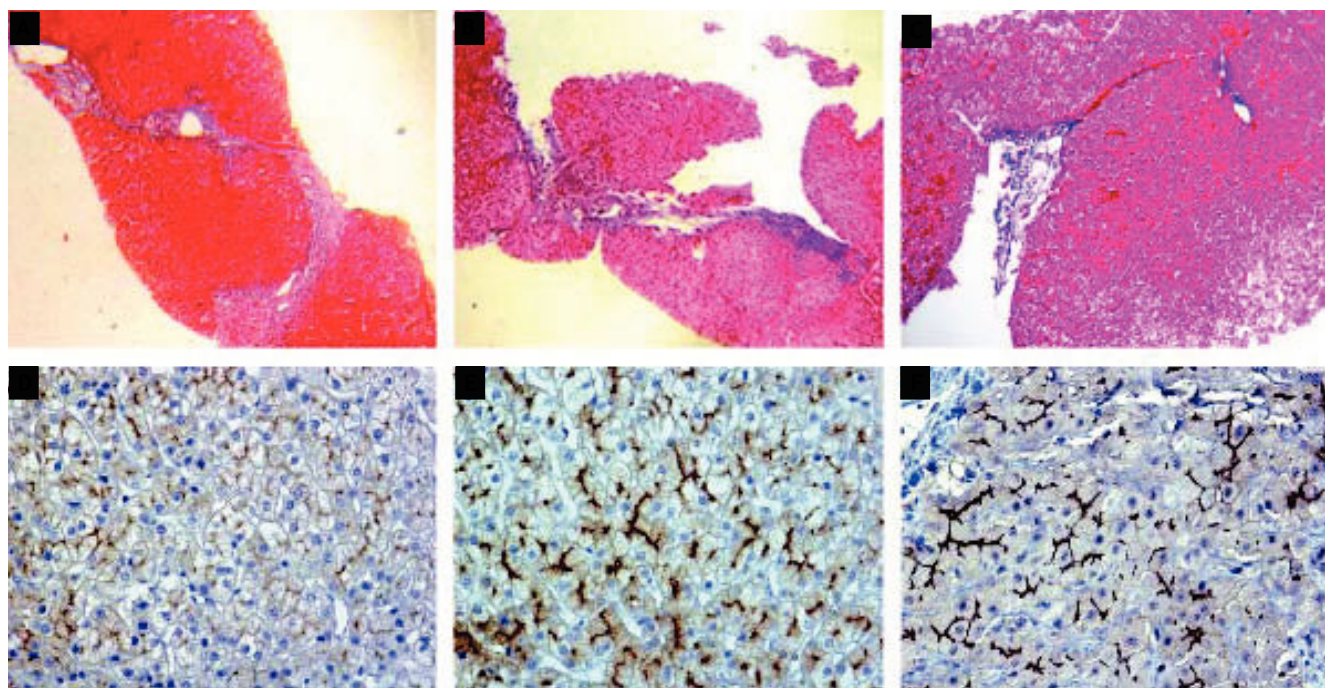


Figure 1. Histological features of representative liver biopsy specimens of Patient 1. Masson trichrome staining in biopsies performed before (A, B) and after (C) 54 months of treatment with UDCA. In A and B, incomplete cirrhosis is observed with regenerative nodules delimited by fibrous septae (METAVIR fibrosis score: F4, thirty evaluable portal tracts, representative fields are shown). In (C) reversion of cirrhosis is observed after the treatment with UDCA, with incomplete thin fenestrated septae; the remanent liver architecture is conserved (METAVIR fibrosis score: F1, eight evaluable portal tracts, a representative field is shown). D. Faint and discontinuous MDR3 immunostaining in Patient 1. E. Normal MRP2 immunostaining in the same patient. F. Normal MDR3 staining in a patient with cholestasis not PFIC-3 (anti-MDR3 or anti-MRP2/hematoxylin, original magnification of D, E, F, 400x).

10% fetal bovine serum and antibiotics. Transient transfections were carried out using Lipofectamine (Invitrogen, Carlsbad, CA, USA), according to the supplier's protocol. For immunofluorescence, MDCK-II cells were seeded on glass coverslips and, 48 h after transfection, fixed with 2% paraformaldehyde and stained for MDR3 with the monoclonal antibody P3II-26 (dilution 1:100). The cells were subsequently incubated with anti-mouse AlexaFluor594-conjugated immunoglobulins (Molecular Probes, Eugene, OR, USA) at 1:200 dilution. Glass coverslips were mounted in Vectashield/DAPI (Vector Laboratories Inc., Burlingame, CA, USA) and examined with a confocal laser-scanning microscope.

Western blot analysis

SDS-PAGE and Western blotting were performed as previously described¹³ using 30 µg of total proteins. Anti-MDR3 and anti-Na/K-ATPase (Santa Cruz Biotechnology, Santa Cruz, CA, USA) antibodies were used at a 1:20,000 and 1:3,000 dilution, respectively. Immune complexes were visualised by chemiluminescence, using the ECL Advanced Western Blotting Detection Kit (GE Healthcare, Buckinghamshire, UK).

RESULTS

Histologic and biochemical analysis, Immunohistochemistry and Transient elastography

An initial liver biopsy of P1 in 2004 showed severe fibrosis with incomplete cirrhosis and cholestasis (Figures 1A and 1B). Immunohistochemical analysis of the liver biopsy showed positive canalicular detection but reduced expression of MDR3 protein (Figures 1D, 1F). Canalicular staining for MRP2 was normal (Figure 1E). Biochemical and histologic features were consistent with high GGT progressive familial intrahepatic cholestasis (PFIC-3) and biliary cirrhosis.

After a few months of treatment with UDCA, the patient progressively improved the symptoms and biochemical alterations of cholestasis (Figure 2). A liver biopsy performed in 2009 (4.5 years after initiated the treatment) showed absence of specific lesions of fibrosis or cirrhosis (Figure 1C, eight portal tracts were analysed, a representative field is shown) and liver function tests remain unchanged since then (Figure 2).

A transient elastography for the staging of liver fibrosis made in June 2013 revealed absence of cirrhosis.

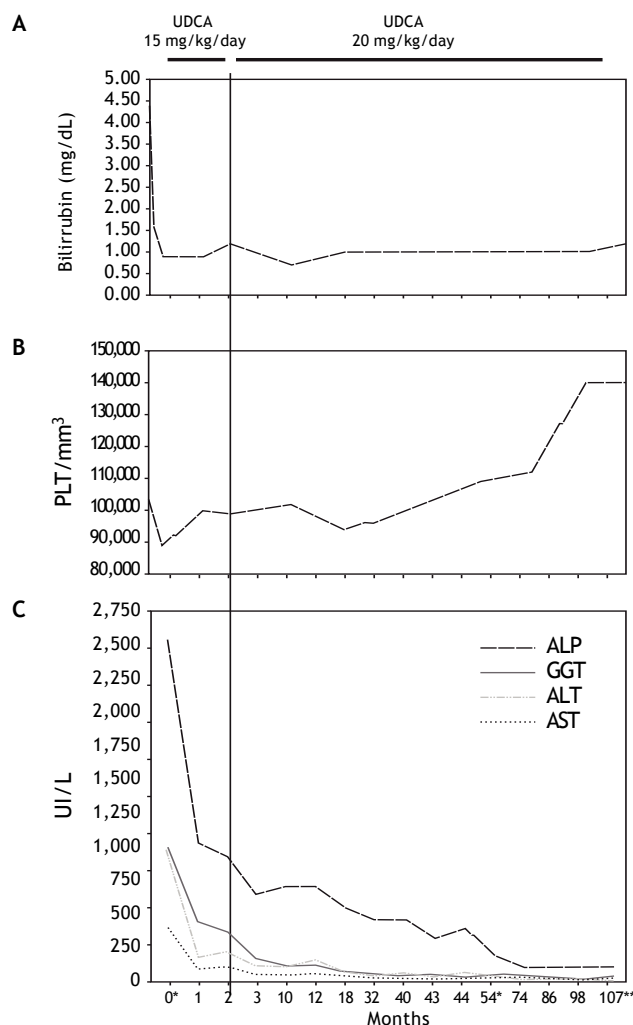


Figure 2. Biochemical improvement of Patient 1 during treatment with ursodeoxycholic acid. Evolution of the levels of total bilirubin, platelets, serum alkaline phosphatase (ALP), γ -glutamyl transpeptidase (GGT), alanine aminotransferase (ALT) and aspartate aminotransferase (AST) during treatment with two different doses of UDCA. At month 0, the levels of bilirubin, platelets and liver enzymes previous to the treatment are represented; (*) indicates the moment when first and last biopsy were performed, whereas (**) indicates the moment in which a transient elastography was carried out. PT-INR remained normal during the whole study period (1-1.2 mg/dL).

Ten measures were done, with a 6.2 KPa statistical median obtained (IQR 0.4). Simultaneous blood analyses revealed normal levels of GGT (38 IU/L), FAL (116 IU/L), ALT (19 IU/L) and AST (22 IU/L) (Figure 2).

For P2, the first biopsy showed ductopenia in less than 20% of bile ducts and conserved histoarchitecture. After two years of treatment with UDCA, a new biopsy showed a moderate diffuse ductular reaction, absence of progression and minimal histological changes. Blood

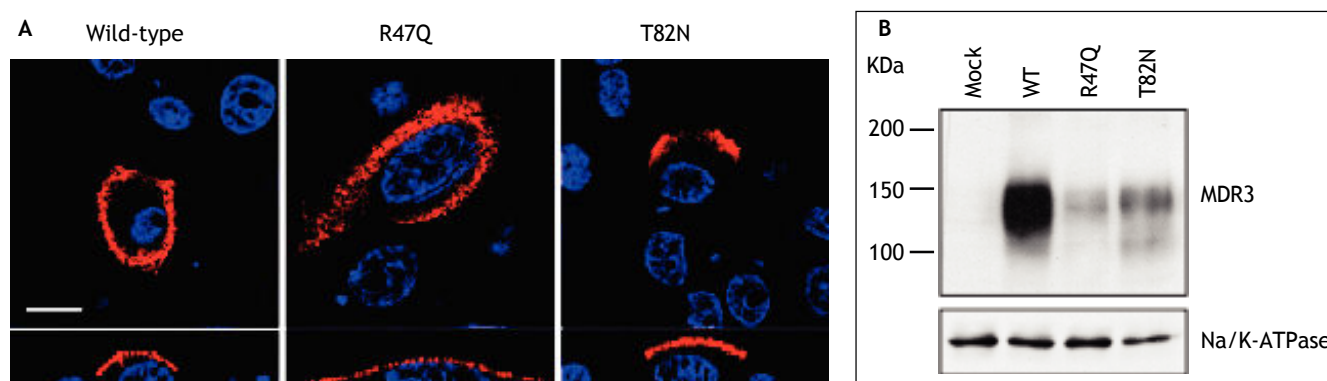


Figure 3. Effects of R47Q and T82N mutations on MDR3 subcellular localization and expression. **A.** MDCKII cells expressing wild-type and mutant MDR3 proteins were analysed by confocal immunofluorescence microscopy. Red and blue fluorescence represent MDR3 and nuclei, respectively. Upper panels show optical x-y sections. Apical surface localization of the MDR3 mutants is clearly detected in the corresponding Z-section images (lower panels). Scale bar = 10 µm. Images shown are representative of three independent experiments. **B.** Western blot analysis with the monoclonal anti-MDR3 antibody from mock-transfected HEK293T cells and from cells expressing wild-type or the mutated versions of MDR3. Apparent molecular masses are indicated at left.

analyses showed normal levels of GGT (26 IU/L), FAL (97 IU/L), ALT (18 IU/L) and AST (18 IU/L).

Genetic analysis

Sequence analysis revealed that P1 was a compound heterozygote for two missense mutations in exon 4 of *ABCB4*: c.140G > A and c.245C > A, (p.R47Q and p.T82N respectively; the first of them located in a cytoplasmic domain and the latter in an extracellular domain). Nucleotide and aminoacidic sequence reference were NG_007118.1 and NP_061337.

Genetic analysis of P2 showed a missense mutation in *ABCB4* shared with her nephew, c.245C>A (p.T82N).

In vitro studies of *ABCB4* mutations

In order to determine whether these substitutions affected subcellular localization or expression of MDR3, MDCKII and HEK293T cells were transfected with expression vectors containing wild-type or the mutated versions of MDR3 (R47Q and T82N) and were analyzed by either immunofluorescence or Western blot.

Due to the low transfection efficiency in MDCK-II cells, for studying the effects of both mutations on MDR3 expression, HEK293T cells were used. Transfection efficiency, as assessed by fluorescence microscopy after MDR3 staining with an anti-MDR3 antibody, was estimated to range between 70-80% with the different cDNA constructs. Results ob-

tained from immunofluorescence showed that both MDR3 mutants display normal apical localization, similar to the wild-type protein (Figure 3A), but Western blotting revealed a marked decrease in their expression levels (Figure 3B). Thus, R47Q and T82N mutations do not alter MDR3 localization, but lead to reduced protein levels.

DISCUSSION

This report documents clinical, biochemical and histological improvement with reversion of advanced fibrosis and incomplete cirrhosis in one PFIC-3 patient after long-term treatment with UDCA. In this disorder, the severity of cholestasis, the time of presentation and the favourable response to UDCA therapy seems to depend on the degree of penetrance of the genetic defect.^{4,6} The phenotypic characterization of the mutations found in our patient confirms this assumption, since R47Q and T82N do not impair the canalicular expression of MDR3, but they result in a dramatic reduction in the levels of the protein, a finding that correlates with data from the immunohistochemical analysis of the liver biopsy. Interestingly, none of the mutations observed in our patient have been previously described either in the Human Gene Mutation Database or in previous clinical studies. However, it was reported that mutations at R47 impair phosphorylation of N-terminal domain of MDR3, which is determinant for PC secretion.¹⁴ It was reported that R47G mutated protein has similar localization and stability to wild-type protein, but PC secretion activity

resulted markedly decreased because of this lack of phosphorylation of neighboring residues, either Thr44 or Ser49.

The finding of the mutation T82N in the affected aunt with PFIC3 is a strong evidence of the association of this mutation with the cholestatic disease. As was previously reported, patients with missense mutations in *ABCB4* that presumably reduce but not abolish MDR3 activity have a slow progression of the liver disease and may benefit from chronic treatment with UDCA.¹

The benefit of UDCA can be explained by experimental and clinical evidence suggesting that at least four mechanisms of action are involved in the beneficial therapeutic effects of UDCA in cholestatic disorders:

- An increased hydrophilicity index of the circulating bile acids pool;
- Stimulation of hepatocellular and ductular secretions;
- Cytoprotection against bile acids and cytokine-induced injury; and
- Immunomodulation and anti-inflammatory effects.

The predominant mechanism of action of UDCA may vary according to the pathophysiology of the underlying cholestatic disorder.¹⁵ In this patient, UDCA administration led to substantial clinical and biochemical improvements, with fibrosis regression and apparent disappearance of cirrhosis, as assessed both histologically and by transient elastography. The possibility to reverse hepatic fibrosis and cirrhosis in patients with chronic liver disease is still controversial. However, evidence of fibrotic regression after successful treatment of the underlying liver disease has been documented for several chronic disorders, including viral hepatitis, autoimmune hepatitis and NASH.^{16,17} Furthermore, recent studies support reversal of cirrhosis in HBV-infected patients upon achieving a sustained viral response from antiviral therapy.¹⁸ To our knowledge, this is the first description of advanced fibrosis reversal in a cholestatic condition after a long-term treatment with UDCA.

ABBREVIATIONS

- **ALP:** alkaline phosphatase.
- **ALT:** alanine aminotransferase.
- **AST:** aspartate aminotransferase.
- **GGT:** γ -glutamyl transpeptidase.

- **HAV:** hepatitis A virus.
- **HBV:** hepatitis B virus.
- **HCV:** hepatitis C virus.
- **ICP:** intrahepatic cholestasis of pregnancy.
- **LPAC:** low phospholipid-associated cholelithiasis.
- **MDR3:** multidrug resistance protein 3.
- **MRP2:** multidrug resistance-associated protein 2.
- **NASH:** nonalcoholic steatohepatitis.
- **NV:** normal value.
- **PC:** phosphatidylcholine.
- **PFIC-3:** progressive familial intrahepatic cholestasis type 3.
- **UDCA:** ursodeoxycholic acid.

CONFLICT OF INTEREST

The authors declared that they do not have anything to disclose regarding conflict of interest with respect to this manuscript.

FINANCIAL SUPPORT

This work was supported by funds from Agencia Nacional de Promoción Científica y Tecnológica (ANPCyT, PICT 2340), Argentina to VM and from the Spanish Fondo de Investigaciones Sanitarias (PI12/01196) to LA.

REFERENCES

1. Jacquemin E. Progressive familial intrahepatic cholestasis. *Clin Res Hepatol Gastroenterol* 2012; 36: 26-35.
2. Daleke D. Regulation of transbilayer plasma membrane phospholipid asymmetry. *J Lipid Res* 2003; 44: 233-42.
3. Chan J, and VandeBerg J. Hepatobiliary transport in health and disease. *Clin Lipidol* 2012; 7: 189-202.
4. Davit-Spraul A, Gonzales E, Baussan C, Jacquemin E. The spectrum of liver diseases related to *ABCB4* gene mutations: pathophysiology and clinical aspects. *Semin Liver Dis* 2010; 30:134-46.
5. Sundaram SS, Sokol RJ. The Multiple Facets of *ABCB4* (MDR3) Deficiency. *Curr Treat Options Gastroenterol* 2007; 10: 495-503.
6. Stapelbroek J, van Erpecum K, Klomp L, Houwen R. Liver disease associated with canalicular transport defects: Current and future therapies. *J Hepatol* 2010; 52: 258-71.
7. Jacquemin E, De Vree JM, Cresteil D, Sokal E, Sturm E, Dumont M, Scheffer G, et al. The wide spectrum of multidrug resistance 3 deficiency: from neonatal cholestasis to cirrhosis of adulthood. *Gastroenterology* 2001; 120: 1448-58.
8. Colombo C, Vajro P, Degiorgio D, Coviello D, Costantino L, Tornillo L, Motta V, et al. Clinical features and genotype-phenotype correlations in children with progressive familial intrahepatic cholestasis type 3 related to *ABCB4* mutations. *J Pediatr Gastroenterol Nutr* 2011; 52: 73-83.
9. Oude Elferink RP, Paulusma CC. Function and pathophysiological importance of *ABCB4* (MDR3 P-glycoprotein). *Pflügers Arch* 2006; 453: 601-10.

10. Gonzales E, Davit-Spraul A, Baussan C, Buffet C, Maurice M, Jacquemin E. Liver diseases related to MDR3 (*ABCB4*) gene deficiency. *Front Biosci* 2009; 14: 4242-56.
11. Gordo-Gilart R, Andueza S, Hierro L, Martínez-Fernández P, D'Agostino D, Jara P, Alvarez L. Functional analysis of *ABCB4* mutations relates clinical outcomes of progressive familial intrahepatic cholestasis type 3 to the degree of MDR3 floppase activity. *Gut* 2015; 64: 147-55.
12. Alvarez L, Jara P, Sanchez-Sabaté E, Hierro L, Larrauri J, Díaz MC, Camarena C, et al. Reduced hepatic expression of farnesoid X receptor in hereditary cholestasis associated to mutation in ATP8B1. *Hum Mol Genet* 2004; 20: 2451-60.
13. Martínez-Fernández P, Hierro L, Jara P, Alvarez L. Knockdown of ATP8B1 expression leads to specific down-regulation of the bile acid sensor FXR in HepG2 cells. Effect of the FXR agonist GW4064. *Am J Physiol Gastrointest Liver Physiol* 2009; 296: G1119-G1129.
14. Gautherot J, Delautier D, Maubert MA, Ait-Slimane T, Bolbach G, Delaunay JL, Durand-Schneider AM, et al. Phosphorylation of *ABCB4* impacts its function: insights from disease-causing mutations. *Hepatology* 2014; 60: 610-21.
15. Poupon R. Ursodeoxycholic acid and bile- acid mimetics as therapeutic agents for cholestatic liver diseases: An overview of their mechanisms of action. *Clin Res Hepatol Gastroenterol* 2012; 36: 3-12.
16. Friedman SL, Bansal MB. Reversal of hepatic fibrosis -fact or fantasy? *Hepatology* 2006; 43: 82-8.
17. Chang TT, Liaw YF, Wu SS, Schiff E, Han KH, Lai CL, Safadi R, et al. Long-term entecavir therapy results in the reversal of fibrosis/cirrhosis and continued histological improvement in patients with chronic hepatitis B. *Hepatology* 2010; 52: 886-93.
18. Marcellin P, Gane E, Buti M, Afdhal N, Sievert W, Jacobson IM, Washington MK, et al. Regression of cirrhosis during treatment with tenofovir disoproxil fumarate for chronic hepatitis B: a 5-year open-label follow-up study. *Lancet* 2013; 381: 468-75.