



Clinical Presentation and Anatopathologic Finding of a Hepatic Vascular Hamartoma: a Case Report.

Valentina Ferri,* Benedetto Ielpo,* Hipolito Duran,* Eduardo Diaz,* Isabel Fabra,* Carlos Plaza,** Yolanda Quijano,* Emilio Vicente*

* Division of General Surgery, Sanchinarro Hospital, San Pablo University, Madrid, Spain.

** Division of Anatomic Pathology, Sanchinarro Hospital, San Pablo University, Madrid, Spain.

ABSTRACT

HVH (hepatic vascular hamartoma) is a tumor like malformation arising from the vascular tissue of the liver. HVH has been previously reported in animals and presents distinctive features from the most frequent benign tumor like malformation of the liver, the hepatic mesenchymal hamartoma (HMH). Herein we report a case of HVH localized in hepatic segment 4b, involving the gastro hepatic ligament, successfully treated with total excision. We describe the anatomo-pathologic findings focusing on the clinical and radiological presentation, the intraoperative characteristics and the differential diagnosis.

Key words. Benign liver tumor. Tumor like malformation. Case report. Vascular hamartoma.

INTRODUCTION

Hamartoma derives from the Greek word “αμαρτία”, Hamartia, and refers to a defect or an error. It is a tumor-like malformation resembling a neoplasm, composed by an overgrowth of indigenous mature cells and tissues which show disorganized architectural pattern with predominance of one of its components.¹ Hamartoma can arise from any organ and tissue, in particular, it has been commonly observed in lung, pancreas, spleen, liver and kidney.

In liver hamartomas usually originates from mesenchymal tissue: hepatic mesenchymal hamartoma (HMH) was initially described by Edmondson² and is generally regarded as the second most common benign liver lesion in children.³

In this article, we describe a case of hepatic hamartoma arising from vascular tissue (hepatic vascular hamartoma, HVH), that to the best of our knowledge has never been reported in human.

CASE REPORT

A 48-year-old female with a history of intermittent right upper abdominal pain was referred to our service. The physical examination and medical history weren't sig-

nificant. The laboratory tests, including complete blood count, liver function, serological markers for viral B, C hepatitis and tumoral markers, were within the normal limits. Antiechinococcal antibodies were negative.

On abdominal ultrasound, a 10 cm multiloculated hepatic cyst was reported. A computed tomography scan (Figure 1) and a magnetic resonance imaging showed a multiloculated liver mass, involving the porta hepatis and extending to the IV duodenal portion. Additionally, endoscopic ultrasound confirmed the intrahepatic lesion involving the gastro-hepatic ligament and excluded a vascular compromise; the endoscopic ultrasound-guided fine-needle aspiration was compatible with a benign epithelial tumor.

The surgical resection was planned and a bilateral subcostal laparotomy performed. A heterogeneous, capsulated, 8 cm hepatic mass located in segment 4b was surrounding gallbladder and involving portal vein, right and left hepatic artery and the proper hepatic artery without signs of direct infiltration. The mass depended on the hepatic parenchyma and no communication between hepatic artery, portal vein and the tumor was observed. An accurate dissection of hilar structures, guided by intraoperative cholangiography, was performed and “en block”

resection of the involved hepatic segment, gallbladder and the extrahepatic part of the lesion was finally obtained.

The postoperative course was uneventful and the patient was discharged on 8th postoperative day. Currently,

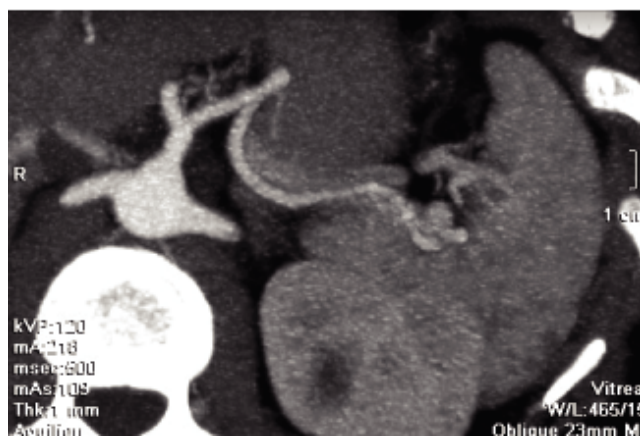
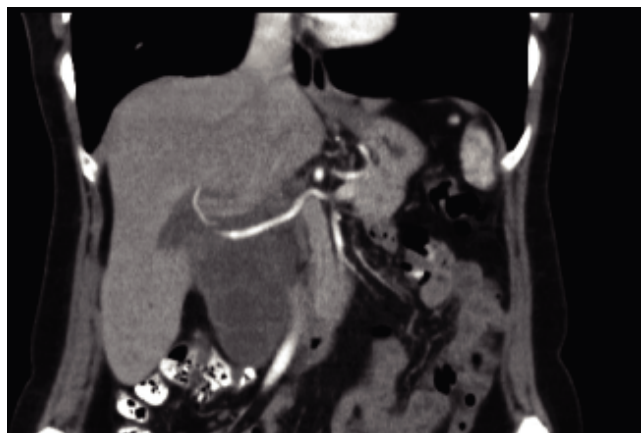


Figure 1. Coronal abdominal contrast computed tomography image and vascular reconstruction. The hepatic artery, originating from the celiac trunk, pass through the lesion without infiltration sings.

the patient is asymptomatic with no evidence of recurrence at 4 years of follow up.

On cut section, a multiloculated cystic mass of cm 7 x 6.9 x 5.9 cm was revealed with cystic spaces contained hematic and necrotic material. The lesion was coated with a smooth membrane compressing the adjacent normal hepatic parenchyma.

In the hematoxylin eosin stained vascular spaces lined with plump endothelial cells without atypia and the intra-vascular areas enclosed focal adipose tissue with a connecting network of fibrosis were observed. There were extended areas of necrosis and hemorrhage as well as hemosiderophages (Figure 2). Mesenchymal, fusiform cells expressing actine and caldesmon delimited vascular spaces enclosing arteries and veins with different size and shape (Figure 3).

The lining endothelial cells of the vascular channels were positive for CD31 and CD34 immunostain (Figure 4). The final pathological diagnosis was a HVH.

DISCUSSION

Hamartoma is a benign, polyclonal lesion derived from an uncontrolled proliferation of cell of the tissue of origin and can arise from any tissue and organ. This tumor- like lesion has been associated with numerous genetic syndromes such as the tuberous sclerosis and the PTEN hamartoma tumor syndrome (PHTS), including Cowden syndrome (CS), Bannayan-Riley-Ruvalcaba syndrome (BRRS) and adult Lhermitte-Duclos disease (LDD).⁴ Hamartoma can be pathologically sub-classified, depending on the relative abundance of a particular endogenous tissue (mesenchymal, vascular, neurovascular, etc.).

In case of vascular hamartoma, normal vascular tissue and blood vessel are arranged in a disorganized structure forming mass and represents congenital defects of vascular formation and development.⁵

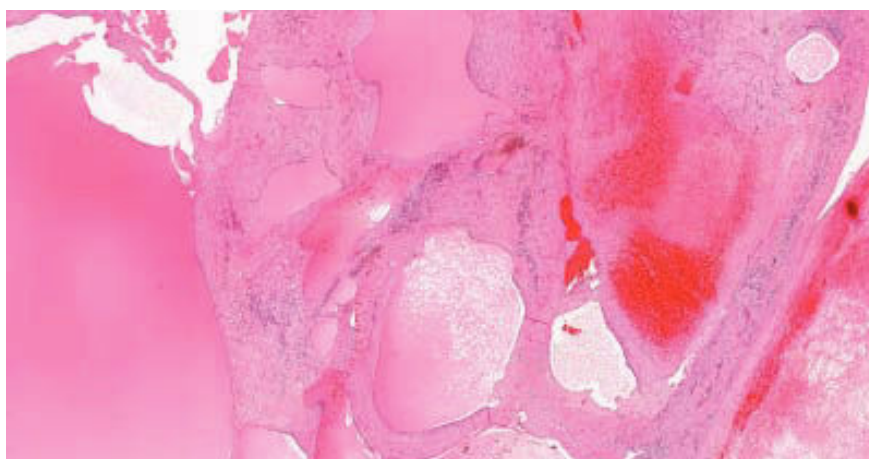


Figure 2. Hematoxylin eosin stained of the hepatic mass section: the tumor is composed of fusiform cells delimitating vascular spaces, with arteries and veins of different shapes. Necrosis and hemorrhagic areas with hemosiderophages can be observed.

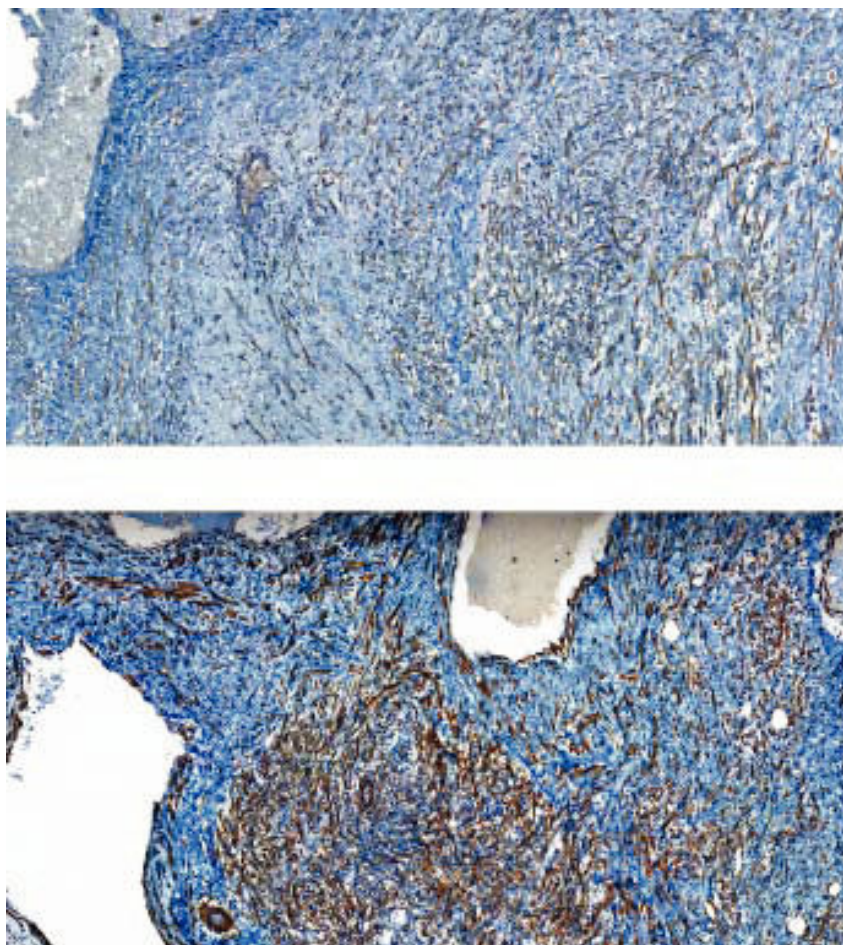


Figure 3. Immunohistochemistry expression of mesenchymal cells interposed between vascular spaces: actin expression (upper figure) and same cells positive for caldesmon expression (lower figure).

Although uncommon, vascular hamartoma has been described in several organs: in spleen, lung, gastrointestinal tract, mediastinum, lower genital tract, in tongue, paranasal sinus, and parotid gland. As far as we are aware, this is the first case of hepatic vascular hamartoma (HVH) reported in humans, even if several cases have been reported in different animal species such as in dogs,^{6,7} and cow.⁸

Differential diagnosis, on the gross and histopathologic finding, includes HMH and hemangioma. Firstly hemangioma shows common histologic findings with vascular hamartoma such as the presence of dilated vascular spaces of varying size, lined by cells without atypia and expressing endothelial markers. Unlike vascular hamartoma, hemangioma's structure is characterized by a large and compact clonal cell population, while in the case herein reported the histopathological finding is represented by a set of arterial and venous vessels (non-clonal origin) and is accompanied by intralesional adipose tissue. Otherwise, in HVH, blood vessels have a normal structure (endothelium, connective tissue, muscle tissue,^{5,9} while hemangioma lacks the muscular part of the vessels. Regarding the second differential diagnosis, the hepatic mesenchymal

hamartoma, this tumor originates from mesenchymal tissues and can appear as a solid or cystic lesion.¹⁰ Histological, HMV consists of malformed bile ducts included in a fibromyxoid stroma. Epithelial-lined cysts, and foci of nonepithelial-lined cystic spaces within the stroma (which may resemble lymphangioma), and entrapped islands of otherwise normal-appearing hepatocytes have also been described.¹¹ In vascular hamartoma neither biliary element nor hepatocytes are present.

In most cases vascular hamartoma is asymptomatic or associated with only minor symptoms, depending on the localization.⁵ In the case of splenic vascular hamartoma only 20% of the lesion are able to manifest clinical symptoms, such as palpable mass, spontaneous rupture with intra-abdominal bleeding, and hypersplenism (thrombocytopenia, anemia, pancytopenia).^{9,12} In lung most pulmonary vascular hamartoma is nonexpanding or slowly growing neoplasms, but some authors believe that surgery is necessary when expansion is detected or accompanying by pulmonary symptoms. In fact, in some cases, a malignant behavior, such as invasion of pulmonary arteries and esophagus has been described.¹³

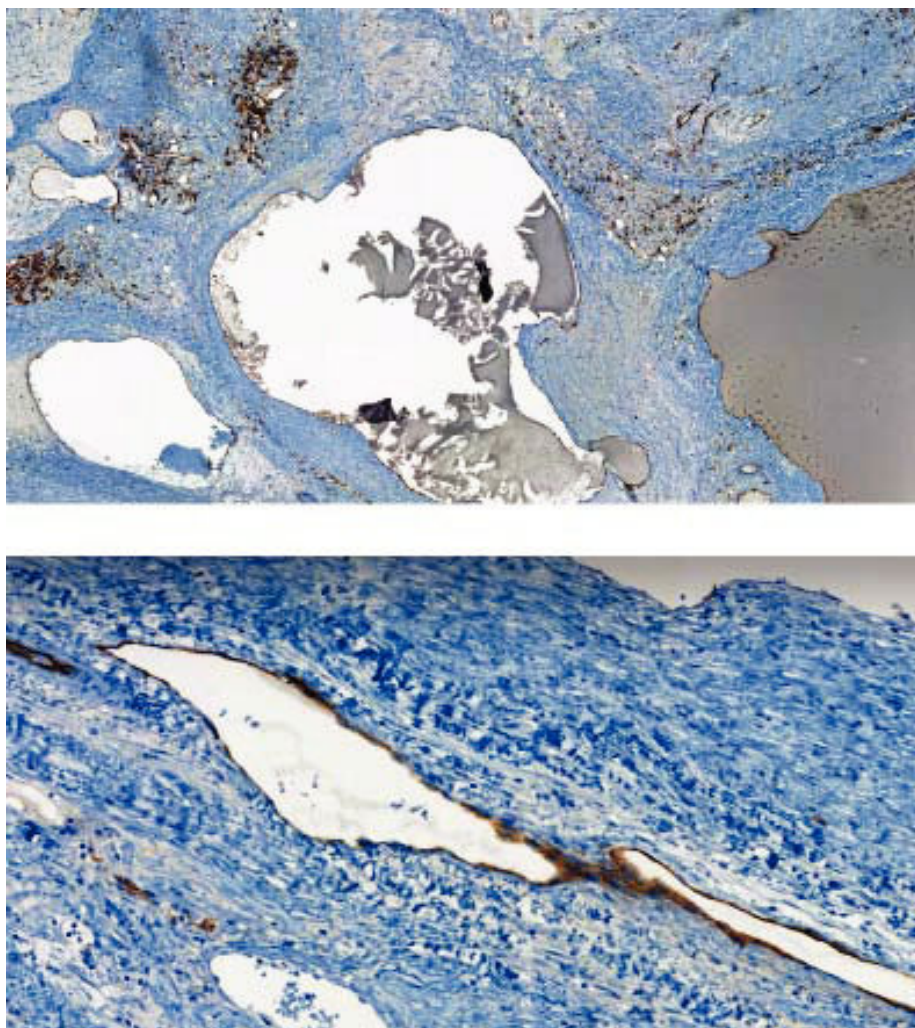


Figure 4. Immunohistochemistry expression of the cells involving the vascular spaces: CD 31 expression (upper figure) and CD 34 expression (lower figure).

Despite the benign nature, even for hepatic vascular hamartoma, a strict follow up and an early surgery can be recommended to avoid an uncontrolled growth of the lesion with functional damage of the organ involved or severe bleeding complications.

CONCLUSION

In conclusion, hepatic vascular hamartoma is a benign vascular proliferation with the characteristic positive immunophenotype of the lining endothelial cells. In this case report, we describe the first case of hepatic vascular hamartoma ever reported in human. Although this tumor is very rare, it must be included in the differential diagnosis of hepatic mass-forming lesions; it is essential to be able to recognize HVH to learn more about its natural history and response to treatment.

ABBREVIATIONS

- **BRRS:** Bannayan-Riley-Ruvalcaba syndrome.
- **CS:** Cowden syndrome.
- **HMH:** hepatic mesenchimal hamartoma.
- **HVH:** hepatic vascular hamartoma.
- **LDD:** Lhermitte-Duclos disease.
- **PHTS:** PTEN hamartoma tumor syndrome.

CONFLICT OF INTEREST

The authors declares that there is no conflict of interest regarding the publication of this article.

REFERENCES

1. Prabhu VR, Burt AR. Pathology of liver tumors. *Surgery* 2007; 25: 10-15.

2. Edmondson HA, Peters RL. Tumors of the liver: pathologic features. *Semin Roentgenol* 1983; 18: 75-83.
3. Qureshi SS, Bhagat M, Kembhavi S, Vora T, Ramadwar M, Chinnaswamy G, Prasad S, et al. Benign liver tumors in children: outcomes after resection. *Pediatr Surg Int* 2015; 31: 145-9.
4. Mester J, Charis E. PTEN hamartoma tumor syndrome. *Handb Clin Neurol* 2015; 132: 129-37.
5. Mannan AA, Sharma MC, Singh MK, Bahadur S, Hatimota P. Vascular hamartoma of the paranasal sinuses: report of 3 rare cases and a short review of the literature. *Ear Nose Throat J* 2009; 88:740-3.
6. McGavin MD, Henry J. Canine hepatic vascular hamartoma associated with ascites. *J Am Vet Med Assoc* 1972; 160: 864-6.
7. Gualtieri M, Cocci A, Monti S, Olivero D. Surgical removal of a localised vascular hepatic hamartoma in a dog. *Aust Vet J* 2009; 87: 360-2.
8. Braun U1, Trösch L, Gerspach C, Brosinski K, Hilbe M. Ultrasonographic findings in a cow with vascular hamartoma of the liver: case report. *BMC Vet Res* 2011; 4; 7: 52.
9. Bowerson M, Menias CO, Lee K, Fowler KJ, Luna A, Yano M, Sandrasegaran K, Elsayes KM6. Hot spleen: hypervascular lesions of the spleen. *Abdom Imaging* 2015; 40: 2796-813.
10. Papastratis G, Margaris H, Zografos GN, Korkolis D, Mannika Z. Mesenchymal hamartoma of the liver in an adult: a review of the literature. *Int J Clin Pract* 2000; 54: 552-4.
11. Brkic T, Hrstic I, Vucelic B, Jakic-Razumovic J, Skegro M, Romic B. Benign mesenchymal liver hamartoma in an adult male: a case report and review of the literature. *Acta Med Austriaca* 2003; 30: 1347.
12. Lee H, Maeda K. Hamartoma of the spleen. *Arch Pathol Lab Med* 2009; 133: 147-51.
13. Ladeira I, Neves S, Almeida J, Parente B, Couceiro A, Moura Sá J. Diffuse vascular hamartoma with malignant behavior. *Respir Med Case Rep* 2015; 22: 125-7.

Correspondence and reprint request:

Valentina Ferri, M.D.

Division of General Surgery, Sanchinarro Hospital, San Pablo University, Madrid, Spain, Calle oña 10, 28050 Madrid, Spain, Tel.: 00393381941040.

E-mail: valenpeglio@gmail.com