



Hepatic Cyst Compressing The Right Atrial and Ventricular Inflow Tract: An Uncommon Cardiac Complication

Maulik Panchal,^{*} Ahmed Alansari,^{*} Marc Wallack,^{**} Ferdinand Visco,^{***} Susan Williams,^{****} Alexander M. Sy^{*}

^{*} Department of Medicine. Metropolitan Hospital Center, New York Medical College, New York, NY, USA.

^{**} Department of Surgery. Metropolitan Hospital Center, New York Medical College, New York, NY, USA.

^{***} Division of Cardiology, Department of Medicine. Metropolitan Hospital Center, New York Medical College, New York, NY, USA.

^{****} Division of Gastroenterology, Department of Medicine. Metropolitan Hospital Center, New York Medical College, New York, NY, USA.

ABSTRACT

Commonly reported complications of hepatic cysts are spontaneous hemorrhage, rupture into the peritoneal cavity, infection and compression of the biliary tree however cardiac complications are not commonly reported. We are presenting a case of a large liver cyst presenting with right atrial and ventricular inflow tract impingement resulting in cardiac symptoms. A 68 year-old Hispanic female presented with one month of fatigue and shortness of breath after household work and walking less than one block, right upper quadrant pain and weight loss. She had history of multiple hepatic cysts for more than 12 years, well-controlled diabetes and hypertension. Examination of the heart revealed tachycardia with regular heart sounds. There were no murmurs. She had tenderness in her right upper quadrant on palpation and an enlarged smooth liver. Rest of physical examination was unremarkable. CT scan of the abdomen showed multiple non-enhancing liver cysts in both lobes, with the largest measuring 12 x 15 x 17 cm which was significantly increased from her baseline of 7 x 8 x 10 cm in 2003. Echocardiogram showed normal left ventricular ejection fraction, grade 1 diastolic dysfunction and a hepatic cyst impinging RA and RV inflow tract. She had successful laparoscopic enucleation of liver cyst and subsequent relief from tachycardia, fatigue and shortness of breath. In conclusion, this case illustrates that hepatic cysts may become symptomatic after remaining quiescent for an extended period. They may present with unusual symptoms and clinicians should be mindful of rare complications, such as in this case.

Key words. Liver cyst. Right atrium. Right ventricle. Cardiac Compression.

INTRODUCTION

The prevalence of simple hepatic cysts in the general population varies from 2-18%. While they are usually asymptomatic, large hepatic cysts may become symptomatic. The usual complications include hemorrhage, torsion, infection, rupture into the peritoneal cavity and compression of the biliary tree. Cardiac complications are not commonly reported. We describe a patient with a large hepatic cyst who presented with heart failure-like symptoms caused by obstruction of the right atrial and ventricular inflow tract by a large hepatic cyst.

CASE REPORT

A 68 year-old Hispanic female presented to our clinic for evaluation of worsening right upper quadrant pain. She had intermittent right upper quadrant pain for about one year, but reported recent, progressive worsening of pain and discomfort over the past few weeks. She denied nausea or vomiting. However, despite having a normal appetite, she was only able to eat small portions due to a pressure-like sensation in her stomach and she lost 10 to 15 pounds over the last year. She also noted a decline in her exercise tolerance, which she described as fatigue, following her

usual household activities. She had a history of well-controlled diabetes mellitus, hypertension and multiple hepatic cysts. The largest cyst was located in the right lobe of the liver measuring 8 x 9 x 10 cm on computed tomography done 10 years prior (Figure 1). Physical examination revealed an afebrile female with a blood pressure of 92/62 mmHg and heart rate of 111 beats per minute. There was no jaundice, jugular venous distention or lower extremity edema. Cardiac examination revealed sinus tachycardia with normal heart sounds and no murmurs. The abdominal examination revealed tenderness in the right upper quadrant with an enlarged smooth liver. The rest of the examination was unremarkable. Laboratory work up showed normal blood count, basic metabolic panel and thyroid function. Liver function tests revealed normal serum transaminases, bilirubin and albumin concentrations, but the alkaline phosphatase activity was mildly elevated at 159 units/L (normal: 50-136 units/L). The *Echinococcus* antibody was negative. A computed tomography of the abdomen was significant for multiple non-enhancing liver cysts in both lobes, with the largest measuring 14 x 15 x 18 cm located in the right lobe with no peripheral enhancing components on contrast study (Figure 2). Electrocardiogram showed sinus tachycardia with no acute ST-T wave changes. Due to her unexplained tachycardia, relative hypotension, and decreased exercise tolerance, an echocardiogram was performed to rule out heart failure, which revealed a normal left ventricular ejection fraction with no wall motion abnormalities or valvular dysfunction. However, a mass-like structure showing the characteristics of a hepatic cyst was seen impinging on the right atrial and ventricular inflow tract (Figure 3). She was evaluated by a surgical team and underwent laparoscopic deroofing of the hepatic cysts. The procedure was uncomplicated and the two largest liver cysts were drained. A total of three liters of fluid was drained and a sample was sent for cytology, gram stain and culture, all of which came back negative. Histopathology of the cyst walls showed simple liver cyst lined by cuboidal epithelium, supported by a fibrous wall. The post-surgical echocardiogram revealed resolution of the compression on the right side of the heart (Figure 4). This was correlated with significant improvement in the patient's symptoms together with improved exercise tolerance.

DISCUSSION

Simple cysts of the liver are cystic formations containing clear fluid that do not communicate with the intrahepatic biliary tree. The prevalence of hepatic cysts ranges from 2-3 % in older studies¹ to as high as 18% in more recent studies.² The wide difference of this prevalence is probably due to sophistication in diagnostic radiology and

increasingly frequent use of imaging. Ultrasound, CT scan and MRI are all highly diagnostic, but ultrasound is most frequently ordered as it is readily available and less expensive. The majority of these simple hepatic cysts are asymptomatic and usually found incidentally on imaging. However, larger cysts may produce more symptoms such as abdominal pain, distension, fullness, early satiety, nausea or vomiting. The most common complications reported with hepatic cysts are rupture,³ infection,⁴ obstructive jaundice, bleeding into the cyst, portal vein occlusion with splenic varices⁵ and inferior vena cava thrombosis.⁶

Cardiac complications are rare and only few reported cases are noted in literature. One case describes premature atrial contractions associated with simple liver cyst.⁷

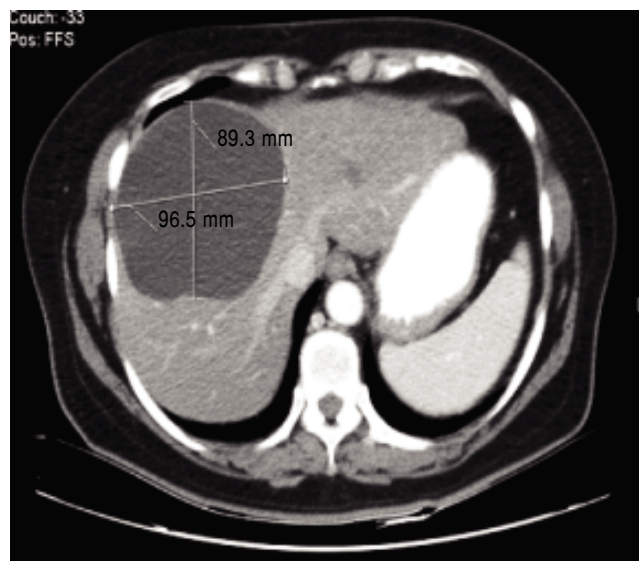


Figure 1. CT abdomen showing liver cyst 10 years prior.

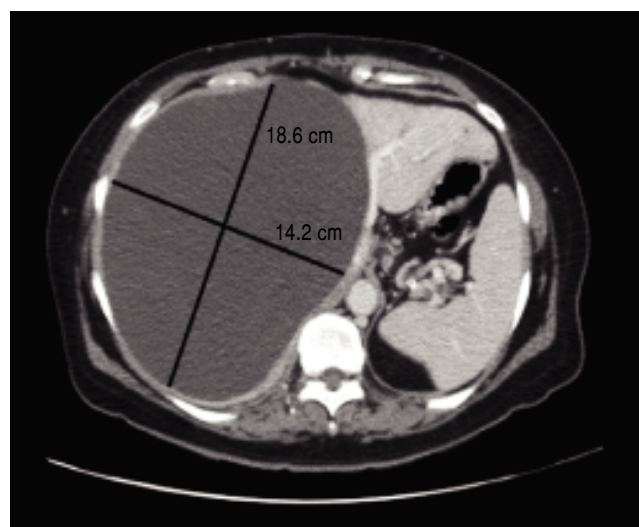


Figure 2. CT Abdomen on presentation showing huge liver cyst.

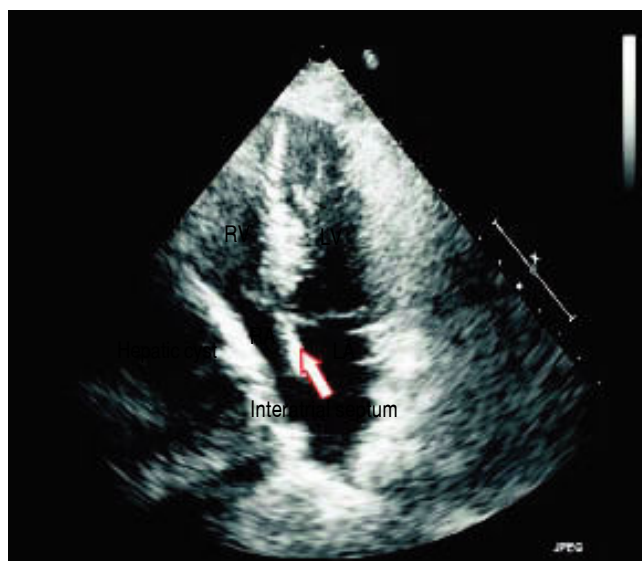

Figure 3. Echocardiogram on presentation showing right heart compression.

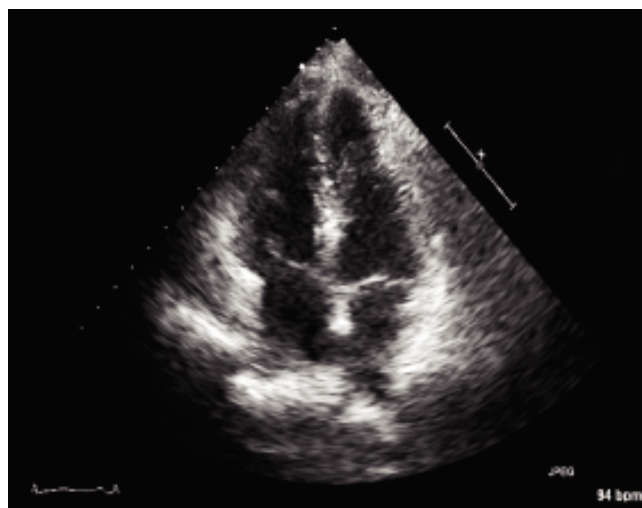


Figure 4. Post-operative echocardiogram showing resolution of compression.

Refractory hypotension is described in two other cases who had liver cyst and autosomal dominant polycystic kidney disease, but both had hypotension in the event of acute illness. One patient had hypotension in setting of bacteremia,⁸ who improved after right nephrectomy. The second patient was admitted with septic shock after nephrectomy and also had left ventricular ejection fraction of 30%. That patient's hypotension along with other causes was thought to be due to hepatic cyst compressing right atrium and ventricle, and who succumbed to illness due to abdominal infection.⁹ Of note, our patient did not have any confounding factors attributing to the symptoms ex-

cept for the liver cyst. Two other cases describe right sided heart failure^{10,11} as a result of liver cyst compressing the right atrium, one of which was in relation to polycystic kidney disease.¹¹ Cardiac tamponade was reported in one case¹² due to rupture of the liver cyst with fluid filling the pericardium in a kidney transplant patient with polycystic kidney. Our patient had compression of both the right atrial and right ventricular inflow tract causing reduced venous return, which is the likely explanation of her presentation with decreased exercise tolerance, fatigue, tachycardia and hypotension. Majority of cases described here had association with polycystic kidney disease, unlike our patient who had primarily a liver pathology. On reviewing literature, none of these cases except one¹⁰ describes having any liver surgery or improvement thereafter. Our patient is different from other cases having regular follow up and complete resolution of cardiac and other symptoms after liver surgery.

Asymptomatic simple liver cysts are usually treated conservatively; surgical intervention is required when they become symptomatic. Surgical interventions include simple drainage, sclerotherapy,¹³ radiofrequency ablation, laparoscopic or open deroofing and hepatic resection. Despite surgical intervention, recurrence of hepatic cysts is seen in 11.3% of cases of non-parasitic cysts. A recently published review reported a lower recurrence rate with laparoscopic *vs.* open surgery, 6.1% *vs.* 11.5% respectively.¹⁴

We presented a patient with heart failure-like symptoms secondary to a large hepatic cyst compressing the right side of the heart. Cardiac complication of hepatic cyst should be considered differentially in all patients with cardiovascular signs and symptoms due to close anatomic proximity of the liver to the heart and major vessels.

FINANCIAL SUPPORT

No grants or financial support for this activity.

REFERENCES

- Caremani M, Vincenti A, Benci A, Sassoli S, Tacconi D. Ecographic epidemiology of non-parasitic hepatic cysts. *J Clin Ultrasound* 1993; 21: 115-8.
- Carrim ZI, Murchison JT. The prevalence of simple renal and hepatic cysts detected by spiral computed tomography. *Clin Radiol* 2003; 58: 626.
- Miliadis L, Giannakopoulos T, Boutsikos G, Terzis I, Kyriazanos ID. Spontaneous rupture of a large non-parasitic liver cyst: a case report. *J Med Case Rep* 2010; 4: 2.
- Lantinga MA, Geudens A, Gevers TJ, Drenth JP. Systematic review: the management of hepatic cyst infection. *Aliment Pharmacol Ther* 2015; 41: 253-61.
- Macutkiewicz C, Plastow R, Chrispijn M, Filobos R, Ammori BA, Sherlock DJ, Drenth JP, et al. Complications arising in simple and polycystic liver cysts. *World J Hepatol* 2012; 27: 406-11.

6. Moon J, Heo D, Han S. A case of hepatic cyst-induced inferior vena cava thrombosis. *Pak J Med Sci* 2014; 30: 667-70.
7. Ker J. The liver and right atrium - hepatic cyst as a cause of arrhythmia. *Clin Med Insights Cardiol* 2010; 4: 63-7.
8. Lasic LB, DeVita MV, Spiegel PJ, Marino ND, Mellow E, Michelis MF. Refractory hypotension and edema caused by right atrial compression in a woman with polycystic kidney disease. *Am J Kidney Dis* 2004; 43: 13-7.
9. Ghatak T, Azim A, Sharma A, Mahindra S: Post-operative refractory hypotension due to right heart Compression by hepatic cysts in a patient with autosomal Dominant polycystic kidney disease. *J Anesthesiol Clin Pharmacol* 2013; 29: 572-4.
10. O'Connor A, Lee M, McEntee G, McNamara DA. Massive hepatic cyst presenting as right-sided heart failure. *Ir J Med Sci* 2012; 181: 365-7.
11. Li Vecchi M, Buscemi S, Nardi E, Azzolina V, Provenzano R. A case of cardiac compression by hepatic cyst in a woman with polycystic kidney disease. *Intern Emerg Med* 2008; 3: 69-71.
12. Egbuna O, Johnson S, Pavlakis M. Rupture of an Infected Liver Cyst into the Pericardium in a Kidney Transplant Recipient with Polycystic Kidney Disease. *Am J Kidney Dis* 2007; 49: 851-3.
13. Spârchez Z, Radu P, Zaharie F, Al Hajjar N, Spârchez M. Percutaneous treatment of symptomatic non-parasitic hepatic cysts. Initial experience with single-session sclerotherapy with polidocanol. *Med Ultrason* 2014; 16: 222-8.
14. Antonacci N, Ricci C, Taffurelli G, Casadei R, Minni F. Systematic review of laparoscopic versus open surgery in the treatment of non-parasitic liver cysts. *Updates Surg* 2014; 66: 231-8.

Correspondence and reprint request:

Maulik Panchal, M.D.
Department of Medicine, Metropolitan Hospital Center,
New York, NY 10029, USA.
Tel.: 212-423-7745. Fax: 212-423-8099
E-mail: drmd.18@gmail.com