

## LETTERS TO THE EDITOR

## Acute disseminated encephalomyelitis with tumefactive lesions after vaccination against human papillomavirus

### Encefalomiелitis aguda diseminada con lesiones tumefactas tras vacunación contra el virus del papiloma humano

Dear Editor:

Acute disseminated encephalomyelitis (ADEM) is an acute monophasic demyelinating disease, with an estimated incidence of 0.8/100,000 inhabitants/year and a prevalence in children and young adults. In most cases, it occurs after an infection (viral or bacterial) or previous vaccination (rabies, smallpox, measles, rubella, whooping cough, hepatitis B and influenza). However, the incidence of ADEM for most vaccines is < 0.1-0.2/100,000 vaccinations<sup>1</sup> and less than 5% of all ADEM are postvaccinal.

The pathogenic mechanism of this entity has not been fully clarified. It is considered an autoimmune disease caused by lymphocyte sensitisation to central nervous system antigens<sup>2</sup>. The clinical presentation symptoms are highly variable and non-specific, and include focal deficits, optic neuritis, seizures, spinal condition and variable alteration of consciousness or mental status. The main diagnostic tool is craniospinal magnetic resonance imaging (MRI), which shows multiple, asymmetrical, supratentorial and infratentorial hyperintense lesions, which may be swollen and affecting mainly the white matter, although thalamic and basal nuclei condition is not uncommon. Characteristically, the lesions are all found in the same developmental stage and tend to resolution. Confirmation within 6 months of lesion involution, as well as the absence of new lesions, ultimately supports the diagnosis of ADEM.

We present the case of a 17-year-old female patient with no relevant medical history except for having presented herpes zoster in the first and second branch of the left trigeminal when she was 5 with accompanying chickenpox spread, and no other complications. She did not report recent infectious clinical signs/symptoms. She had begun immunisation against human papilloma virus (HPV) with Gardasil® 2 months earlier, with a second administration 15 days before admission. She consulted due to visual impairment of one week's development with difficulty in

distinguishing the end of words and an accompanying feeling of "blurred vision", with no other concomitant symptoms. A neurological examination evidenced right homonymous hemianopia (confirmed by automated perimetry), with no other pathologic findings. Laboratory tests (complete blood count, basic coagulation study, biochemical profile and thyroid hormones), immune study (C3, C4, anti-DNA, anti-SM, RNP, Ro, La, anticentromere, anti-SCL-70, antiribosome, anti-histone, anti-gliadin and anti-transglutaminase antibodies) and serology tests (hepatitis B, HIV, Epstein Barr virus, herpes simplex 1 and 2, cytomegalovirus, varicella-zoster virus, VDRL, *Toxoplasma* and *Borrelia*) all resulted normal, except for positive ANA (granular pattern 1/80) and positive IgG and IgM antibodies for *Mycoplasma*, with a second negative determination (false positive). Systematic examination of cerebrospinal fluid showed no abnormalities and oligoclonal bands were negative. The brain MRI images showed two large swollen-looking lesions in the left occipital temporal and posterior superior parietal regions, as well as another, smaller, lesion, adjacent to the right occipital horn (Fig. 1). The brain diffusion sequences showed a high signal in lesion periphery with a low signal in its interior; after the intravenous (i.v.) gadolinium, minimal peripheral enhancement was observed (Fig. 1). A spinal MRI showed no abnormalities.

A diagnosis of acute disseminated encephalitis after vaccination was established, and treatment was started with i.v. methylprednisolone at doses of 1 g/day for 5 days with subsequent gradually-decreasing oral prednisone; a rapid improvement of visual field deficit was observed (resolved in the first week after treatment). A control cerebral MRI, performed 2 months after discharge, showed clear improvement, with no evidence of the appearance of new lesions (Fig. 2).

Gardasil® is a recombinant, adjuvant, non-infectious vaccine, prepared from virus-like particles (VLPs), highly purified from protein L1 of the major capsid of HPV types 6, 11, 16 and 18, which has proved effective in preventing cervical cancer and in vaginal, vulvar and cervical dysplasia. VLPs contain no viral DNA, so they can not infect cells, reproduce or cause disease. Gardasil® use has been approved by the U.S. Food and Drug Administration (June 2006) and the European Medicines Agency (September 2006). The regime recommended is 3 separate intramuscular doses (0, 2 and 6 months)<sup>4</sup>. It was introduced into the childhood immunisation schedule in Spain in January 2008, with progressive phasing-in in the different autonomous regions for girls between 9 and 15 years; women between 16 and 26 years can also be vaccinated on a voluntary basis. No

adverse neurological effects were reported in the studies prior to its marketing. There have been cases of Guillain-Barré<sup>5</sup>, as well as non-specific cases of headache and dizziness. In September 2008, it was reported that 5 Australian patients<sup>6</sup> presented atypical or multifocal demyelinating syndromes of the central nervous system within 21 days after the second or third dose of vaccination with Gardasil®. These cases included presentations such as optic neuritis, multifocal myelitis, or combinations of spinal and cerebral symptoms. All patients evolved favourably spontaneously or after administration of i.v. methylprednisolone. In November 2008, a case of ADEM was communicated<sup>7</sup> for a 15-year-old European patient after receiving the second dose of Gardasil®.

Our patient developed a clinical picture compatible with ADEM (with swollen demyelinating lesions in the brain MRI) after receiving the second dose of HPV immunisation. Swollen images are common in ADEM<sup>2</sup>, although in this case the disproportion between the extent of lesions and the scarceness of accompanying clinical symptoms was striking. The clinical evolution and that observed through imaging techniques confirmed the diagnosis.

As far as we know, our case is the second published (the first in our country) of ADEM after immunisation with Gardasil®. Given that the introduction of HPV immunisation into the vaccination schedule is relatively recent, it is difficult to estimate the frequency with which this disease entity could be observed from the isolated cases reported so far. However, an incidence similar to that which occurs in conjunction with other vaccines (such as measles or chickenpox) in a similarly susceptible population (paediatric age) could be extrapolated, which forces us to take into account this history in patients with a compatible clinical presentation.

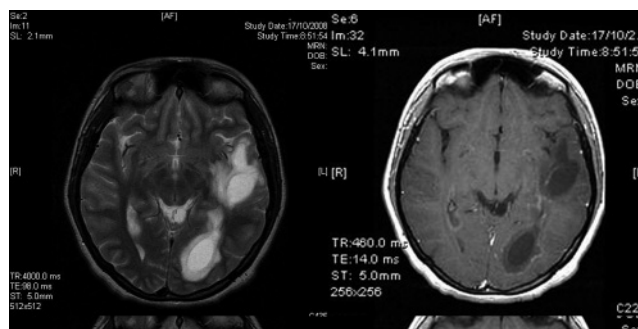
Z. Mendoza Plasencia<sup>a,\*</sup>, M. González López<sup>a</sup>,  
M.L. Fernández Sanfiel<sup>a</sup> and J.R. Muñoz Montes<sup>b</sup>

<sup>a</sup>Servicio de Neurología, Hospital Universitario de Canarias, La Laguna, Santa Cruz de Tenerife, Spain

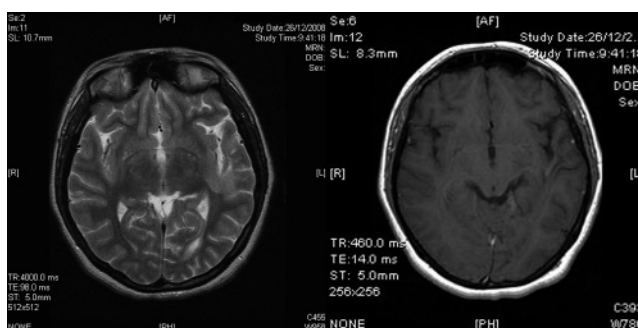
<sup>b</sup>Unidad de Resonancia Magnética, Hospital Universitario de Canarias, La Laguna, Santa Cruz de Tenerife, Spain

\*Author for correspondence.

E-mail: zebensuimp@hotmail.com (Z. Mendoza).



**Figure 1** Brain MRI, T2 axial cuts without contrast and T1 axial cuts with contrast, performed at the time of admission. Three injuries can be observed, two with a swollen appearance in the left parietal and occipitotemporal regions, and another, smaller, adjacent to the right occipital horn. After the administration of i.v. gadolinium, it is possible to observe a fine collection in the periphery.



**Figure 2** Control images (same sequences), performed 9 weeks after symptom onset, which present marked lesion improvement.

## References

1. Menge T, Kieseier BC, Nessler S, et al. Acute disseminated encephalomyelitis: an acute hit against the brain. *Curr Opin Neurol.* 2007;20:247-54.
2. Tenebaum S, Chitnis T, Ness J, Hahn JS. Acute disseminated encephalomyelitis. *Neurology.* 2007;68 Suppl 2:S23-36.
3. Dale RC, De Sousa C, Chong WK, et al. Acute disseminated encephalomyelitis, multiphasic disseminated encephalomyelitis and multiple sclerosis in children. *Brain.* 2000;123:2407-22.
4. Garland SM, Hernandez-Avila M, Wheeler CM, et al. Quadrivalent vaccine against Human Papillomavirus to prevent anogenital diseases. *N Engl J Med.* 2007;356:1928-43.
5. Information from FDA and CDC on Gardasil and its Safety. Vaccine Adverse Event Reporting System (VAERS). July 22, 2008.
6. Sutton I, Lahoria R, Tan IL, Clouston P, Barnett MH. CNS demyelination and quadrivalent HPV vaccination. *Mult Scler.* 2009;15:116-9.
7. Topkian R, Haring HP, Aichner FT. HPV vaccine: a corner stone of female health a possible cause of ADEM? *J Neurol.* 2008;255:1818-20.