

# Diagnostic Clues in Pulsatile Tinnitus (Somatosounds)

Carlos Herraiz<sup>a,b</sup> and José Miguel Aparicio<sup>a,b,c</sup>

<sup>a</sup>Unidad de Acúfenos, Instituto ORL Antolí-Candela, Madrid, Spain

<sup>b</sup>Unidad de Otorrinolaringología, Fundación Hospital Alcorcón, Madrid, Spain

<sup>c</sup>Otorrinolaringología, Hospital Quirón, Madrid, Spain

Pulsatile tinnitus is a sound, mostly of vascular origin, from within the body and stimulating the patient's hearing in the same way as an external sound does, generally at the same pace as the pulse.

Although infrequent, the diagnosis of its cause is crucial because of its potential severity in some cases. This article describes some of the diagnostic clues for arterial causes (arteriosclerosis, aberrant carotid artery, arteriovenous fistula, or malformations, increased vascularization in Paget's disease) and venous causes (benign intracranial hypertension, high jugular bulb). In some cases we have to rule out other systemic diseases such as hypertension, cardiac arrhythmia, or hyperthyroidism. A pathological otoscopy result may be secondary to a tympanic glomus. A guided medical history and an algorithm for complementary tests (magnetic resonance or angio-resonance imaging, computerized tomography, blood test, Doppler ultrasonography) may resolve the diagnostic puzzle of pulsatile tinnitus. We present our experience in 80 cases. The most frequent aetiologies have been arteriosclerosis of the carotid artery (17.5%) and benign intracranial hypertension syndrome (10%).

**Key words:** Tinnitus. Pulsatile tinnitus. Arteriovenous fistula. Benign intracranial hypertension.

## Claves diagnósticas en los somatosonidos o acúfenos pulsátiles

El acúfeno pulsátil es el sonido que se origina en alguna estructura del organismo, generalmente de etiología vascular, y estimula el aparato auditivo igual que lo haría un sonido del exterior pero con una frecuencia similar al pulso arterial.

Es una enfermedad otológica poco frecuente; sin embargo, un diagnóstico etiológico exhaustivo es fundamental por las posibles implicaciones severas que esta entidad puede conllevar. En este artículo se describen las causas arteriales (arteriosclerosis, trayectos carotídeos aberrantes, fístulas o malformaciones arteriovenosas, neovascularización de la enfermedad de Paget) y venosas (síndrome de hipertensión intracraneal benigna, bulbo yugular prominente, etc). En algunos casos, una afección sistémica, como la hipertensión, las arritmias cardíacas o el hipertiroidismo, puede ser la causa de este tipo de acúfenos. La otoscopia patológica puede ser signo de glomus timpánico. Una historia clínica dirigida y un algoritmo en la realización de las pruebas complementarias (resonancia y angiorresonancia magnética, tomografía computarizada, análisis de sangre, ecografía Doppler) suelen ser resolutivas en el puzzle diagnóstico que supone este síntoma clínico. Aportamos nuestra experiencia en pacientes que refirieron un somatosonido pulsátil. La causa más frecuente en nuestra serie fue la arteriosclerosis carotídea (17,5%), seguida del síndrome de hipertensión intracraneal benigna (10%).

**Palabras clave:** Tinnitus. Acúfeno pulsátil. Fístula arteriovenosa. Hipertensión intracraneal benigna.

The authors have not indicated any conflict of interest.

Correspondence: Dr. C. Herraíz Puchol.  
Unidad de Otorrinolaringología. Fundación Hospital Alcorcón.  
Budapest, 1. 28922 Alcorcón. Madrid. España.  
E-mail: cherraizp@seorl.net

Received June 7, 2007.

Accepted for publication June 19, 2007.

## INTRODUCTION

Tinnitus is a symptom frequently seen at otorhinolaryngological clinics. Most of the disorders affecting the inner ear structures can cause subjective tinnitus through different mechanisms.<sup>1</sup>

Changes in the external or internal ciliate cells, afferent fibre imbalances, and cortical reorganization phenomena following peripheral lesions are found in 90%-95% of tinnitus

cases. The other 5%-10% are a type of tinnitus termed objective tinnitus, which does not share these pathophysiological mechanisms, but instead originates within some structure of the body that is generally far away from the auditory path and stimulates the auditory apparatus in the same way as an external sound.<sup>2</sup> We define objective tinnitus (from now on referred to as somatosounds) as any external sound originating inside the body that is perceived by the ear and is therefore capable of stimulating cochlear mechanical activity. The term "objective" is based on the fact that the person performing the examination can hear these sounds.

Instead of the traditional classification of subjective tinnitus (not heard by the person giving the examination) and objective tinnitus (heard by the person conducting the exam), current medical literature imposes a more aetiology-based term: "somatosounds." The objective identification and measurement of certain tinnituses, previously labelled as subjective because the technical ability to perceive them externally was not available, is now being achieved thanks to innovations in technology; therefore, this classification may vary greatly depending on who performs the examination and the means used.

Somatosounds may have pulsatile characteristics, generally indicating a vascular aetiology, or they may give off more continuous tones or frequency rhythms that are faster than the heartbeat. In the latter case, myoclonic, tubaric, or respiratory mechanisms are usually involved. Categorization as pulsatile tinnitus through anamnesis is a basic element that must be considered in order to apply our diagnostic protocol.

## PULSATILE SOMATOSOUNDS

Pulsatile tinnitus, described by the patient as a sound that is in sync with the heartbeat, is an infrequently seen otologic disorder. However, an exhaustive aetiological diagnosis is absolutely necessary due to the possibly severe implications this disorder may lead to.

The pathophysiological mechanism involved in producing the pulsatile sound is linked to blood flow turbulence, either secondary to a stenosis in blood vessel lumen or due to an increase of flow. Pulsatile tinnitus is, with a few exceptions, vascular in origin. Taking this origin into account, we can classify tinnitus as either arterial, venous, or neoplastic.

### How Do We Approach Anamnesis With Regard to Pulsatile Somatosounds?

The first step in anamnesis is to verify that we really are facing a pulsatile somatosound. We check with patients whether the sound they hear has the same rhythm as their heartbeat and whether the rhythm of the somatosound increases when they engage in physical activity. It may be useful to take the patient's pulse and ask the patient to indicate every time "tinnitus" is heard to check whether it is in sync with the heartbeat registered.

Next, we will ask about how it started. Some conditions may come on suddenly, such as with a hypertensive crisis,

or following an arterial change such as an aneurysm, fistula or carotid dissection, or vascular compression due to a cervical mass. At other times, onset is more gradual and insidious, such as with benign intracranial hypertension (BIH) or anaemia. There are different factors at the start of symptoms that may help us in reaching a diagnosis, such as a history of cranioccephalic traumas in arteriovenous fistulae or weight gain in BIH. We will probe deeper into the patients' history, such as whether or not there have been instances of high blood pressure as well as possible treatment changes for this condition; pregnancy will be ruled out, as will a family history of vascular malformations, etc.

The presence of other associated symptoms may also make us lean towards one aetiology or another. Other auditory symptoms such as hypoacusia or aural fullness may be secondary to otitis with effusion, a mass in the middle ear, or an inner ear condition. In its early stages, Ménière's disease may produce pulsatile tinnitus, as can BIH. In both situations, hypoacusia, aural pressure, vertigo, hyperacusia, or cochlear recruitment are usually present. Headaches, especially if they are hemicranial, or changes in vision, point to basilar migraine or BIH.

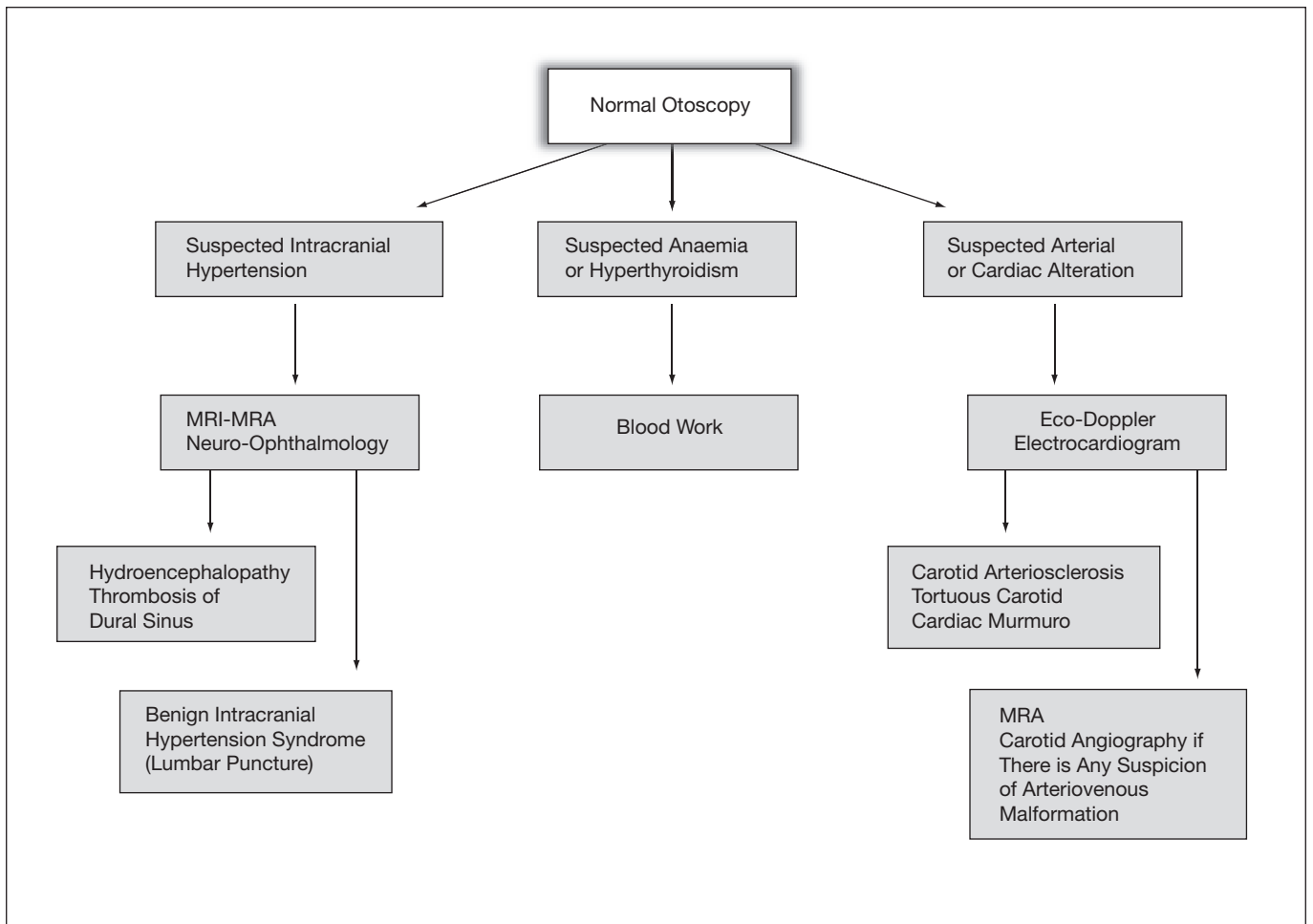
### What Examination Are Needed When Faced With a Pulsatile Somatosound?

Our diagnostic protocol for pulsatile tinnitus is a modified version of the one described by Sismanis<sup>4</sup> (Figures 1 and 2). Otoscopy is essential to orientate the protocol for diagnosis of this symptom.

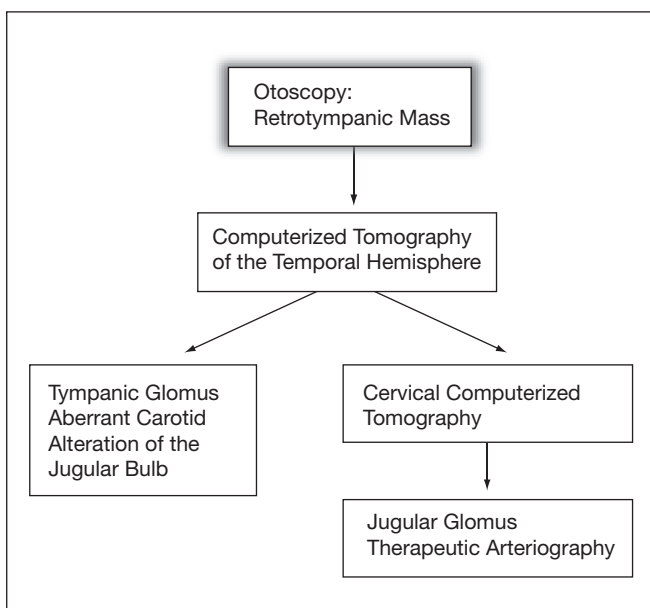
As we shall see, finding changes during this examination is decisive in the case of middle ear disorders. Nasal and pharyngeal assessment by an otorhinolaryngeal endoscopy may help us rule out tubaric or tumoural conditions.

We will do a complete cardiac auscultation, but above all a cervicocranial one. This procedure will allow us to detect arrhythmias, cervical murmurs compatible with carotid diseases (aneurysms, atheromatosis) or murmurs in the temporal, orbital, or retroauricular regions (fistulae or arteriovenous malformations). We should explore those factors capable of changing the intensity or rhythm of the pulsatile somatosound. For this we will use jugular compression manoeuvres at the cervical level, cervical rotation, changes in head position and Valsalva's manoeuvre.

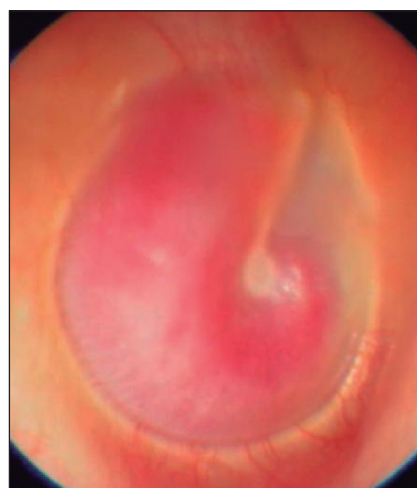
Audiometry may have very different readings, depending on the aetiology. We may see normoacusia, conductive hypoacusia (such as those occurring in serous otitis or sensorineural hypoacusia) or diseases of the inner, or middle ear. In some patients hearing loss is produced because the very same pulsatile "tinnitus" does not allow the low intensity frequencies to be heard, without a true hypoacusia being present. Repeating the audiometry in these cases is interesting to see whether or not in a certain position the patient cannot hear the somatosound. This way we rule out an inner ear condition. Performing other hearing tests such as acoustic otoemissions or evoked potentials will complement the exam according to the condition that we suspect.



**Figure 1.** Diagnostic algorithm for pulsatile tinnitus with normal otoscopy (amended from Sismanis<sup>13</sup>). MRI indicates magnetic resonance imaging; MRA, magnetic resonance angiography.



**Figure 2.** Diagnostic algorithm for pulsatile tinnitus with retrotymppanic mass seen in the otoscopic examination (Sismanis<sup>13</sup>).



**Figure 3.** Otomicroscopy. Tympanic glomus in the right ear.

**What Can We Suspect With a Pathological Otoscopy Result?**

The first test we will do on our patients is an otoscopy. A high percentage of pulsatile somatosounds (PS) show a

normal image but when the cause refers to a change in the middle ear, otoscopy becomes relevant.

We can observe a reddish retrotympanic mass, with a vascular appearance, occupying the hypotympanic region or the entire eardrum, even deforming it. Three diagnoses basically give this image: tympanic chemodectomas (glomus), an aberrant or ectopic carotid artery, and a prominent jugular bulb (Figure 3). For this reason, a computerized tomography (CT) of the petrous bones will be the test of choice. In the case of a jugular chemodectoma we will complement the test with a cervical CT scan. Both pathologies require magnetic resonance angiography in order to plan the surgery.

A chemodectoma or glomus is a tumour that originates in the neuroendocrine tissue surrounding the promontory or large vessels. It is usually more frequent in women, and usually those who are in their forties and fifties. It usually produces a pulsatile tinnitus in 80% of cases. Treatment is surgical; in some patients though, growth control can be achieved with radiotherapy. Angiographic embolization of the vascular mass must be done before surgery (Figure 2).

In other patients we will see a mucous or purulent content in the middle ear, as in chronic and acute otitis media with effusion. In these patients the PS is due to the fact that the mucus in the middle ear transmits the sounds produced by the vessels on the promontory's surface, therefore they are perceived more easily. Generally placing a transtympanic drain clears this up.

### The Otoscopy Is Normal. So Where Do We Focus Our Diagnosis?

When the otoscopic image is normal we are faced with a dilemma in the diagnostic protocol since experience, anamnesis, and paying attention to certain symptoms are key to performing our complementary examinations.

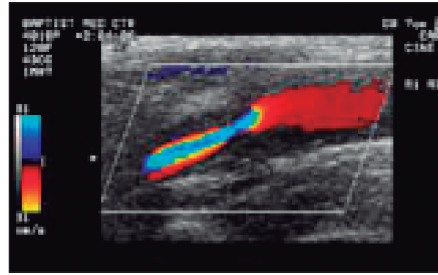
Reviewing the medical history we should be able to determine whether we are facing a systemic, arterial, or venous condition.

#### *Suspicion of a Systemic Pathology*

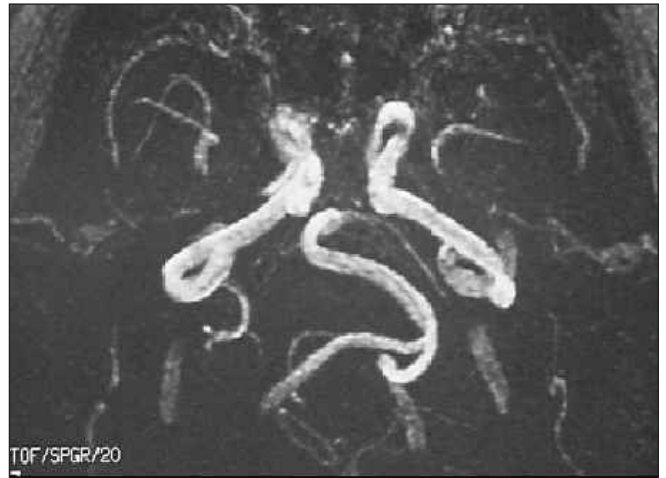
If the patient's medical history is compatible with arteriosclerosis, diabetes, high blood pressure, thyroid, or heart disease, all of this will lead us to request a complete blood workup and cardiologic exam. These are older patients, most being somewhat overweight.

High blood pressure may cause a pulsatile somatosound but occasionally it starts with a continuous tone tinnitus (buzzing), without pulsating characteristics. Occasionally pulsatile tinnitus is persistent but some people mention perceiving it as a paroxysmal crisis (coinciding with high blood pressure spikes). We should investigate the treatments proposed for the high blood pressure since some (such as enalapril or verapamil) may generate a pulsatile somatosound per se.

We will take the patient's blood pressure while the tinnitus is perceived to verify any link. High blood pressure treatment or replacing those that we mentioned earlier usually solves the issue of the patient perceiving the PS.<sup>5</sup>



**Figure 4.** Doppler ultrasound scan of the right common carotid artery in a patient with 60% stenosis of the vascular lumen and clumping of pulsatile tinnitus in the right ear.



**Figure 5.** Magnetic resonance angiography in a patient with an aberrant left basilar artery.

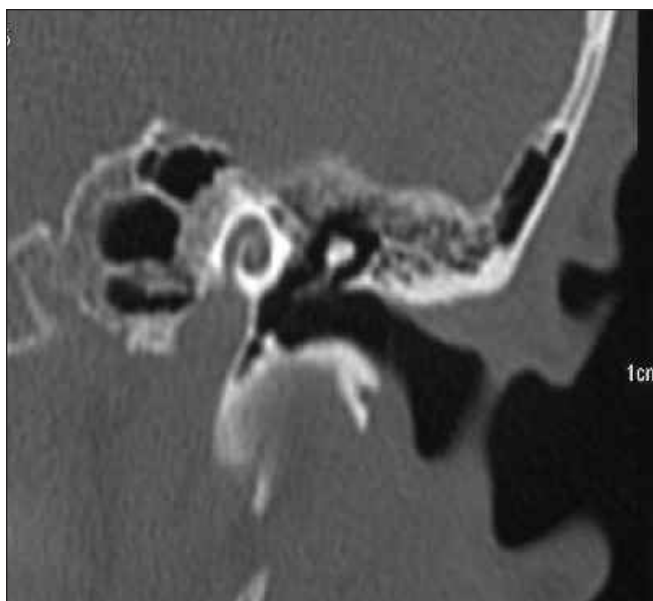
Any situation that increases cardiac activity may generate this type of sound: pregnancy, anaemia, hyperthyroidism, or cardiac changes such as arrhythmias or valvulopathies. Migraine may also cause a PS through 2 mechanisms: the first, during the aura phase, as happens with basilar migraines; the second, during the headache, due to vessel dilatation.

#### *Suspicion of an Arterial Condition*

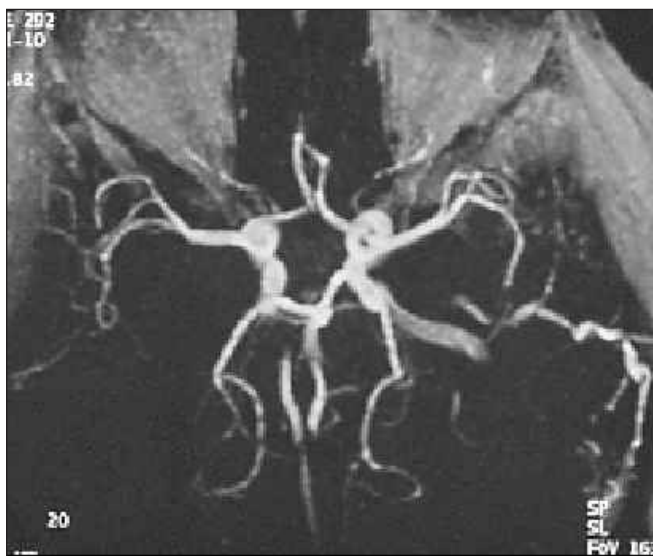
The most frequent diagnosis, when faced with an arterial pulsatile tinnitus, is arteriosclerosis of the carotid artery or the subclavian artery. We should suspect this in patients over 50 having other concurrent diseases such as high blood pressure, diabetes, hyperlipidaemias, or smokers. They may have a history of cerebrovascular accidents. Cervical auscultation may show a murmur that varies depending on neck rotation or extension. A Doppler ultrasound will confirm these stenoses and flow turbulences (Figure 4).

Arteriography<sup>4</sup> may be necessary in some cases. Non-significant stenosis (<60%) may also produce a PS. In this case endarterectomy and angioplasty should not be done and the tinnitus should be handled with therapies helping the person get used to living with it (Figure 4).

Sometimes a tortuous or aberrant carotid artery cannot be seen on the otoscopy and may produce a PS. The basilar artery may produce this symptom when an irregular path is seen (Figure 5). Less frequently we see dehiscence of the carotid canal in contact with the promontory. The carotid



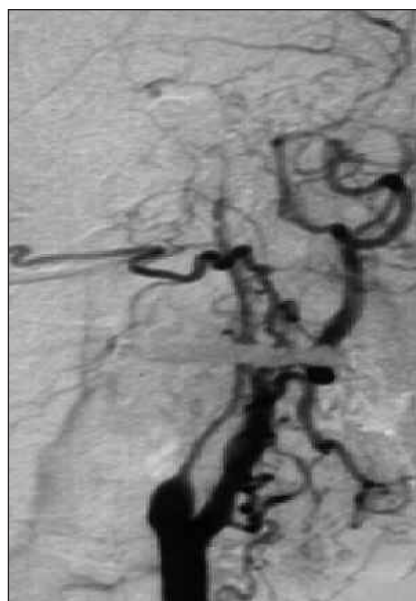**Figure 6.** Computerized tomography. Dehiscence of the left internal carotid artery in contact with the membranous labyrinth.



**Figure 7.** Magnetic resonance angiography. Arteriovenous fistula of the dural sinus in the left temporal region.

artery pulse will be transmitted directly to the membranous labyrinth and then a PS will be heard (Figure 6). A CT scan and magnetic resonance angiography are necessary to confirm these diagnoses.

A suspicion of an arteriovenous malformation or fistula (AVM or AVF) is much more difficult. An AVM or AVF is made up of groups of vessels with numerous links between them. With fistulae, abnormal communications occur between the arterial and the venous regions of the brain, leading to an increase in venous pressure and a reversal of the blood flow. The tributary veins widen, which then dilates them and causes ectasia and oedema. The aetiology is controversial; they may be congenital from aberrant



**Figure 8.** Arteriography. Fibromuscular dysplasia of the carotid. "String of pearls" sign: a succession of dilatations and small aneurysms in the right internal carotid artery.

communications during embryonic development, but most are acquired: spontaneous, post-traumatic, and thrombotic.<sup>5,7</sup> There are some predisposing factors, such as gestation, high blood pressure, arteriosclerosis, or connective tissue diseases. Malformations are more frequently seen in the transverse and sigmoid sinus. Most of the fistulae are communications between the internal carotid artery (mainly dural branches) and the cavernous sinus, although occasionally they may appear between the vertebral artery, the external carotid artery or there may a direct communication from the internal carotid artery (Figure 7).

Clinical manifestations include pulsatile tinnitus, headaches, vision symptoms (pulsatile exophthalmos, ecchymosis, vision loss), and insomnia; there may be more serious symptoms such as intracranial haemorrhaging. An exhaustive auscultation (vascular murmur) should be done in the retroauricular and orbital regions. Sometimes digipressure in these areas decreases the perception of the tinnitus.

Together with auscultation and Doppler ultrasound (as a first step), angio-resonance imaging and angio-CT scan are tests of choice since they have a high rate of detecting mid- and high-flow fistulae.<sup>9</sup> The low-flow fistulae can be diagnosed in many cases thanks to the minimally invasive digital intravenous subtraction angiography (DIVSA) technique. Definitive diagnosis is given after an arteriography, which is a technique that should be used only when embolization is foreseen as the therapeutic approach. The presence of nodes on the arteriography is pathognomonic of arteriovenous malformations.

Carotid aneurysms may be behind a PS. An intra-petrous bone location usually gives a pulsatile tinnitus in most cases, while a cervical location is associated with a palpable pulsatile mass, with vascular murmur auscultation. In carotid fibromuscular dysplasia the aetiology is usually idiopathic and frequently multifocal, with pulsatile tinnitus as the most common symptom.<sup>5</sup> Using arteriography as a diagnostic

test shows a succession of dilatations and small aneurysms. Magnetic resonance arteriography will help us with wider vessels. Embolization and open surgery will be the therapeutic processes to be used (Figure 8).

Masses in the neck (thyroid goitre, cervical cyst, neoplasia) may put external pressure on the carotid artery and cause turbulence or blood flow stenosis, in which case a cervical CT is the standard diagnostic test to be performed.

Neovascularization and the formation of arteriovenous fistulae in the temporal bone cause pulsatile tinnitus in 10% of patients with Paget's disease.<sup>5</sup> In some cases stapedectomy may resolve the issue. Otosclerosis, during the first stages, may also cause a PS. In some cases a persistent stapedia artery can be found that is capable of generating a pulsatile sound, making surgery very difficult (Figure 9).

The appearance of a Ménière-like syndrome associated with fluctuating sensorineural hypoacusia, vertigo, and tinnitus will make us suspect vascular compression of the VIII cranial nerve. The tinnitus is usually a non-pulsatile continuous tone when it is due to an acoustic nerve lesion from vessel compression. When the artery (generally a loop in the anteroinferior cerebellar artery, AICA) is in contact with the bony wall of the internal ear duct, it generally produces pulsatile tinnitus since the beating of the artery is transmitted toward the inner ear by way of the cranial bone. Magnetic resonance angiography may be a valid diagnostic method.<sup>10</sup> However, the presence of asymptomatic AICA loops is similar in proportion to those presenting clinical signs and symptoms. Evoked potentials may show changes in the auditory nerve in cases of vessel compression, while at other times an arachnoid cyst located in the area of the pontocerebellar angle may cause a compression syndrome. Vascular decompression of the VIII pair resulted in an improvement in 77%-79% of the patients in a 207-case series.<sup>11</sup>

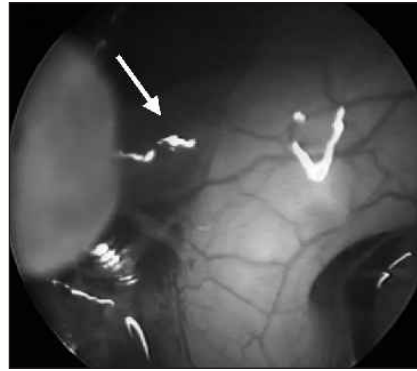For diagnosing most arterial conditions the test of choice is a magnetic resonance angiography of the brain and supra-aortic trunks, with the exceptions mentioned above. For authors such as Dietz,<sup>9</sup> of the 28 patients with tinnitus secondary to vascular disease, all tested positive during the magnetic resonance angiography performed prior to the confirming arteriography.

An arteriography is optional for those cases with a normal magnetic resonance angiography and a high suspicion of arteriovenous malformations.

#### *Suspicion of a Venous Condition*

Suspecting a venous condition will always be more difficult since the symptoms and imaging findings are less conclusive. Anamnesis may also orientate us toward a venous condition and the jugular compression test may be useful in telling the difference from an arterial disease. Generally, in cases in which venous changes cause a PS, pressure on the jugular on the same side as the sound decreases it or eliminates it from being perceived, while with arterial conditions this is not so.

The most frequent venous condition in a PS is BIH. This is defined as an increase of the intracranial pressure above 250 mm H<sub>2</sub>O, with no neurological focal signals (except occasional paresias of the VI pair), and with no lesions



**Figure 9.** Otomicroscopy. Image of a persistent stapedia artery. (Photo provided by courtesy of F Antolí-Candela.)

**Table 1.** Clinical Entities and Conditions Related to Benign Intracranial Hypertension<sup>13</sup>

Confirmed
Epidemiological signs: female, middle-aged, menstrual irregularities, obesity, recent weight gain
Possible
Endocrine signs: adrenal insufficiency, Cushing's syndrome, hypoparathyroidism, hypothyroidism
Drugs: tetracyclines, trimethoprim-sulphamethoxazole, cimetidine, corticosteroids, lithium, levothyroxine
Others: kidney failure, lupus erythematosus

occupying the area or an increase in the ventricle size.<sup>14</sup> This is not frequent and is calculated at 1 per 100 000 people per year, affecting more women, people with obesity or rapid weight gain and people of African ancestry.<sup>12</sup>

Obesity leads to an increase in the intra-abdominal and intrathoracic pressure from an elevation of the diaphragm. This hypertension makes the venous flow from the brain more difficult thus increasing the resistance to absorption of cerebrospinal fluid (CSF) and causing an interstitial cerebral oedema. The most frequent otoneurological symptom is pulsatile tinnitus.<sup>13</sup> Other frequent symptoms are headache, visual manifestations (diplopia from paralysis of the VI pair, papilloedema, vision loss), sensorineural hypoacusia mainly for low tones and fluctuating ones, vertigo, and aural fullness.<sup>14</sup> It has also been linked to trigeminal neuralgias and facial paralysis.

An improvement in the tinnitus after jugular pressure will help us with our diagnosis. Fundoscopy shows papilloedema in most patients, but it is not necessary in order to define this. Diagnosis requires that we rule out other diseases with the same signs and symptoms, such as lesions that occupy the space (central nervous system tumours), which is why a magnetic resonance image is mandatory. In some cases we can see an empty sella turcica or a small ventricular size. The BIH is also linked to other clinical and systemic conditions (Table 1).<sup>13</sup>

Treatment of this requires, as a first step, weight loss, because in many patients this proves to be enough to reverse the symptoms. Diuretics such as acetazolamide or furosemide are used to favour the least amount of CSF being

**Table 2.** Aetiological Diagnosis in Pulsatile Tinnitus

<i>Diagnosis</i>	<i>Sismanis,<sup>4</sup></i> %	<i>Waldvogel,<sup>8</sup></i> %	<i>Dietz,<sup>9</sup></i> %
Benign intracranial hypertension	43	1	–
Arteriosclerosis of the carotid	18	8	1
Paraganglioma	12	6	10
Arteriovenous fistula or malformation	2	27	26
Vascular tortuosity	5	1	4
Dissection and aneurysm of the carotid	1	7	2
Fibromuscular dysplasia	–	6	–
Others	11	12	2
Unknown	8	32	55

produced and to eliminate extremely high blood pressure. Steroids may also be helpful. When a pharmacological improvement is not achieved a peritoneal shunt is put in place. The shunt usually closes up easily due to obstruction, making it inoperative.<sup>14</sup>

Other venous changes have been described that are capable of producing a PS, such as changes in the mastoid epiphyseal veins, a narrowing of the transverse venous sinus or a venous murmur.

### What Are the Most Common Causes of Pulsatile Somatosounds?

The results published in different series show great variability depending on the unit the patient was studied at: neurology/neurosurgery or otorhinolaryngology.

The most extensive series is the one published by Sismanis<sup>14</sup> on 145 patients, where benign intracranial hypertension was the most frequent diagnosis (43%). Waldvogel et al<sup>8</sup> describe

**Table 3.** Most Likely Diagnosis in Our Series (n=80)<sup>a</sup>

<i>Likely Aetiology</i>	<i>Patients, n (%)</i>	<i>Other Concomitant Aetiologies</i>
Carotid stenosis	14 (17.5)	One case associated with anxiety and another with uncontrolled high blood pressure
Benign intracranial hypertension	8 (10)	
Ototuberculosis/otitis media with effusion	6 (7.5)	
Tension headache/stress	4 (5)	
Loop in the anteroinferior cerebellar artery/VIII pair v.c. syn.	4 (5)	One case associated with prior anxiety
Arterial hypertension	4 (5)	
Arteriovenous fistula	3 (3.8)	
Endolymphatic dropsy/MS	3 (3.8)	One case associated with loop in the anteroinferior cerebellar artery
Chronic otitis media	3 (3.8)	
Protruding jugular bulb	3 (3.8)	One case associated with anaemia
Otosclerosis	2 (2.5)	One case associated with loop in the anteroinferior cerebellar artery
Tympanic glomus	2 (2.5)	
Anaemia	2 (2.5)	One case with elongation of the basilar artery
TMJ pathology	2 (2.5)	
Aneurysm in posterior communicating artery	1 (1.3)	
Dehiscent internal carotid	1 (1.3)	
Stenosis of the sub-clavian artery	1 (1.3)	
Basilar dolichoectasia	1 (1.3)	
Pressure trauma	1 (1.3)	Associated with chronic otitis media
Reaction to anti-hypertensive	1 (1.3)	
Meningocele in external auditory canal	1 (1.3)	
Migraine	1 (1.3)	
Contracture of the neck	1 (1.3)	
Pre-menstrual retention	1 (1.3)	
Idiopathic	10 (12.5)	

<sup>a</sup>v.c. syn. indicates vascular compression syndrome; MS, multiple sclerosis; TMJ, temporomandibular joint.

a 27% rate of arteriovenous fistulae in a sample of 84 patients; this condition was also the most frequent one in a series of 49 patients published by Dietz et al<sup>9</sup> (18%).

The number of unknown diagnoses varies greatly among the different authors: from 9% in Sismanis<sup>14</sup> to 55% in Dietz et al.<sup>9</sup> A comparison among the different series can be seen in Table 2.

In our series, 80 patients were sent to the tinnitus unit for a pulsatile somatosound (Table 3). The most frequent aetiology was carotid stenosis secondary to arteriosclerosis (17.5%) followed by BIH syndrome (10%) and tubaric obstruction or otitis media with effusion in 7.5%. This information cannot be extrapolated to the findings of a general ear, nose, and throat examination since the low incidence of glomus in our series (2 cases) would possibly be higher during a general check-up (most patients referred to a tinnitus unit have already been checked out for more evident diseases). It also cannot be compared to a visit to a neurologist, where cerebrovascular diseases (aneurysms, arteriovenous fistulae) are predominant.

## NON-PULSATILE SOMATOSOUNDS: MYOCLONIAS

Myoclonias of the middle ear muscles (tensor tympani and stapedial) and of the palatine muscle present a tinnitus that the patient describes as lasting only a certain amount of time and sounding like a "typewriter." These are frequent in patients with symptoms of masseter muscle contraction or changes in the temporomandibular joint, but a central disorder must be ruled out as a possible aetiology: multiple sclerosis, cerebral artery trunk infarction, or cerebellar change. In order to reach a correct diagnosis, otoscopy may reveal fasciculations of the eardrum. By using fibroendoscopy, we can observe the movements of the peristaphyline muscles. While the mouth is open the tinnitus usually decreases. Auscultation, impedanciometry and blood work to measure calcium, potassium, and magnesium may be useful.

Several pharmacological treatments have been described (benzodiazepine, carbamazepine) as have surgical ones (tenotomy), but the one used most is an injection of botulinum toxin at a dose of between 4 and 10 U, and that is repeated according to the patient's progress.<sup>15</sup> Electrostimulation through TENS (trans-electrical nerve stimulation) systems prove to be an effective method. In our service we have described 14 cases of myoclonia, 8 of which were treated with TENS, with an 88% rate of resolution of the cases. The rest were given mouth guards since the probable cause of the myoclonia is a temporomandibular joint condition.

## REFERENCES

- Herraiz C. Mecanismos fisiopatológicos en la génesis y cronificación del acúfeno. *Acta Otorrinolaringol Esp.* 2005;56:335-42.
- Shulman A. Clinical types of tinnitus. In: Shulman A, editor. *Tinnitus diagnosis / treatment.* San Diego: Singular; 1997. p. 329-41.
- Herraiz C, Hernández Calvín FJ, Machado A, et al. Evaluación diagnóstica del acúfeno pulsátil. XVII Congreso de la SEORL. Las Palmas, October, 1998. P-053.
- Sismanis A. Neurotologic manifestations of intracranial hypertension. In: Reid A, Marchbanks RJ, Ernst A, editors. *Intracranial and inner ear physiology and pathophysiology.* London: Whurr; 1998. p. 61-6.
- Olteanu-Nerbe V, Uhl E, Steiger HJ, Yousry T, Reulen HJ. Dural arteriovenous fistulas including the transverse and sigmoid sinuses: results of treatment in 30 cases. *Acta Neurochir (Wien).* 1997;139:307-18.
- Sismanis A, Smoker WRK. Pulsatile tinnitus: Recent advances in diagnosis. *Laryngoscope.* 1994;104:681-8.
- Montané D, Casado J. Tratamiento de las fístulas carótido-cavernosas. *Rev Neurol.* 1997;25:1963-7.
- Waldvogel D, Mattle HP, Sturzenegger M, Schroth G. Pulsatile tinnitus — a review of 84 patients. *J Neurol.* 1998;245:137-42.
- Dietz RR, Davis WL, Harnsberber HR, Jacobs JM, Blatter DD. MR imaging and MR angiography in the evaluation of pulsatile tinnitus. *Am J Neuroradiol.* 1994;15:879-89.
- van Hemert RL. MRA of cranial tumors and vascular compressive lesions. *Clin Neurosci.* 1997;4:146-52.
- Moller MB, Moller AR, Jannetta PJ, et al. Microvascular decompression of the eighth nerve in patients with disabling positional vertigo: selection criteria and operative results in 207 patients. *Acta Neurochir.* 1993;125:75-82.
- Wall M, George D. Idiopathic intracranial hypertension. *Brain.* 1991;114:155-80.
- Sismanis A. Pulsatile tinnitus. A 15-year experience. *Am J Otol.* 1998;19:472-7.
- Plaza G, Vela L, Herraiz C, et al. Hipertensión intracranial e hipoacusia fluctuante. *Med Clin (Barc).* 2001;116:75.
- Bryce GE, Morrison MD. Botulinum toxin treatment of essential palatal myoclonus tinnitus. *J Otolaryngol* 1998;27:213-6.