

in the secondary evaluation of trauma patients,⁷ even when the trauma was considered non-serious. However, there is sometimes a symptom-free period after the trauma (open or closed). The appearance of delayed neurological symptoms after an apparently trivial trauma should not be underestimated as it may indicate a severe neurological injury, such as the one described in this case due to spinal cord injury, as well as the presence of a dural fistula.⁸ Both pathologies can have dire consequences if they go unnoticed or if treatment is not started immediately after the onset of symptoms.⁹ Urgent neurosurgical consultation should not be delayed in these cases, and transfer of the patient to a referral center should be considered at the time of diagnosis if necessary.

The presence of subacute or delayed neurological symptoms in a patient who has had blunt cervical trauma, although it was not high-energy and does not present data of vertebral fracture, requires urgent differential diagnosis with post-traumatic spinal cord injuries.

REFERENCES

1. Tompkins M, Panuncialman I, Lucas P, Palumbo M. Spinal epidural abscess. *J Emerg Med*. 2010;39:384-90. <http://dx.doi.org/10.1016/j.jemermed.2009.11.001>.
2. Darouiche RO. Spinal epidural abscess. *N Engl J Med*. 2006;355:2012-20. <http://dx.doi.org/10.1056/NEJMra055111>.
3. Ares B, Prieto JM, Dapena MD, García-Allut A, Lerma M. Spinal epidural abscess secondary to pharyngeal trauma due to food. *Rev Neurol*. 2001;32:1049-51.
4. Alerhand S, Wood S, Long B, Koyfman A. The time-sensitive challenge of diagnosing spinal epidural abscess in the emergency department. *Inter Emerg Med*. 2017;12:1179-83. <http://dx.doi.org/10.1007/s11739-017-1718-5>.
5. Mackenzie AR, Laing RB, Smith CC, Kaar GF, Smith FW. Spinal epidural abscess: the importance of early diagnosis and treatment. *J Neurol Neurosurg Psychiatry*. 1998;65:209-12. <http://dx.doi.org/10.1136/jnnp.65.2.209>.
6. Bond A, Manian FA. Spinal epidural abscess: a review with special emphasis on earlier diagnosis. *Biomed Res Int*. 2016;2016:1614328. <http://dx.doi.org/10.1155/2016/1614328>.
7. Evaluación y manejo inicial. American College of Surgeons, editor. *ATLS Soporte Vital Avanzado en Trauma, Manual del Curso para Estudiantes*. 10ª ed. Chicago: American College of Surgeons; 2018; p. 18.
8. Ginestal RC, García-Moreno F, Marques J, Simoes R, Serafim A, Palma T. Delayed onset diplopia associated with a stab wound dural cerebrospinal fluid fistula. *Sinapse*. 2011;11:16-9.
9. Khursheed N, Dar S, Ramzan A, Fomda B, Humam N, Abrar W, et al. Spinal epidural abscess: report on 27 cases. *Surg Neurol Int*. 2017;8:240. http://dx.doi.org/10.4103/sin.sni_105_17.

Ricardo C. Ginestal-López^{a,*}, Patricia Gómez-Iglesias^a,
Marta García-Yepes^a, Miguel Yus-Fuertes^b,
Carla Fernández García^c

^aServicio de Neurología, Hospital Clínico San Carlos, Madrid, Spain

^bSección de Neuroradiología, Hospital Clínico San Carlos, Madrid, Spain

^cServicio de Neurocirugía, Hospital Clínico San Carlos, Madrid, Spain

*Corresponding author.

E-mail address:

ricardoconstantino.ginestal@salud.madrid.org

(R. C. Ginestal-LópezQ1).

2173-5077/

© 2020 AEC. Published by Elsevier España, S.L.U. All rights reserved.

epidural abscess: the importance of early diagnosis and

Altemeier procedure for rectal prolapse after intersphincteric low anterior resection with transanal total mesorectal excision[☆]

Procedimiento de Altemeier para la reparación de prolapso rectal tras resección anterior de recto interesfinteriana con escisión mesorrectal total por vía transanal



Currently, intersphincteric ultralow anterior resection of the rectum with manual coloanal anastomosis is accepted

treatment in selected cases of Rullier II and III neoplasms of the lower rectum.^{1,2}

[☆] Please cite this article as: Maldonado Marcos E, Planellas Giné P, Gil García J, Farrés Coll R, Codina Cazador A. Procedimiento de Altemeier para la reparación de prolapso rectal tras resección anterior de recto interesfinteriana con escisión mesorrectal total por vía transanal. *Cir Esp*. 2021;99:389-391.

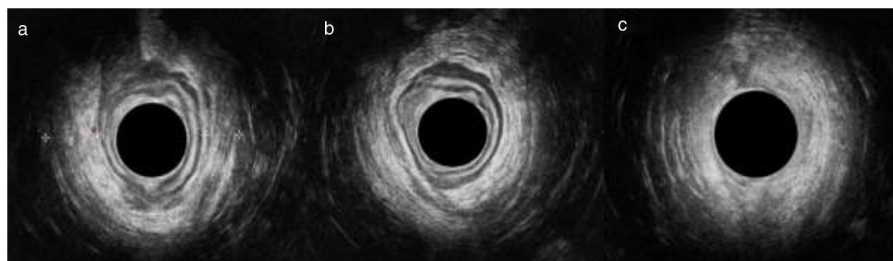


Fig. 1 – Endoanal ultrasound for the study of the prolapse: a) upper anal canal showing asymmetry between the right and left branches of the puborectalis muscle; b) middle anal canal showing thinning of the external anal sphincter in the left quadrants; c) lower anal canal showing no alterations.

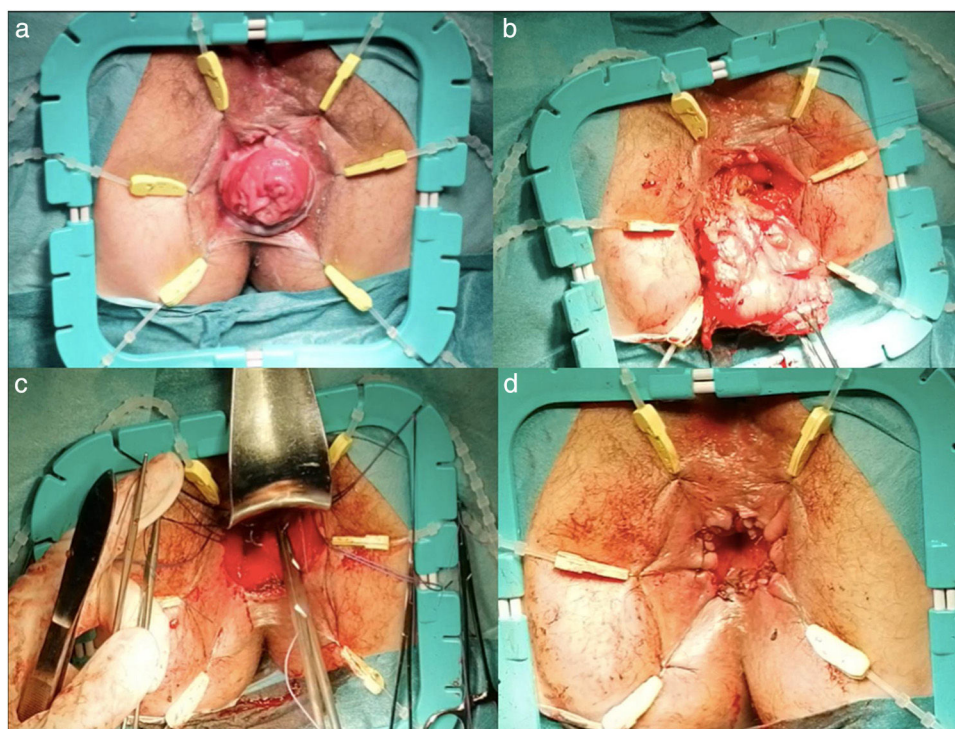


Fig. 2 – Repair of the anal prolapse with the Altemeier procedure: a) prolapse prior to surgery; b) resection of the coloplasty; c) levatorplasty; d) final appearance.

Prolapse of the coloplasty after anterior rectal resection is a rare complication, with an incidence close to 2.2% in the open approach. The incidence is slightly higher when the approach is done laparoscopically or robotically (6.4%).³

Classically, the treatment for coloanal anastomosis prolapse consisted of abdominoperineal resection.

We report the case of a 61-year-old woman with a history of smoking, grade I obesity and tubal ligation, who was diagnosed with low rectal cancer after a fecal occult blood test. Colonoscopy revealed a lesion, whose biopsy was compatible with low-grade adenocarcinoma, 1 cm proximal to the pectineal line. On pelvic MRI, the lesion was observed to be a bilateral posterior and anterolateral tumor of more than 75% of the circumference and 3.5 cm in length. There was invasion of the entire thickness of

the internal anal sphincter, but no signs of invasion of the intersphincteric space, and 5 mesorectal lymphadenopathies were in contact with the mesorectal fascia (Rullier III cT3N2M0). Endoanal ultrasound could not be performed due to pain. In the directed anamnesis, the patient reported good baseline continence (0 points on the Wexner scale) and history of an uneventful vaginal delivery. Upon physical examination, which was limited due to pain, the patient presented good tone, contractility, and preserved reflexes.

The patient received neoadjuvant radiochemotherapy. The restaging MRI showed reduction of the tumor and lymphadenopathy (persisting extramural extension). Distant metastatic involvement was ruled out (Rullier II and cT3N0M0). Surgery was indicated, and we proposed two options: Miles'

abdominoperineal resection or sphincter-preserving surgery with total transanal mesorectal excision (TaTME). The patient opted for the latter.

Complete intersphincteric resection was performed by TaTME surgery, including a manual end-to-end coloanal anastomosis with protective ileostomy. The postoperative patient progress was good, without complications, and she was discharged on the seventh day.

During the subsequent follow-up, the patient presented a good general condition but poor adaptation to the ileostomy. The physical examination was normal. Pathology results reported free margins and optimal mesorectal quality, with final staging ypT1N0.

Four months later, the patient presented with spontaneous rectal prolapse, complete with the Valsalva maneuver. Rectal examination revealed the absence of masses and, together with manometry, severe hypotonia. A colonoscopy study ruled out other lesions, and the endoanal ultrasound showed asymmetry of the puborectalis branches (right 12 mm and left 9 mm), absence of an internal anal sphincter and a complete external anal sphincter, with thinning of the left quadrants (Fig. 1).

Given the coloplasty prolapse together with the severe hypotonia, we performed prolapse surgery without a definitive colostomy, in accordance with the Altemeier technique.⁴ The surgery involved resection of the coloplasty about 7–8 cm below the previous anastomosis and end-to-end coloanal anastomosis with posterior levatorplasty, with no incidents and good retraction of the repair (Fig. 2). The patient was discharged on the second postoperative day, and the ileostomy was closed 3 months later. In subsequent check-ups, the patient has been in good general health, with a score on the LARS scale of 23 points (minor LARS).⁵

Sphincter-preserving surgery for lower rectal cancer is an option whose use is increasing in our setting, with different approaches that include the robotic approach and the TaTME approach.⁶ TaTME surgery should be performed by teams with established training.⁷ Even when the criteria are met, related complications have been reported. Rectal prolapse related with ultra-low resections is a rare complication, associated with poor anorectal function, including incontinence, exudation, and anal pain.⁸

Factors related to the incidence of colon prolapse after intersphincteric resection have been described, such as advanced age, female sex, and neoadjuvant radiotherapy.³

When treating a patient with rectal prolapse, especially after cancer surgery, the study before surgical indication should rule out recurrence and make a dynamic sphincter evaluation.

There are multiple surgical approaches for the treatment of similar cases, whose objectives are to preserve anorectal function and avoid a definitive colostomy. The techniques described by Delorme and Altemeier, rectopexies, or another resection via the abdominal route are examples.^{9,10} In our experience, the Altemeier technique could be one to keep in

mind, although there are no randomized clinical trials or case series with long-term follow-up.

REFERENCES

1. Yamada K, Ogata S, Saiki Y, Fukunaga M, Tsuji Y, Takano M. Long-term results of intersphincteric resection for low rectal cancer. *Dis Colon Rectum*. 2009;52:1065–71.
2. Rullier E, Denost Q, Vendrely V, Rullier A, Laurent C. Low rectal cancer: classification and standardization of surgery. *Dis Colon Rectum*. 2013;56:560–7.
3. Guraieb-Trueba M, Helber AR, Marks JH. Full-thickness neorectal prolapse after transanal transabdominal proctosigmoidectomy for low rectal cancer: a cohort study. *Color Dis*. 2018;20:593–6.
4. Altemeier W, Culbertson W, Alexander J. One-stage perineal repair of rectal prolapse. Twelve years' experience. *Arch Surg*. 1964;89:6–16.
5. Emmertsen KJ, Laurberg S. Low anterior resection syndrome score: development and validation of a symptom-based scoring system for bowel dysfunction after low anterior resection for rectal cancer. *Ann Surg*. 2012;255:922–8.
6. Shirouzu K, Murakami N, Akagi Y. Intersphincteric resection for very low rectal cancer: a review of the updated literature. *Ann Gastroenterol Surg*. 2017;1:24–32.
7. Adamina M, Buchs NC, Penna M, Hompes R, St. Gallen Colorectal Consensus Expert Group on behalf of the SGCCE. St. Gallen consensus on safe implementation of transanal total mesorectal excision. *Surg Endosc*. 2018;32:1091–103.
8. Chau A, Frasson M, Debove C, Maggiori L, Panis Y. Colonic prolapse after intersphincteric resection for very low rectal cancer: a report of 12 cases. *Tech Coloproctol*. 2016;20:701–5.
9. Fazeli MS, Kazemeini AR, Keshvari A, Keramati MR. Delorme's procedure: an effective treatment for a full-thickness rectal prolapse in young patients. *Ann Coloproctol*. 2013;29:60–5.
10. Alwahid M, Knight SR, Wadhawan H, Campbell KL, Ziyaie D, Koch SMP. Perineal rectosigmoidectomy for rectal prolapse—the preferred procedure for the unfit elderly patient? 10 years experience from a UK tertiary centre. *Tech Coloproctol*. 2019;23:1065–72.

Eloy Maldonado Marcos*, Pere Planellas Giné, Júlia Gil Garcia, Ramon Farrés Coll, Antoni Codina Cazador

Cirugía General y Digestiva, Unidad de Cirugía Colorrectal, Servicio de Cirugía General y del Aparato Digestivo, Universidad de Girona, Instituto de Investigación Biomédica de Girona (IdIBGi), Girona, Spain

*Corresponding author.

E-mail address: emaldonadom.girona.ics@gencat.cat (E. Maldonado Marcos).

2173-5077/

© 2020 AEC. Published by Elsevier España, S.L.U. All rights reserved.