



Scientific letters

Autologous Falciform Ligament Graft for Vascular Reconstruction in Pancreatic Cancer Surgery[☆]



Injerto autólogo de ligamento falciforme para la reconstrucción vascular en cirugía oncológica de páncreas

Complete oncological resection (R0) is the main determinant for survival in pancreatic cancer. In order to achieve R0 resection, vascular reconstruction is sometimes required.

We present the case of a 50-year-old male patient diagnosed by computed tomography (CT) (Fig. 1) and abdominal magnetic resonance scans with a tumor in the pancreatic body measuring 53×29 mm, with involvement of the splenoportal confluence and gastric antrum. An endoscopic ultrasound was performed to obtain a sample for histology study, which was compatible with adenocarcinoma of biliopancreatic origin. Positron emission tomography ruled out distant disease.

During surgery, involvement of the lateral side of the portal vein was confirmed. An *en bloc* resection of the body and tail of the pancreas was performed with lateral resection of the portal vein, subtotal gastrectomy and splenectomy. Vascular reconstruction was carried out with a lateral autograft from the falciform ligament using continuous 5/0 prolene suture (Fig. 2).

The definitive pathology result confirmed pancreatic ductal adenocarcinoma with infiltration of the gastric wall and lateral wall of the portal vein, with free resection margins. Two peripancreatic ganglia were affected (2/11), pT4N1.

The patient presented no postoperative complications and was discharged on the sixth day. He was administered thromboembolic prophylaxis with low-molecular-weight heparin for one month. The CT scan performed one month after the surgery demonstrated permeability of the vascular graft.

Porto-mesenteric infiltration is common in tumors of the head and body of the pancreas. In these cases, venous resection is necessary to achieve complete removal of the tumor.¹

Venous reconstruction can be performed in most cases by primary anastomosis. When this is not possible, an autologous graft can be used in cases of small defects or prosthetic material after major resections.²

Numerous autologous graft options have been described, including venous grafts (saphenous, femoral, external iliac, jugular, umbilical, etc.) and peritoneal grafts.¹ The use of the latter was described by Kurbangaleev in 1965. Peritoneal autologous grafts are non-thrombogenic and have some advantages, including being easily obtainable and low in cost.¹

A recently described alternative is the use of the falciform ligament,³ which has an advantage over peritoneal grafts as it is a double membrane structure that lends greater strength¹ and can be used on both sides.

In our patient, the use of the falciform ligament as a graft provided for reconstruction of the venous defect in a simple,

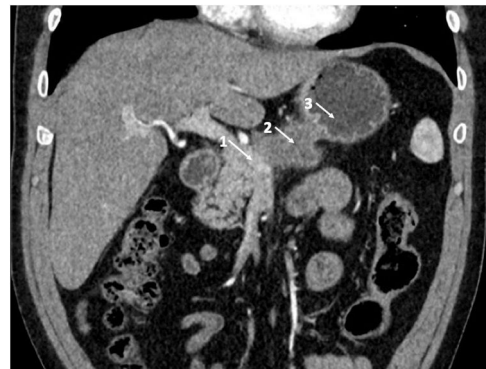

Fig. 1 – Radiological image showing the vascular infiltration: (1) splenoportal confluence; (2) pancreatic tumor; (3) gastric antrum.

[☆] Please cite this article as: Galofré-Recasens M, Herrero Fonollosa E, Camps Lasa J, García-Domingo MI, Cugat Andorrà E. Injerto autólogo de ligamento falciforme para la reconstrucción vascular en cirugía oncológica de páncreas. Cir Esp. 2019;97:54–55.

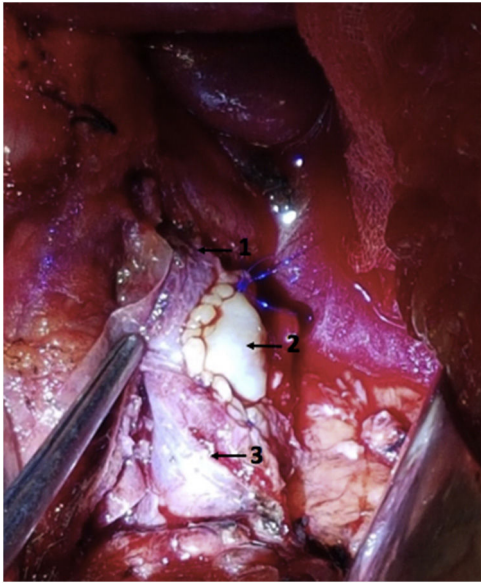


Fig. 2 – Vascular reconstruction with a lateral autologous graft of the falciform ligament: (1) portal vein; (2) lateral plasty of the falciform ligament; (3) superior mesenteric vein.

economical manner, with excellent functional results and free of complications. The falciform ligament can be considered an alternative in venous reconstruction when a graft is necessary during pancreatic surgery.

REFERENCES

1. Zhiying Y, Haidong T, Xiaolei L, Yongliang S, Shuang S, Ligu L, et al. The falciform ligament as a graft for portal-superior mesenteric vein reconstruction in pancreatectomy. *J Surg Res.* 2017;218:226–31.
2. Balzan S, Gava V, Magalhaes M, Schwengber A, Dotto M. The use of autologous peritoneal grafts for vascular reconstruction. *Off J Int Hepato-Pancreato-Biliary Assoc.* 2016;18(S1):e385–601.
3. Dokmak S, Aussilhou B, Sauvanet A, Nagarajan G, Farges O, Belghiti J. Parietal peritoneum as an autologous substitute for venous reconstruction hepatopancreatobiliary surgery. *Ann Surg.* 2015;262:366–71.

María Galofré-Recasens*, Eric Herrero Fonollosa, Judith Camps Lasa, María Isabel García-Domingo, Esteban Cugat Andorrà

Servicio de Cirugía General y Digestiva, Unidad de cirugía HBP, Hospital Universitari Mútua Terrassa, Terrassa, Barcelona, Spain

*Corresponding author.

E-mail address: mariagalofre@uic.es (M. Galofré-Recasens).

2173-5077/

© 2018 AEC. Published by Elsevier España, S.L.U. All rights reserved.

Postherpetic Pseudohernia[☆]

Pseudohernia postherpética



Varicella-zoster virus infection affects 10%–20% of the general population,¹ with an incidence that varies between 3 and 5 per 1000 inhabitants/year.² The neurological sequelae range from chronic pain (postherpetic neuralgia) to meningoencephalitis.³ Within the motor sequelae, postherpetic pseudohernias are due to segmental paresis and appear in less than 5% of cases as a protrusion of the abdominal wall in the absence of structural defects that increases with Valsalva maneuvers.^{4,5}

We present the cases of 2 patients with postherpetic pseudohernia:

An 82-year-old woman was diagnosed with varicella-zoster virus infection after presenting characteristic lesions in the T12-L1 dermatome. She was treated with oral Acyclovir[®] for one week. Three months later, she presented a “bulge” in the region of the right abdominal wall that corresponded with the affected dermatome, which increased in size with the Valsalva maneuver. Upon physical examination, abdominal asym-

metry was observed in the area of the abdominal wall mentioned previously (Fig. 1a), as well as a herpetic eruption in resolution (Fig. 1b). No hernia ring or wall defects were palpated. Computed tomography (CT) confirmed the absence of hernia defects (Fig. 1c) and electromyography revealed limited denervation to the muscles of the right T12-L1 dermatome region.

In the second case, a 67-year-old man presented clinical symptoms that were identical to the first case (Fig. 2b) and was treated with Valaciclovir[®] for one week (Fig. 2c).

The pathogenesis of postherpetic motor complications is controversial. It has been related to the direct propagation of the virus from the dorsal ganglia to the ventral roots or the anterior horns of the spinal cord,^{4,6} thereby generating muscle weakness and the resulting paresis.^{7,8} Abdominal zoster can cause protrusion of the wall, while cervical zoster causes weakness of the arm and the lumbosacral presentation causes bladder and intestinal dysfunction. The term ‘pseudohernia’

[☆] Please cite this article as: Curell A, Ortega N, Protti GP, Balibrea JM, López-Cano M. Pseudohernia postherpética. *Cir Esp.* 2019;97:55–57.