


## CIRUGÍA ESPAÑOLA

[www.elsevier.es/cirugia](http://www.elsevier.es/cirugia)


## Innovation in Surgical Technique

Afferent Loop Stimulation Prior to Ileostomy Closure<sup>☆</sup>J. Abrisqueta, <sup>\*</sup> I. Abellán, M.D. Frutos, J. Luján, P. Parrilla

Servicio de Cirugía General y Aparato Digestivo, Hospital Universitario Virgen de la Arrixaca, El Palmar, Murcia, Spain

## ARTICLE INFO

## Article history:

Received 13 August 2012

Accepted 15 September 2012

Available online 28 May 2013

## Keywords:

Protective ileostomy

Post-surgical paralytic ileus

Afferent loop stimulation

Morbidity

Ileostomy closure

## Palabras clave:

Ileostomía de protección

Íleo paralítico postoperatorio

Estimulación de asa eferente

Morbilidad

Cierre ileostomía

## A B S T R A C T

There is a 17% complications rate after ileostomy closure, with paralytic ileus being the most common. With the aim of reducing this complication, stimulation via the afferent loop was performed daily for the 2 weeks prior to the stoma.

© 2012 AEC. Published by Elsevier España, S.L. All rights reserved.

## Estimulación del asa eferente previa al cierre de ileostomía

## R E S U M E N

El número de complicaciones tras el cierre de ileostomía es del 17%. El íleo paralítico es la complicación más frecuente. Con el objetivo de disminuir esta complicación, las dos semanas previas al cierre del estoma, se realizó una estimulación diaria a través del asa eferente.

© 2012 AEC. Publicado por Elsevier España, S.L. Todos los derechos reservados.

## Introduction

The morbidity and mortality of surgery for rectal cancer have improved since the introduction of colorectal surgery units,<sup>1</sup> although serious complications still occur, and anastomotic leak is the complication associated with a higher rate of mortality.<sup>2</sup> The creation of a protective ileostomy is the only preventative measure that is shown to be effective, and some studies have proven that its absence is a risk factor for the

appearance of anastomotic leak following total mesorectal excision in patients with rectal cancer.<sup>3</sup>

Studies examining cost-effectiveness conclude that the economic benefit of performing a diverting ileostomy begins when leak rates are higher than 16%.<sup>4</sup> However, the reduction in reoperations and the low rate of leaks justify its use, although the indication for protective ileostomy creation is determined by the surgeon's criterion in most cases.<sup>5,6</sup> It should be noted that performing a protective ileostomy has certain drawbacks such as the need for further surgery, as well

<sup>☆</sup> Please cite this article as: Abrisqueta J, et al. Estimulación del asa eferente previa al cierre de ileostomía. Cir Esp. 2013;91:50–2.

<sup>\*</sup> Corresponding author.

E-mail address: [j.abris@hotmail.com](mailto:j.abris@hotmail.com) (J. Abrisqueta).

2173-5077/\$ – see front matter © 2012 AEC. Published by Elsevier España, S.L. All rights reserved.

as a decreased quality of life in the months leading up to ileostomy closure.<sup>7</sup>

The complication rate after ileostomy closure is 17%,<sup>8</sup> with a percentage of reoperations in the different series around 7%.<sup>9</sup> Mortality described in the literature after ileostomy closure ranges between 0.06% and 6.4%.<sup>10</sup>

The most common complication following surgery is paralytic ileus, with an incidence of up to 29%,<sup>11</sup> which creates, in addition to increased patient discomfort, a prolonged hospital stay and high healthcare costs. Postoperative ileus is diagnosed when dietary intolerance motivates a delay in discharge, when the diet must be delayed or is disrupted for over 48 h or when placement of a nasogastric tube is necessary.

The aim of this paper is to present a novel method of reducing the percentage of paralytic ileus after ileostomy closure: the technique consists of stimulating the efferent loop for 2 weeks before the expected date of closure of the stoma. In order to assess its effectiveness and safety, a prospective randomised study has been started.

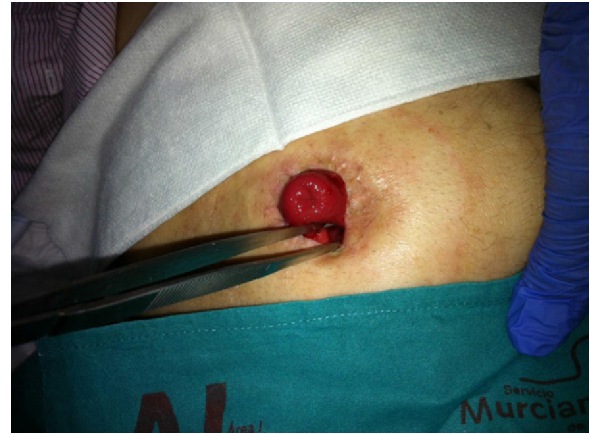### Patient and Technique

A 62-year-old male was diagnosed in March 2011 with a rectal adenocarcinoma of 4 cm, located 3 cm from the anal verge that occupied three quarters of the circumference. Pre-treatment staging was T3N2M0 in the MRI, endoanal ultrasound and abdominal CT scan. He received 28 sessions of radiotherapy with 1.8 Gy per session, associated with oral capecitabine. In August 2011, 6 weeks after receiving the last course of radiotherapy, he underwent surgery and a satisfactory laparoscopic low anterior resection with total mesorectal excision was performed, leaving a protective loop ileostomy in the right iliac fossa without complications. The subsequent pathologic examination revealed a T3N1, Astler-Coller stage C adenocarcinoma. The patient received adjuvant chemotherapy with 4 cycles of oxaliplatin and capecitabine.

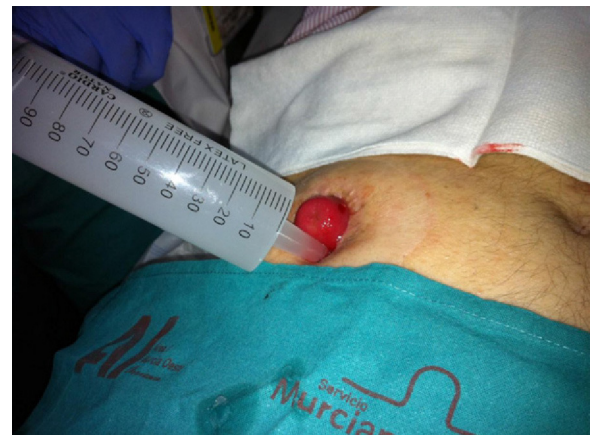Once the oncological disease was under control, he underwent a gastrografin enema through the anus to verify the absence of complications at the anastomosis. Loop ileostomy closure was scheduled, although we previously conducted a daily stimulation of the efferent bowel (ileum and large intestine), with 500cc of physiological saline solution with a nutritional thickener (Resource ThickenUp®, Healthcare Nestlé Nutrition, Montreux, Switzerland) to favour a slow transit, in order to reduce the atrophy and stimulate the intestinal absorptive function of the ileum and colon (Figs. 1 and 2).

After applying stimulation for 2 weeks, ileostomy closure was performed 23 weeks after its construction, using a circular incision around the ileostomy, with resection of the stoma and hand-sewn end-to-end anastomosis. No intra-abdominal drain was used and the incision was closed after irrigating the subcutaneous tissue.

The patient had an uneventful recovery and began intestinal peristalsis 12 h after surgery, with tolerance to oral liquids in the first 24 h, and was discharged without any complications on the second postoperative day. He has



**Fig. 1 – The open efferent loop orifice can be observed.**



**Fig. 2 – Introduction of the thickened solution via syringe.**

continued follow-up visits to date, without complications or disease recurrence.

### Discussion

In the current literature, there are very limited studies that attempt to perform a distal bowel stimulation through the stoma prior to ileostomy closure. Miedema et al.<sup>12</sup> performed ileum stimulation through the anus in patients with ileoanal anastomosis, and did not observe any improvement in terms of absorption or with regard to the motor function of the ileum. The study by Williams et al.<sup>11</sup> demonstrates histological changes that occur after performing an ileostomy, such as villous atrophy and atrophy of the muscle layer of the ileum, and encourages consideration of various methods to prevent or reverse these changes.

The main function of the colon is the absorption of water and electrolytes, and we have not found previous studies, assessing of the changes occurring in the colon after the construction of an ileostomy.

Because of the high number of complications, particularly paralytic ileus, that occur after the closure of an ileostomy, the long postoperative stay and the influence that the excluded

pathophysiological changes could have on them, we believe that this stimulation can activate cellular mechanisms of absorption and motility, by the contact of content on the cell surfaces, so that once the ileostomy is closed, the bowel can returned to normal more quickly.

Moreover, this stimulation can rule out the existence of a distal obstruction that could condition a mechanical ileus after stoma closure.

Using stimulation, the intention is also to carry out a sphincter control education before surgery. It has been shown that after ileostomy creation, atrophy in the external anal sphincter occurs which is related to the elapsed time until the stoma is closed and which conditions a certain degree of faecal incontinence after reconstruction. Added to this is the degree of incontinence that occurs due to the "anterior resection syndrome" and autonomic nerve injury that sometimes occurs during surgery<sup>13</sup> so, especially in these patients, a proper sphincter education prior to stoma closure is particularly important.

Our goal is to reduce postoperative ileus in these patients, thereby achieving a shorter hospital stay and increased patient comfort. With stimulation of the efferent limb we also intend to facilitate the surgical technique, avoiding distal stenosis that can greater difficulty in performing the anastomosis. We believe that the idea of "stimulating before closing" will have clear benefits for our patients.

## Conflict of Interest

The authors have no conflict of interest to declare.

## REFERENCES

1. Smedh K, Olsson L, Johansson H, Aberg C, Andersson M. Reduction of postoperative morbidity and mortality in patients with rectal cancer following the introduction of a colorectal unit. *Br J Surg*. 2001;88:273-7.
2. Courtier R, Pares D, Silva CA, Gil MJ, Pascual M, Alonso S, et al. Resultados clínicos del cierre de ileostomías en asa en pacientes intervenidos de cáncer de recto. Efecto de la quimioterapia en el tiempo de espera. *Cir Esp*. 2010;88:308-13.
3. Peeters KC, Tollenaar RA, Marijnen CA, Klein Kranenbarg E, Steup WH, Wiggers T, et al., Dutch Colorectal Cancer Group. Risk factors for anastomotic failure after total mesorectal excision of rectal cancer. *Br J Surg*. 2005;92:211-6.
4. Koperna TH. Cost-effectiveness of defunctioning stomas in low anterior resections for rectal cancer. A call for benchmarking. *Arch Surg*. 2003;138:1334-8.
5. Allal AS, Bieri S, Pelloni A, Spataro V, Anchisi S, Ambrosetti P, et al. Sphincter-sparing surgery after preoperative radiotherapy for low rectal cancers: feasibility, oncologic results and quality of life outcomes. *Br J Cancer*. 2000;82:1131-7.
6. Rondelli F, Reboldi P, Rulli A, Barberini F, Guerrisi A, Izzo L, et al. Loop ileostomy versus loop colostomy for fecal diversion after colorectal or coloanal anastomosis: a meta-analysis. *Int J Colorectal Dis*. 2009;24:479-88.
7. Thalheimer A, Bueter M, Kortuem M, Thiede A, Meyer D. Morbidity of temporary loop ileostomy in patients with colorectal cancer. *Dis Colon Rectum*. 2006;49:1011-7.
8. Akiyoshi T, Fujimoto Y, Konishi T, Kuroyanagi H, Ueno M, Oya M, et al. Complications of loop ileostomy closure in patients with rectal tumor. *World J Surg*. 2010;34:1937-42.
9. Filkier-Zelkowitz B, Codina-Cazador A, Farrés-Coll R, Olivet-Pujol F, Martín-Grillo A, Pujadas-de Palol M. Morbilidad y mortalidad en relación con el cierre de ileostomías derivativas en la cirugía del cáncer de recto. *Cir Esp*. 2008;84:16-9.
10. Wong KT, Remzi FH, Gorgun E, Arrigain S, Church JM, Preen M, et al. Loop ileostomy closure after restorative proctocolectomy: outcome in 1,504 patients. *Dis Colon Rectum*. 2005;48:243-50.
11. Williams L, Armstrong M, Finan P, Sagar P, Dermot B. The effect of faecal diversion on human ileum. *Gut*. 2007;56:796-801.
12. Miedema BW, Kohler L, Smit CD, Phillips SF, Kelly KA. Preoperative perfusion of bypassed ileum does not improve postoperative function. *Dig Dis Sci*. 1998;43:429-35.
13. Kim KH, Yu CS, Yoon YS, Yoon SN, Lim SB, Kim JC. Effectiveness of biofeedback therapy in the treatment of anterior resection syndrome after rectal cancer surgery. *Dis Colon Rectum*. 2011;54:1007-13.